


Development Of Occlusion

LECTURE BY,
DR. SHANTANU CHOUDHARI

- 
- ▶ Development of Occlusion divided into following stages
 - ▶ • Pre-eruptive jaw relationship
 - ▶ • The deciduous dentition period
 - ▶ • The mixed (transitional) dentition period
 - ▶ • The permanent dentition period.

PRE-ERUPTIVE PERIOD

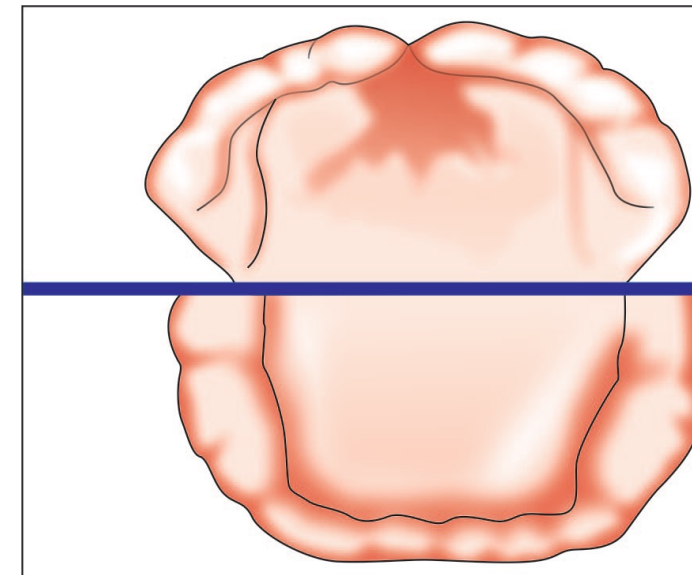
This is the period soon after birth. During this, the neonate has no teeth but the relation of the gum pads is of equal importance.

The alveolar process at the time of birth is called the Gum Pads.

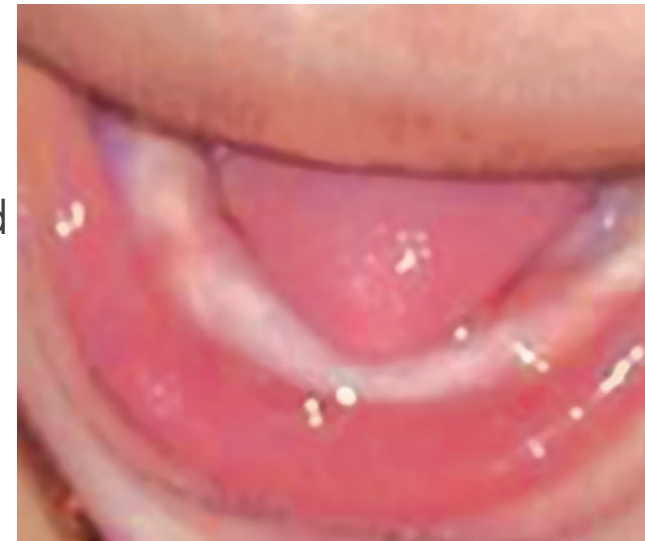Pink, Firm and covered with a layer of dense periosteum

Upper Arch- Horseshoe shape

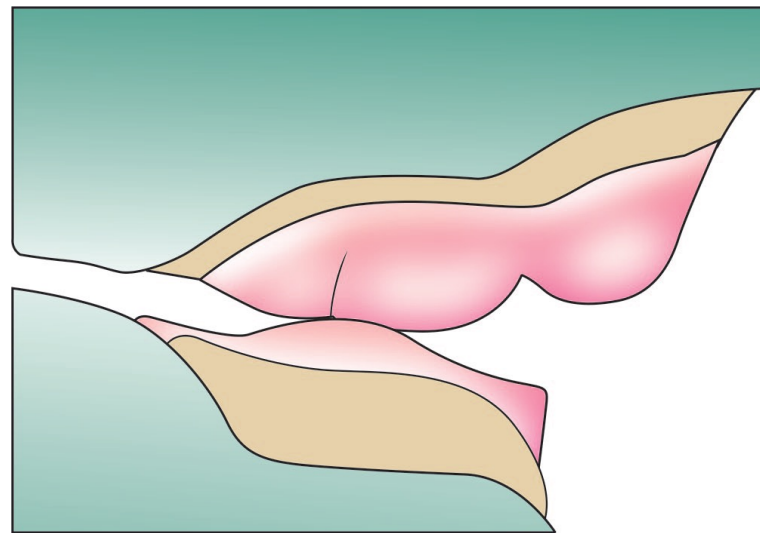
Lower Arch- U shape



- ▶ Divided into 2 parts
 - ▶ 1) **labiobuccal** 2) **Lingual**
 - ▶ **Dental Groove-** Labiobuccal and Lingual divided this groove
 - ▶ Gum Pad has 10 segments and each segment has a developing tooth sac
 - ▶ **Transverse Groove-** Each segment divided by this groove
 - ▶ **Lateral sulcus-** present between canine and 1st molar region
 - ▶ Gingival groove- touches dental groove in canine region and
- Divide gum pad and palate as well as floor of mouth.



- ▶ The maxillary gum pad is wider and longer than the mandibular thus when they are approximated, there is a complete overjet all around.
- ▶ The only contact that occurs is around the molar region while space exists in anterior region. This is called **infantile open bite**, which is considered normal and helpful during suckling



Deciduous Dentition

- ▶ *Both the dental arches are half round in shape or ovoid*
- ▶ *Almost no curve of Spee is present*
- ▶ *Shallow cuspal interdigitation*
- ▶ *Slight overjet*
- ▶ *Deep bite*
- ▶ *Vertical inclination of the incisors*
- ▶ *Spaced dentition*
- ▶ *Different maxillo-mandibular relations like flush, mesial and*
- ▶ *distal terminal planes*



▶ Spacing

- ▶ **Delabarre** in 1918 was the first to describe interdental spacing in primary dentition.
- ▶ **Baume** in 1950 divided the primary dentition into two parts, i.e. spaced and nonspaced. He also concluded that primary spacing occurs around 70 percent in maxilla and 63 percent in mandible.
- ▶ **Foster** and **Hamilton** (1969) reported that only 1 percent of British children had no space.
- ▶ **White** and **Gardiner** (1976) reported that failure of incisor spacing occurs in 20 percent of cases before 5 years of age and usually indicated crowding in the permanent dentition.
- ▶ **Joshi** and **Makhija** (1984) found out that more amount of teeth spacing in males than in females.

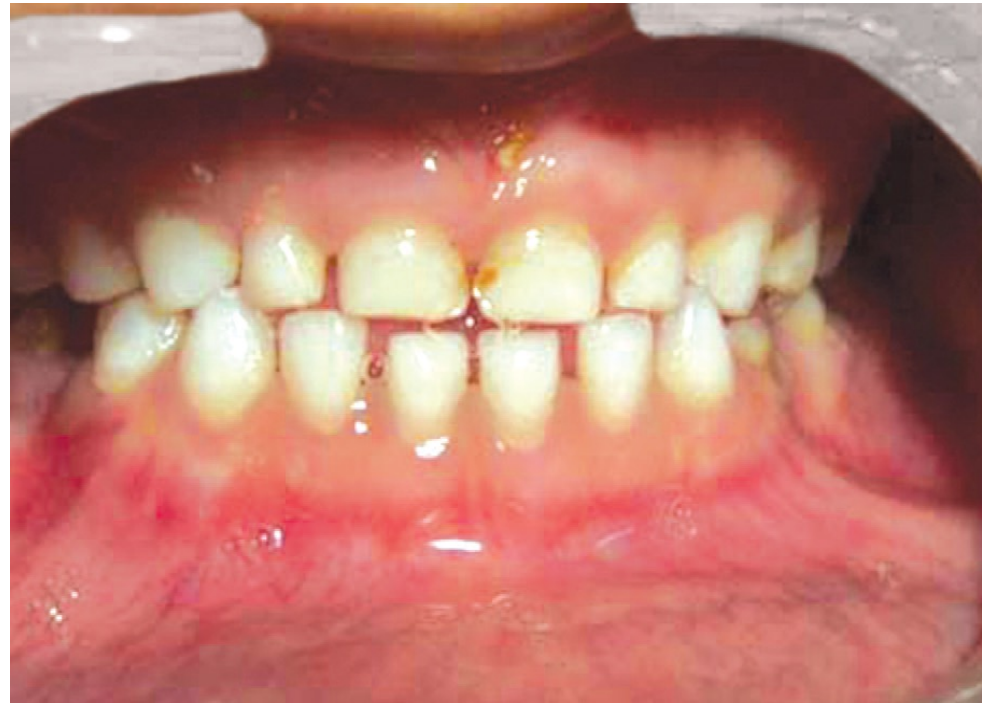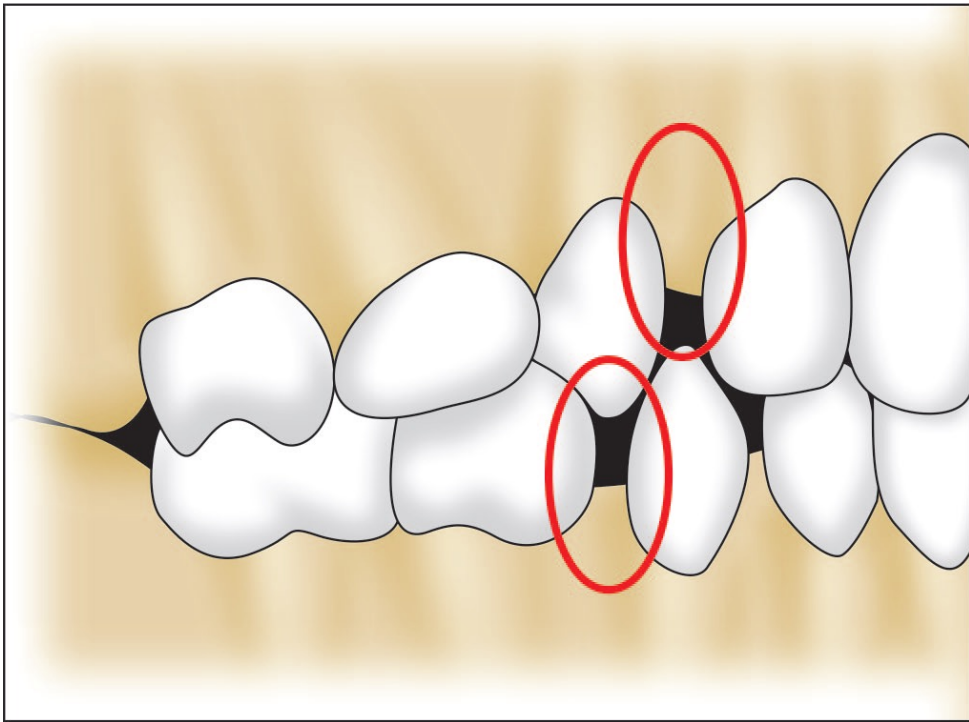

Spaced dentition

▶ Primate Space:

- ▶ Maxillary Arch: lateral incisor and canine
- ▶ Mandibular Arch: Canine and 1st Molar
- ▶ **Synonym: Simian Space, Anthropoid Space,**

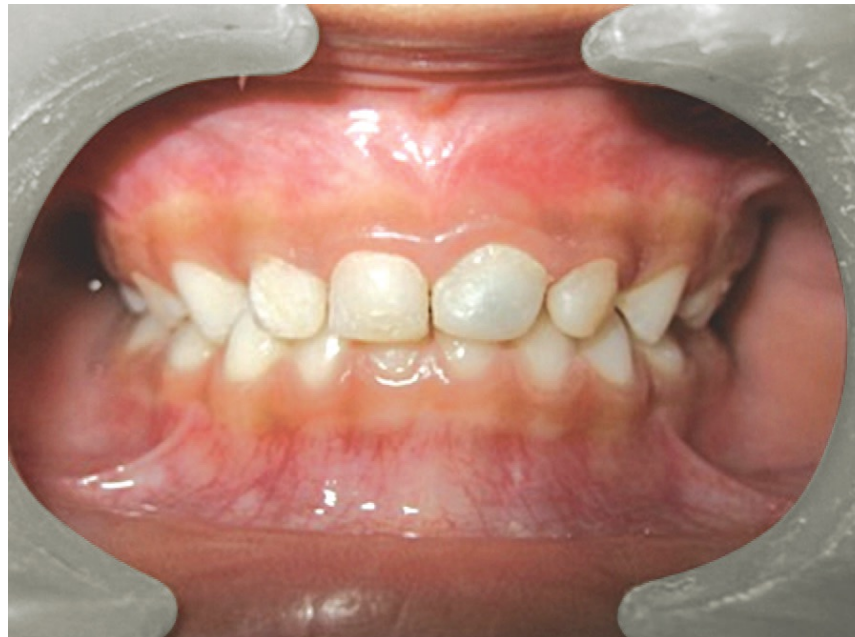▶ Physiologic Space:

- ▶ *Present in between all the primary teeth and play an important role in normal development of the permanent dentition.*
- ▶ The total space present may vary from **0 to 8 mm with the average 4 mm in the maxillary arch** and **1 to 7 mm with the average of 3 mm in the mandibular arch.**



Non- Spaced Dentition

- ▶ This dentition is highlighted by lack of space between primary teeth either due to small jaw or larger teeth. This type of dentition usually indicates to crowding in developing permanent dentition.

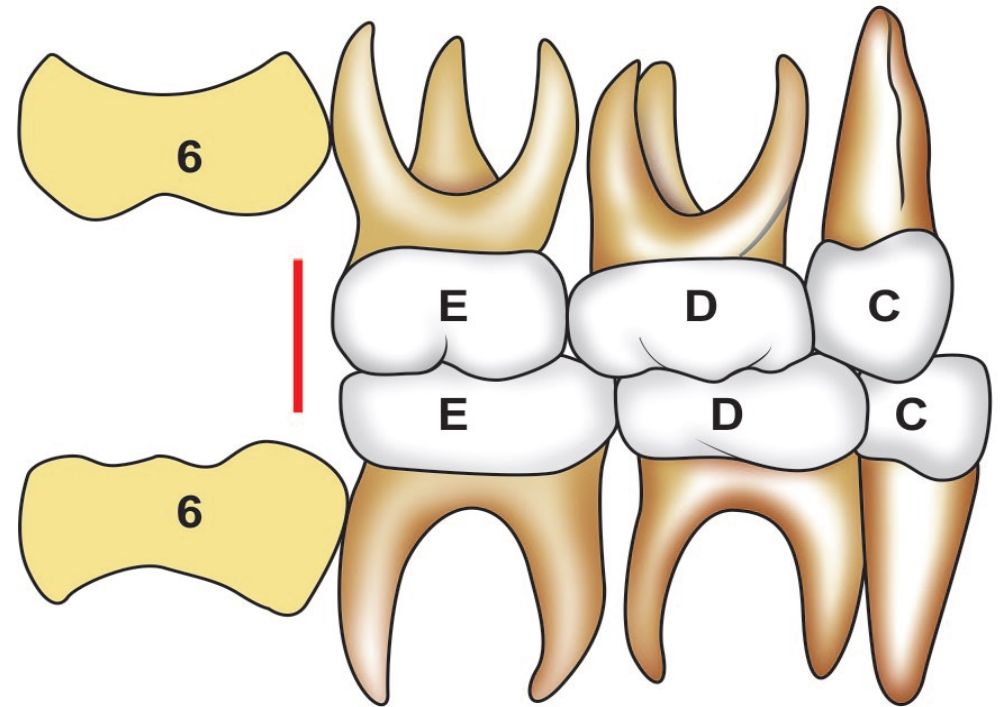


Terminal Plane In Deciduous Dentition:

- ▶ The mesiodistal relation between the distal surfaces of maxillary and mandibular 2nd deciduous molars is called as terminal plane.
- ▶ Three types:
 - ▶ 1. Flush terminal plane
 - ▶ 2. Mesial Step terminal plane
 - ▶ 3. Distal Step terminal plane

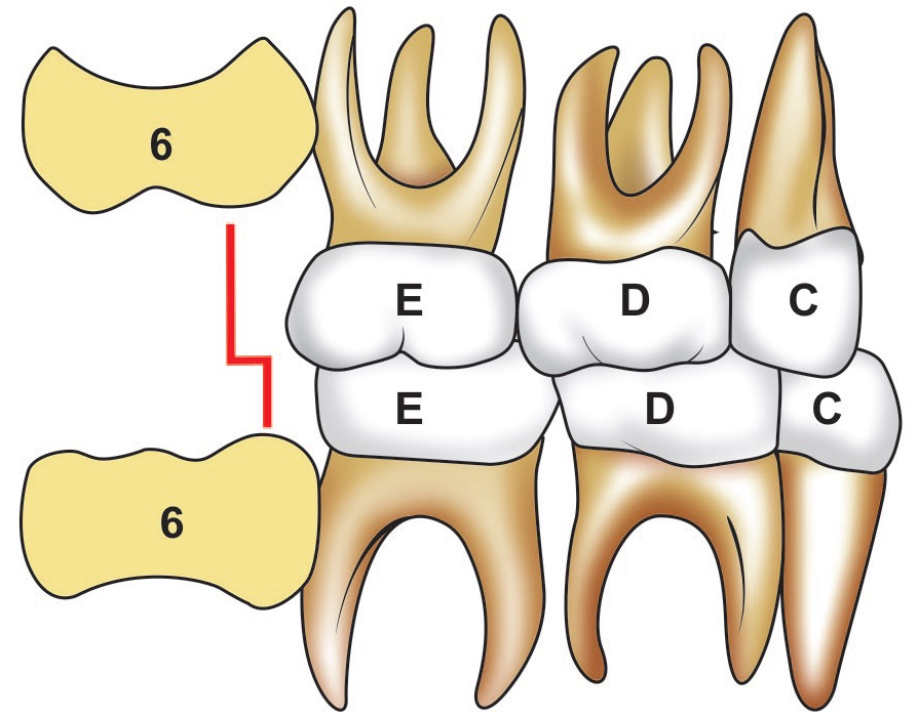
Flush terminal plane

- ▶ The distal surfaces of the deciduous 2nd maxillary and mandibular molars are in a straight plane (flush) and therefore situated on the same vertical plane.
- ▶ It is usually most favorable relationship to guide the permanent molars into class I.
- ▶ It is seen in 74 percent.



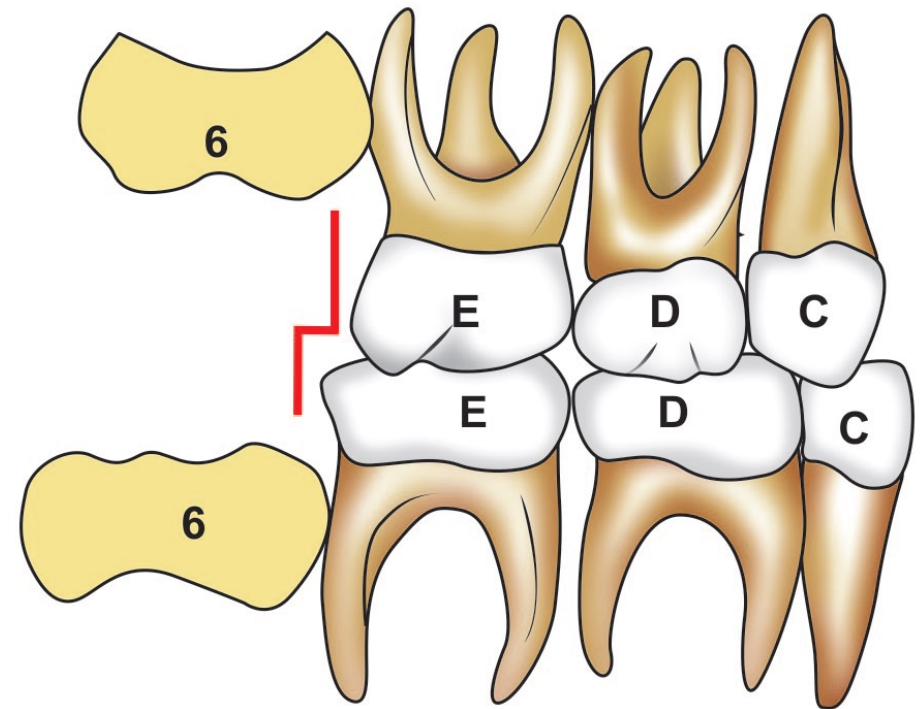
Mesial Step Terminal plane

- ▶ The distal surface of the deciduous 2nd mandibular molar is more mesial to that of the deciduous 2nd maxillary molar.
- ▶ Guides the permanent molars into a class I relationship.
- ▶ Seen in 14 percent



Distal Step terminal Plane:

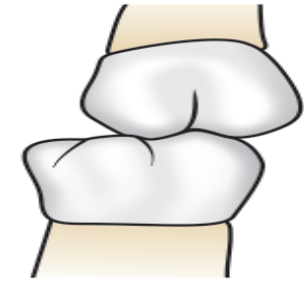
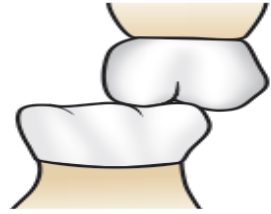
- ▶ The distal surface of the deciduous 2nd mandibular molar is more distal to that of the deciduous 2nd maxillary molar.
- ▶ This relationship is unfavorable as it guides the permanent molars into distal occlusion.
- ▶ Seen in 10 percent



Primary

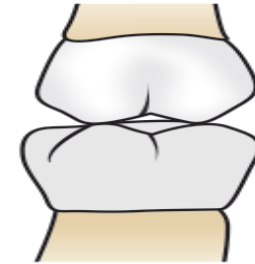
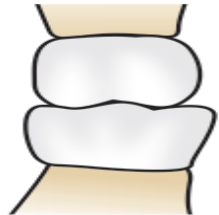
Permanent

Distal step



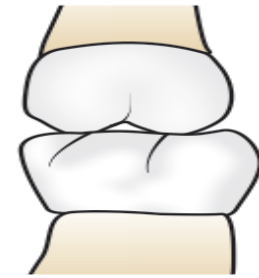

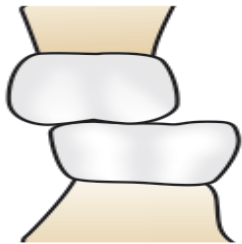
Class

Flush terminal plane

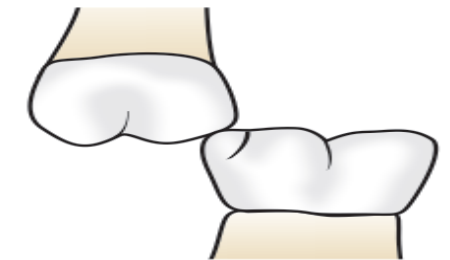


Endo




Mesial step



Class




Class

-  Minimal growth differential
-  Forward growth of mandible
-  Shift of teeth

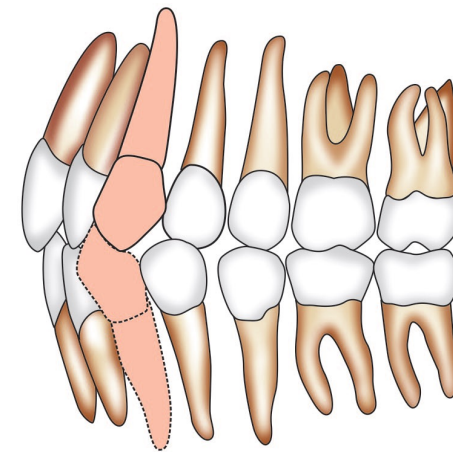
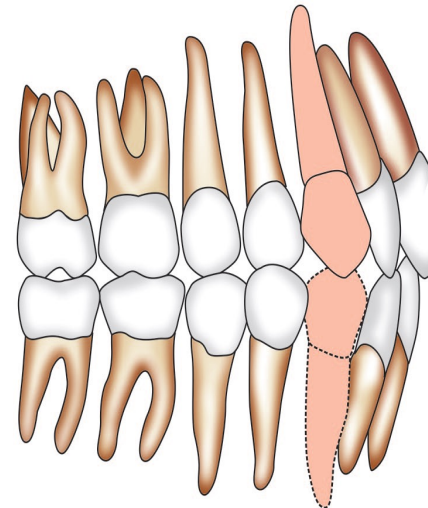
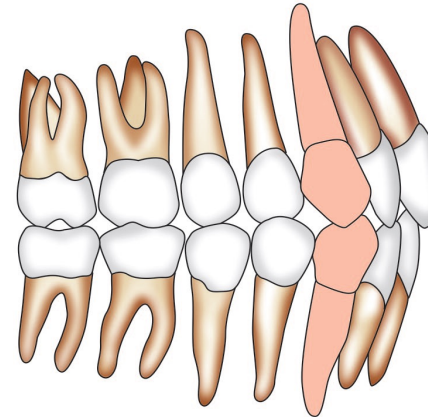
Anterior Teeth relation

- ▶ **Overbite:** It is the distance, which the incisal edge of the maxillary incisors overlaps vertically past the incisal edge of the mandibular incisors.
- ▶ The primary incisors erupt in a deep overbite which is corrected by eruption of posterior teeth around five years of age.
- ▶ The average overbite in the primary dentition is 2 mm.

- 
- ▶ **Edge-to-edge bite:** When the incisal edges of the two incisors are in the same plane. This is also called as a **zero overbite**.
 - ▶ This is most common due to attrition, lengthening of ramus and downward-forward growth of mandible.
 - ▶ **Overjet:** It is the horizontal distance between the lingual aspect of the maxillary incisors and the labial aspect of the mandibular incisors when the teeth are in centric occlusion. The average in primary dentition is 1 to 2 mm.

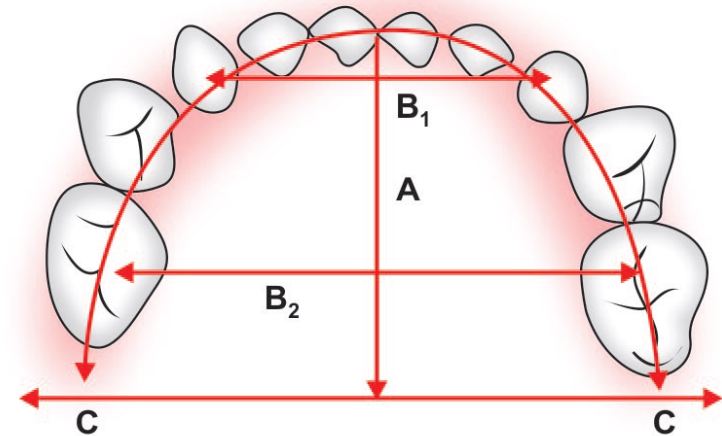
Canine Relationship

- ▶ **Class I:** The mandibular canine interdigitates in embrasure between the maxillary lateral incisor and canine.
- ▶ **Class II:** The mandibular canine interdigitates distal to embrasure between the maxillary lateral incisor and canine.
- ▶ **Class III:** The mandibular canine interdigitates in any other relation.



Arch Dimensions:

- ▶ **Arch size:** Size of the primary dental arch is the arch width between primary canine and 2nd molars.
- ▶ **Arch length:** Measured from the most labial surface of primary central incisor to canine and to 2nd primary molars.
- ▶ **Arch circumference:** It is determined by measuring the length of curved line passing over the incisal edges and buccal cusps of teeth from the distal surfaces of primary 2nd molar around the arch to the distal surface of 2nd primary molar on the other side.
- ▶ **Arch width:** Bicanine or bimolar width is called the arch width.



A – Arch length
B₁ – Bicanine diameter
B₂ – Bimolar diameter
C – Arch perimeter

Mixed Dentition Period

- ▶ The period during which both the primary and permanent teeth are present in the mouth together is known as mixed dentition.
- ▶ **Successional teeth:** permanent teeth erupting in place of previous deciduous teeth.
- ▶ **Accessional teeth:** permanent teeth present posterior to deciduous teeth.
- ▶ Begins at 6 years of age and Last till 12 years.



▶ ***First transitional period:***

▶ – *Emergence of the first permanent molars*

▶ – *Incisors transition*

▶ ***Inter transitional period***

▶ • ***Second transitional period:***

▶ *Emergence of cuspids, bicuspid and the 2nd permanent molars.*

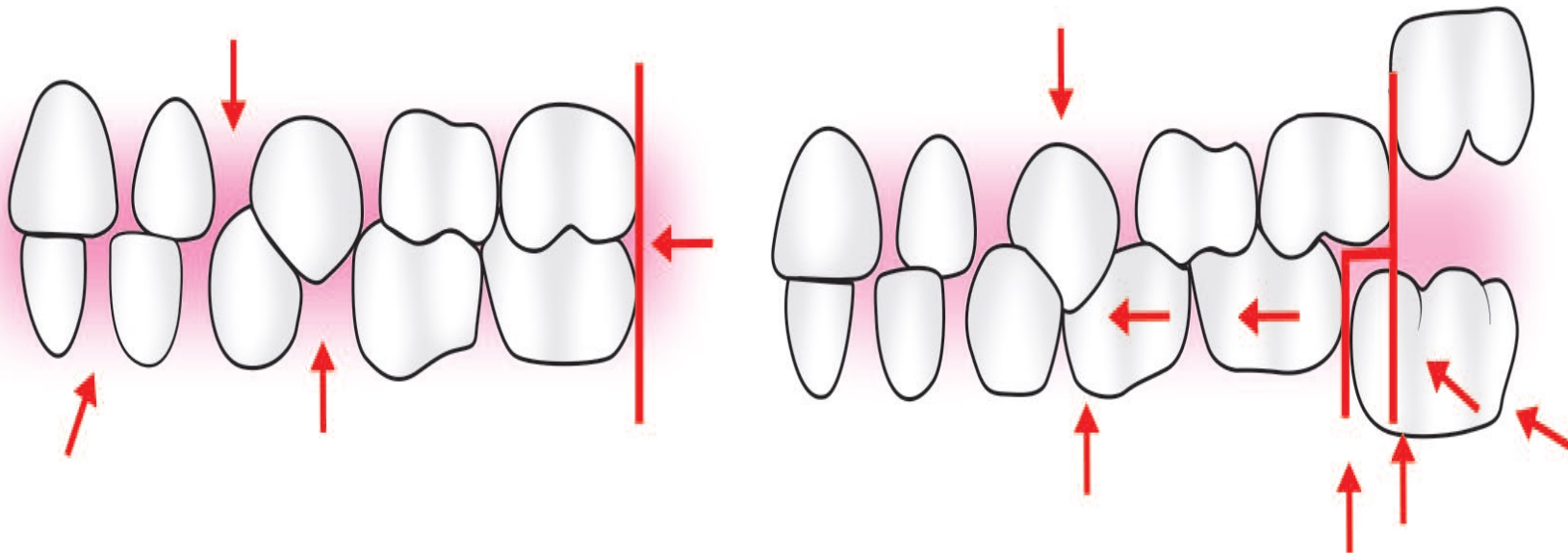
▶ *Establishment of occlusion.*

First transitional period

- ▶ This is characterized by emergence of 1st permanent molars and exchange of deciduous incisors with permanent incisors.
- ▶ ***Emergence of 1st permanent molars:***
- ▶ Erupts at 6 years of age
- ▶ Antero-posterior relation depends mainly on previous occupied position in jaws, maxillo-mandibular relation and cone and funnel mechanism.
- ▶ Position is dependent of deciduous 2nd molar.

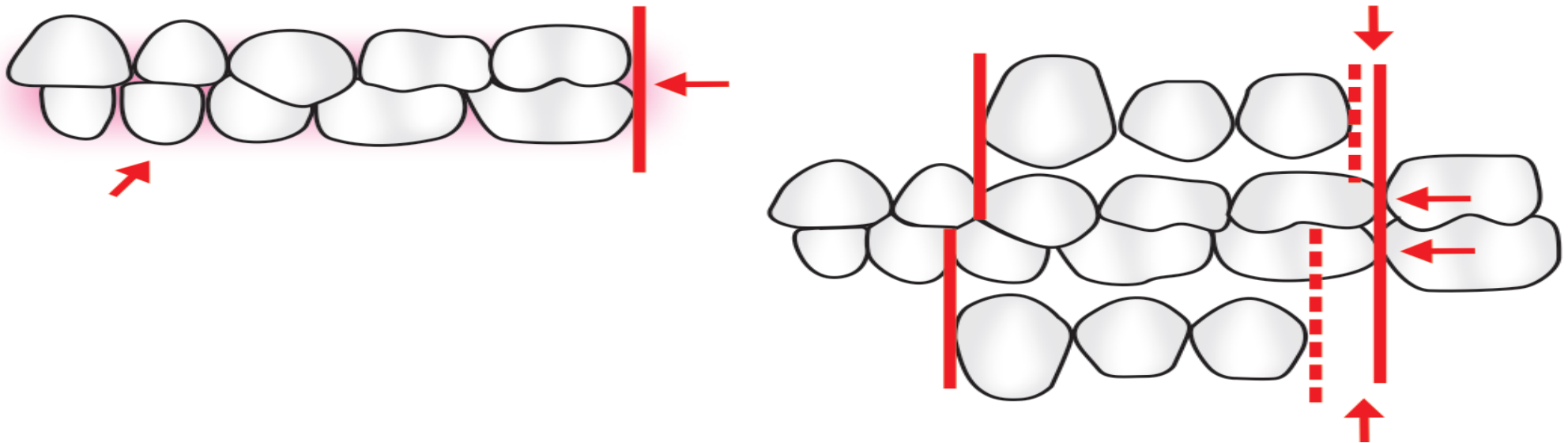
► **Early Mesial Shift:**

- The eruptive forces of 1st permanent molars are strong enough to push the deciduous molars forward in the arch thereby utilizing the primate spaces and thus establishing class I relationship.



► **Late Mesial Shift:**

- Because of lack of primate space or in non-spaced dentition primary tooth utilize lee way space after exfoliation of primary molars and establish the occlusion. This is known as **Late Mesial Shift:**



Exchange Of Incisors

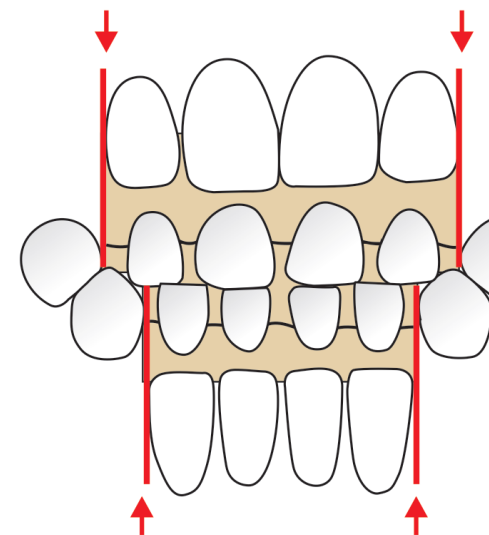
The deciduous incisors are replaced by permanent incisors during this phase.

This period of transition is from 6½ to 8½ years.

Incisor Liability: Permanent Incisors are larger as compared to that of primary incisors. This difference of space available and space required is known as incisor liability.

Maxillary Arch: 7mm

Mandibular arch: 5mm





▶ Some of the factors that help in alignment of incisors by gaining space are:

▶ *Utilization of interdental spacing of primary incisors*

▶ *Maxillary: 4mm*

▶ *Mandibular: 3mm*

▶ *Increase in inter-canine arch width*

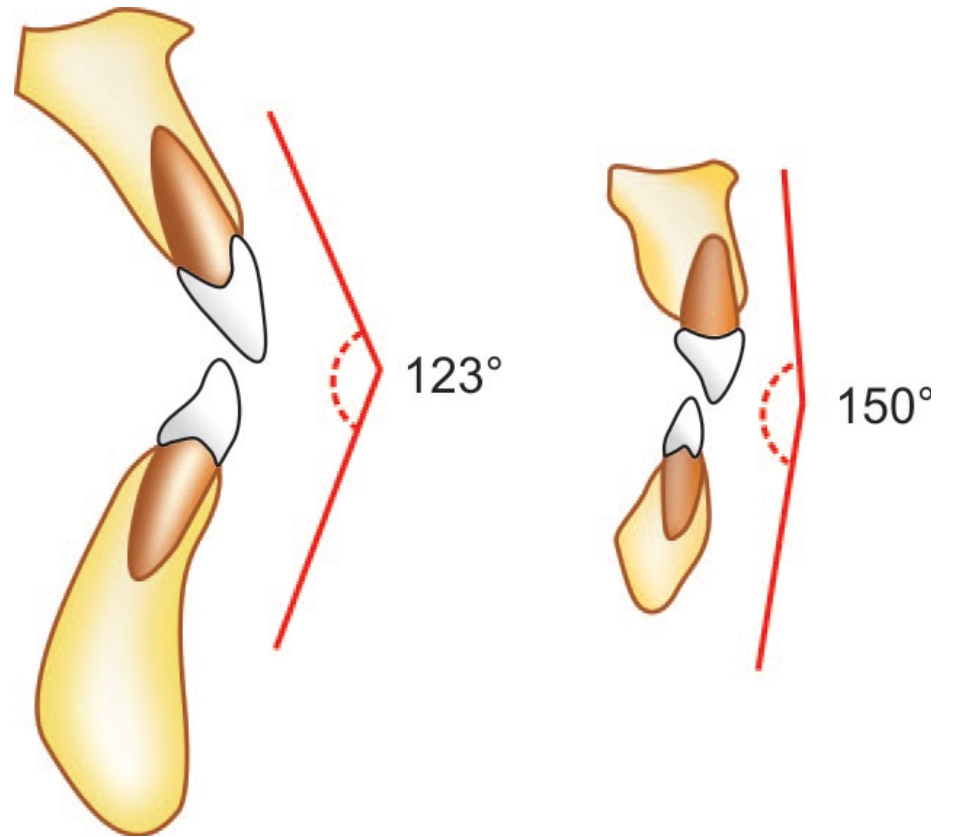
▶ *Males, maxilla: 6 mm*

▶ *Mandible: 4 mm*

▶ *Females, maxilla :4.5 mm*

▶ *Mandible: 4 mm*

- ▶ *Increase in intercanine arch length*
- ▶ *Change in interincisal angulations:*
- ▶ **Primary Incisors: 150°**
- ▶ **Permanent Incisors: 123°**




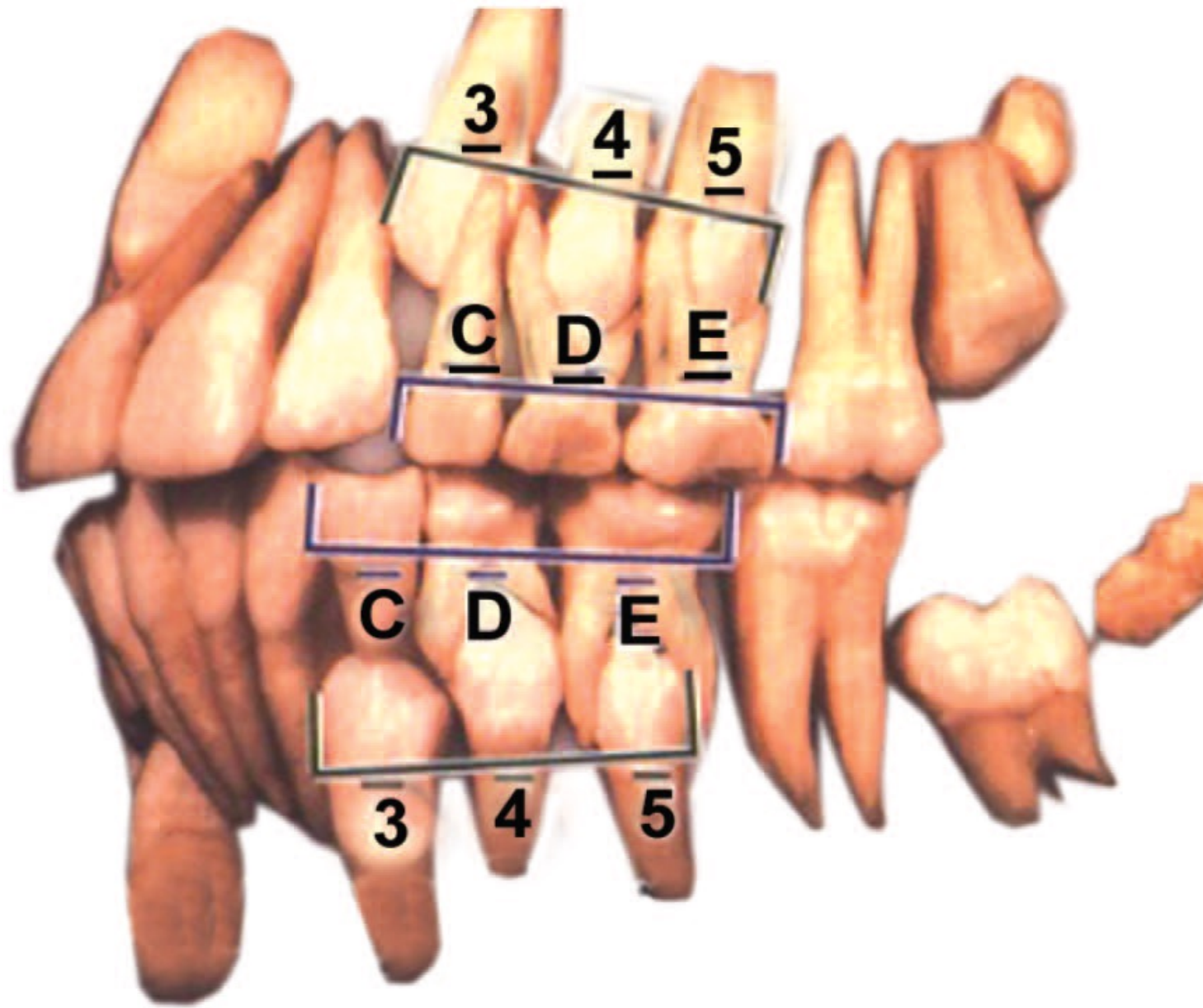
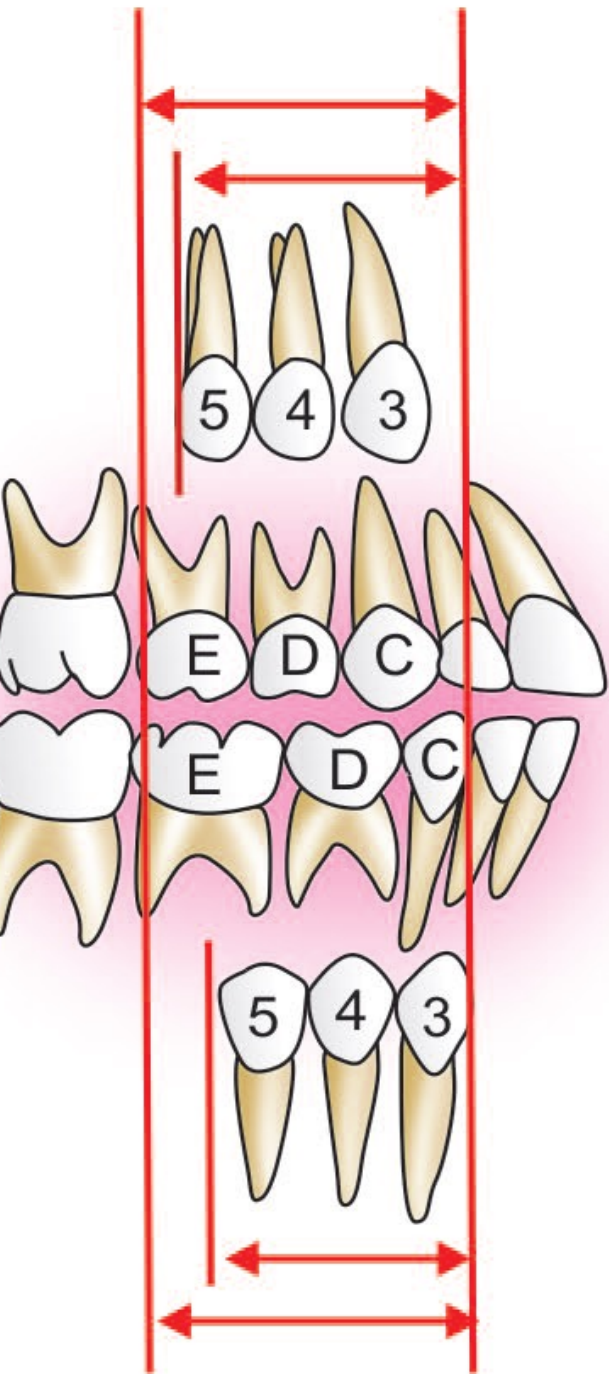
Inter-transitional period:

- ▶ In this period, the maxillary and mandibular arches consist of permanent incisors and permanent molars that sandwich the deciduous canines and molars.
- ▶ This phase lasts for 1½ years and is relatively stable.
- ▶ Only a few changes in the morphology of deciduous teeth are seen because they undergo attrition.

Second Transitional Period:

- ▶ This phase is characterized by replacement of deciduous molars and canines by premolars and permanent cuspids and the eruption of maxillary lateral incisors and canines.
- ▶ This takes place around 9 to 11 years of age and is very critical for the alignment of the erupting permanent teeth.

- 
- ▶ **Replacement of Deciduous Molars and Canine:**
 - ▶ **Leeway Space of Nance:** *The combined mesiodistal width of permanent canine and premolars is less than that of deciduous canine and molars. This extra space is called **Leeway space of Nance** and is utilized by mandibular molars to establish Class I relationship through late mesial shift.*
 - ▶ **Maxilla: 1.8mm (0.9mm each side)**
 - ▶ **Mandible: 3.4mm (1.7mm each side)**

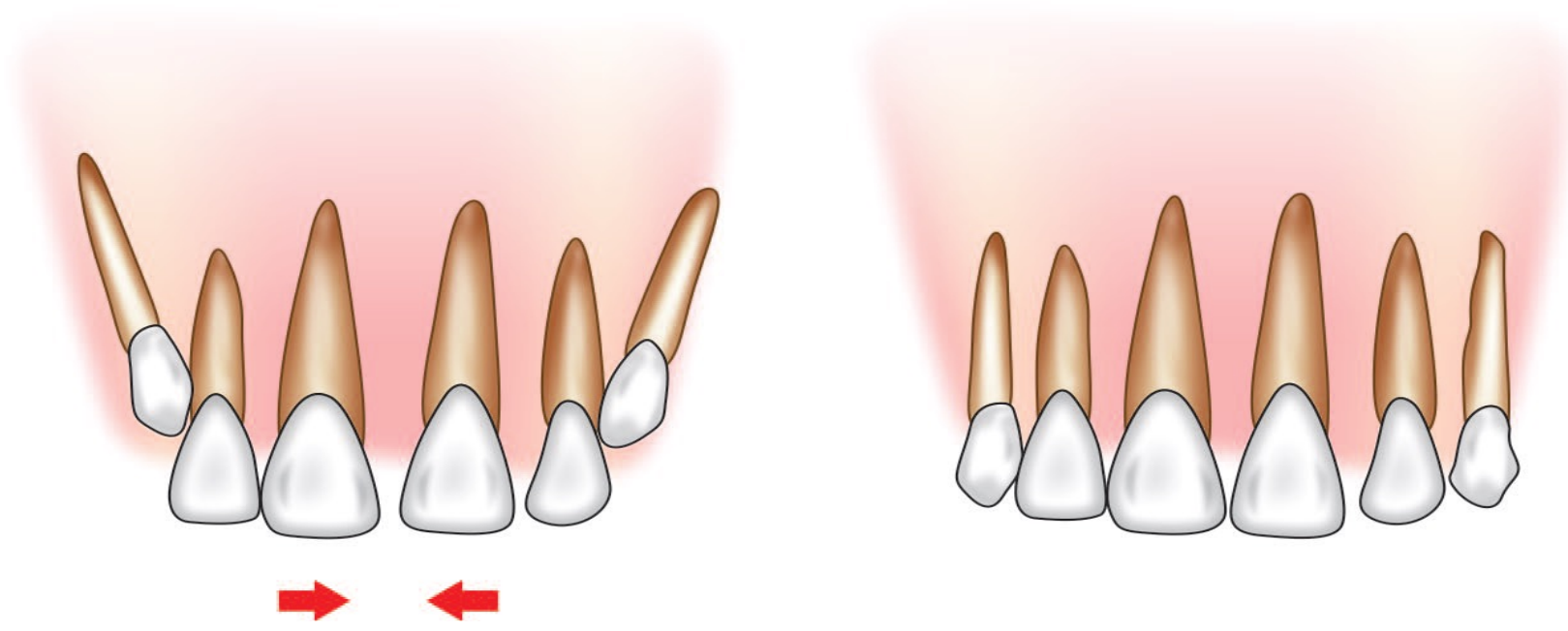
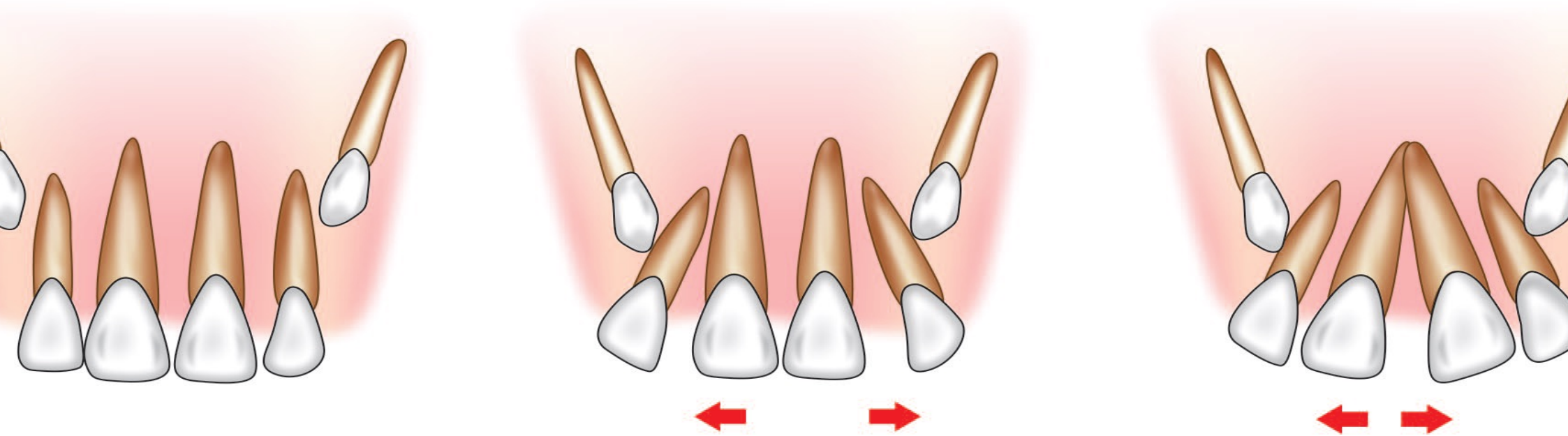


$$\text{Leeway space} = (C+D+E) - (3+4+5)$$



▶ ***Eruption of Maxillary Canine:***

- ▶ **Ugly Duckly Stage:** This self-correcting malocclusion is seen around 8 to 11 years of age or during eruption of canines and was first described by **H Broadbent** in 1937.
- ▶ As the permanent maxillary canines erupt they displace the roots of maxillary lateral incisors mesially. This force is transmitted to the central incisors and their roots are also displaced mesially. Thus, the resultant force causes the distal divergence of the crown in an opposite direction, leading to midline spacing. This is called Ugly Duckling Stage or Broadbent phenomenon.



Permanent Dentition

- ▶ Changes observed during permanent dentition:
- ▶ Horizontal overbite decreases
- ▶ Dental arches become shorter
- ▶ Vertical overbite decreases up to the age of 18 years by 0.5 mm
- ▶ Overjet decreases by 0.7 mm between 12 and 20 years of age

Andrews' Key Of Occlusion

- ▶ Molar inter-arch relationship
- ▶ Mesio-distal crown angulation
- ▶ Labiolingual crown inclination
- ▶ Absence of rotation
- ▶ Tights contacts
- ▶ Curve of spee
- ▶ **Bolton's** discrepancy.

Molar Inter-arch Relationship

- ▶ The distal surface of the distobuccal cusp of the upper 1st permanent molar made contact and occluded with the mesial surface of the mesiobuccal cusp of the lower 2nd molar.
- ▶ The mesiobuccal cusp of the upper 1st permanent molar fell within the groove between the mesial and middle cusps of the lower 1st permanent molar.
- ▶ The canines and premolars enjoyed a cusp-embrasure relationship buccally, and a cusp fossa relationship lingually.

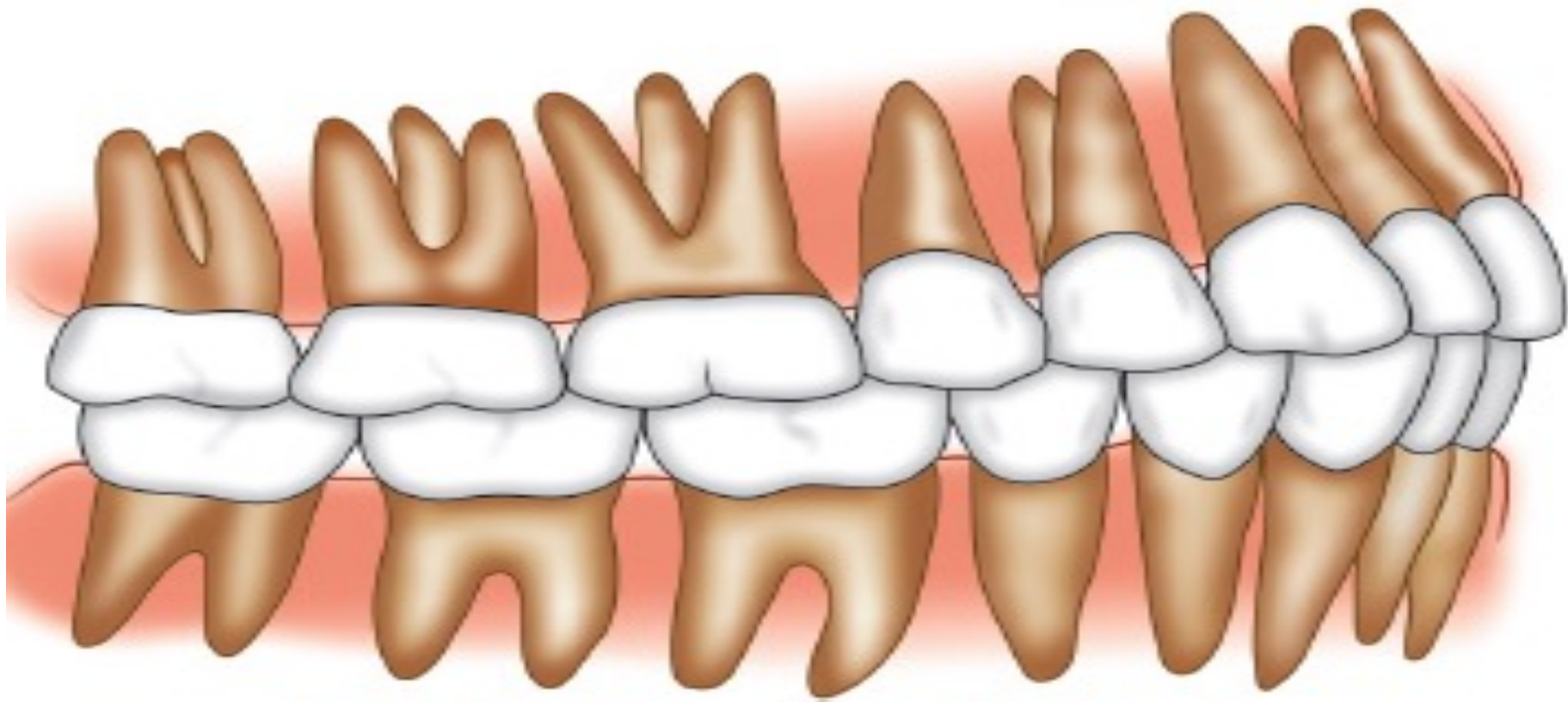
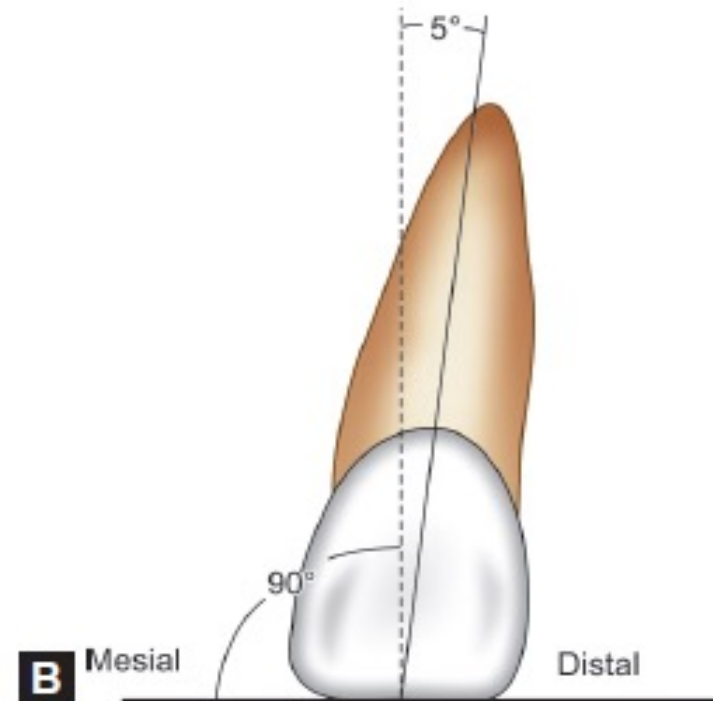
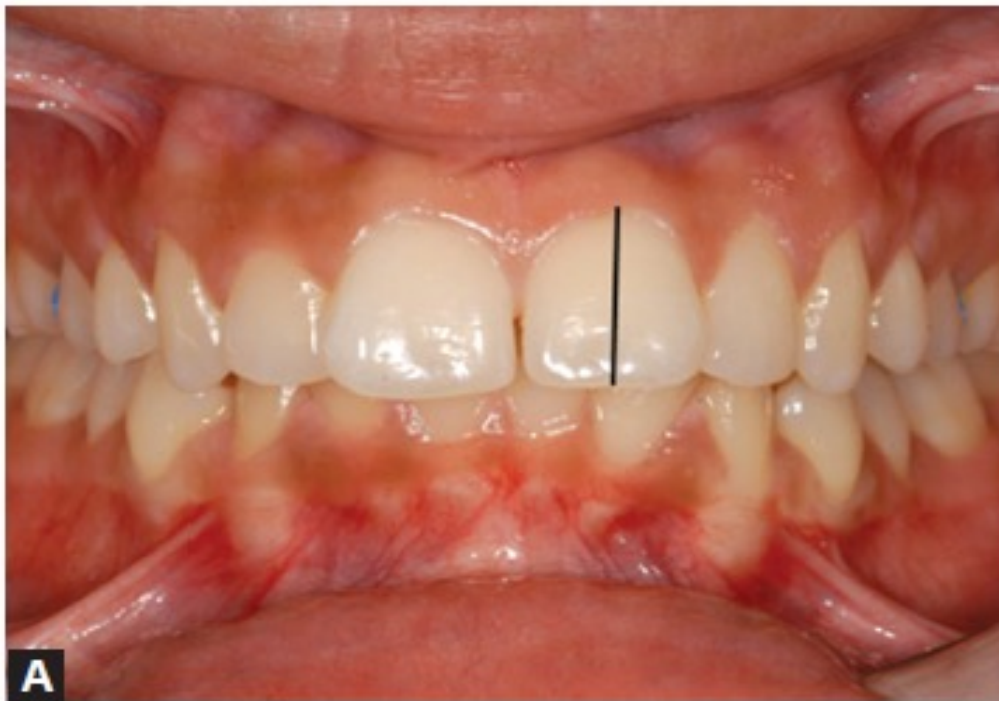

Fig. 16.24: Molar interarch relationship

Mesiodistal Crown Angulation

- ▶ It refers to angulation of long axis of crown rather than long axis of entire tooth.
- ▶ Gingival part of long axis of crown is distal to a incisal or occlusal part.
- ▶ Long axis of crown for all teeth judged by a mid-developmental ridge and in molars judge by a developmental groove.



Figs 16.25A and B: Mesiodistal crown angulation

Crown Inclination:

- ▶ Crown inclination refers to the labiolingual or buccolingual inclination of the long axis of the crown, not to the inclination of the long axis of the entire tooth.
- ▶ Crown inclination is determined by the resulting angle between a line 90 degrees to the occlusal plane and a line tangent to the middle of the labial or buccal clinical crown.
- ▶ Cervical area of crown is lingually placed then it is called as positive crown inclination and if it is more buccally then it is called as negative crown inclination.

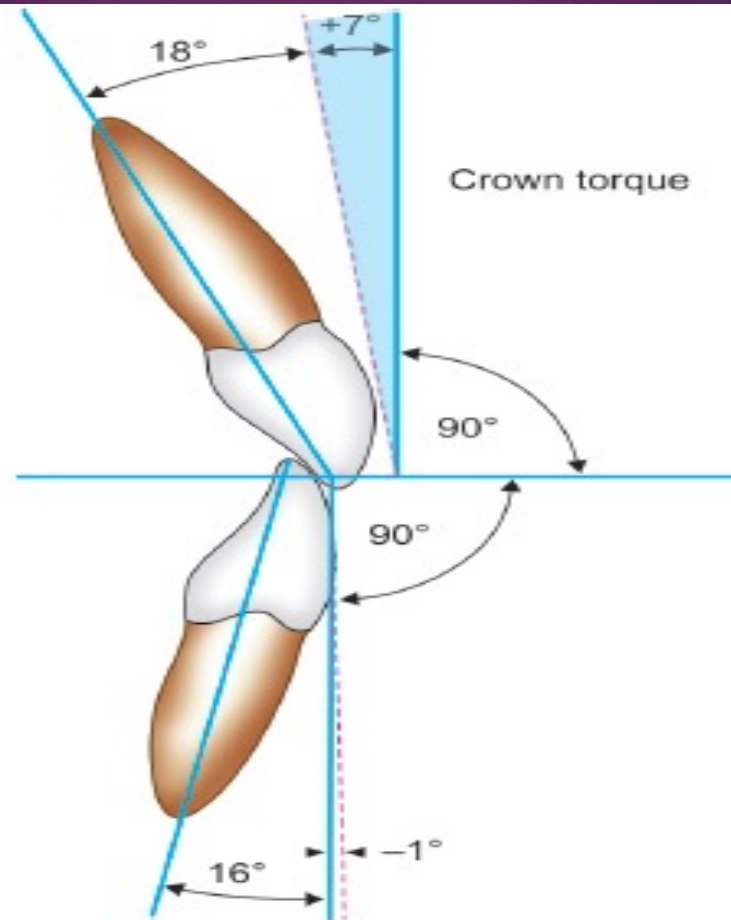
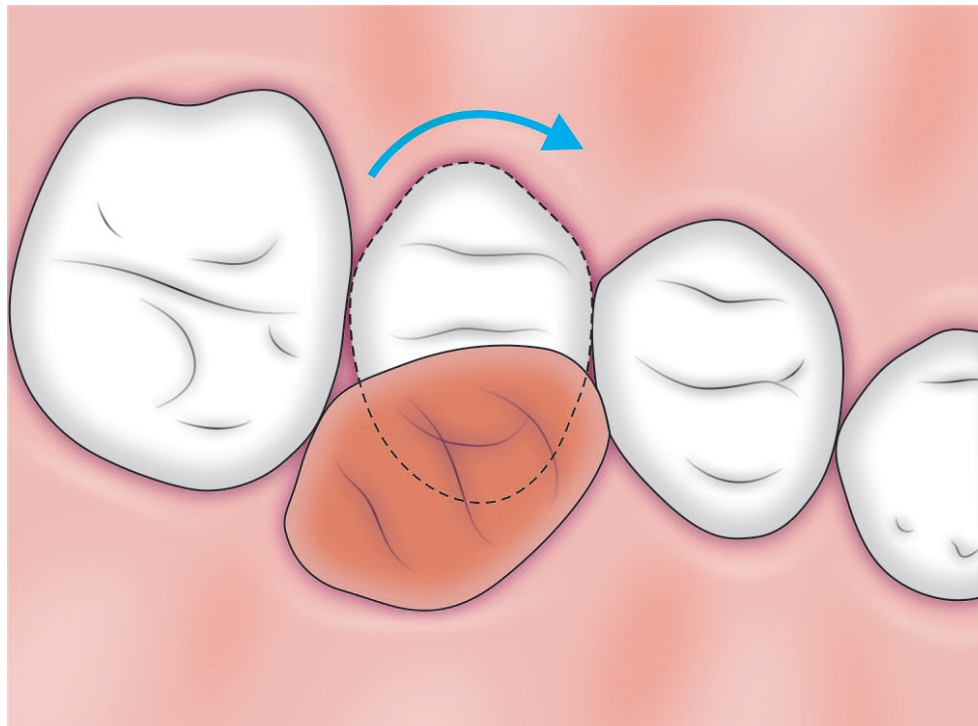


Fig. 16.26: Crown inclination

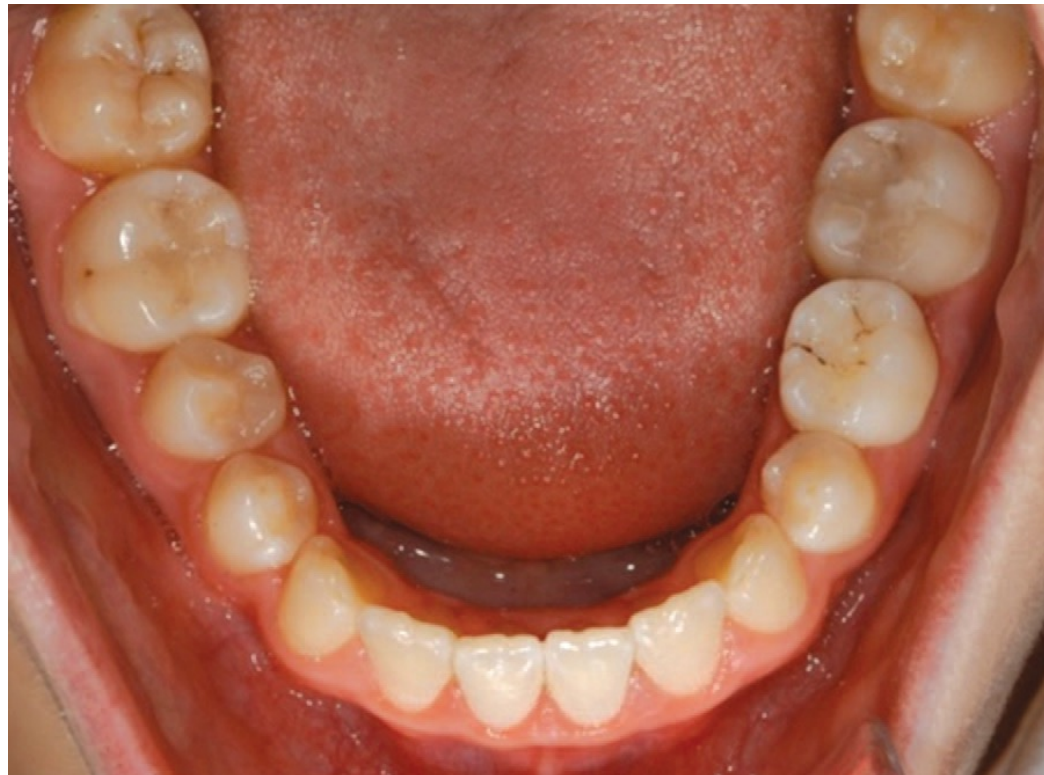Absence of Rotation

- ▶ Rotated teeth will occupy more space hence normal occlusion should be free from rotation.



Tights Contacts

- ▶ Permanent dentition should have close contact to optimize space.



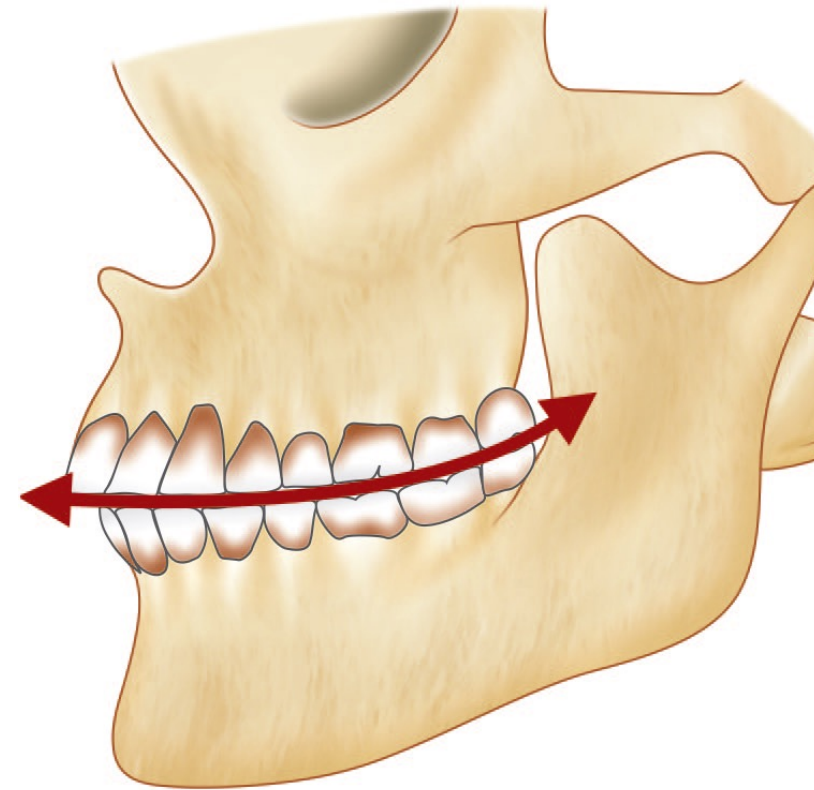
Curve of Spee:

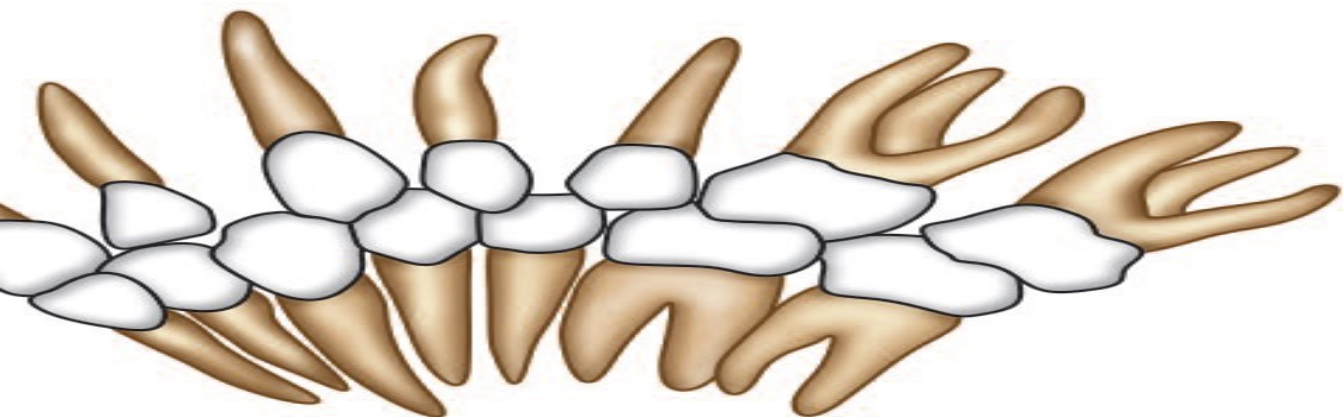
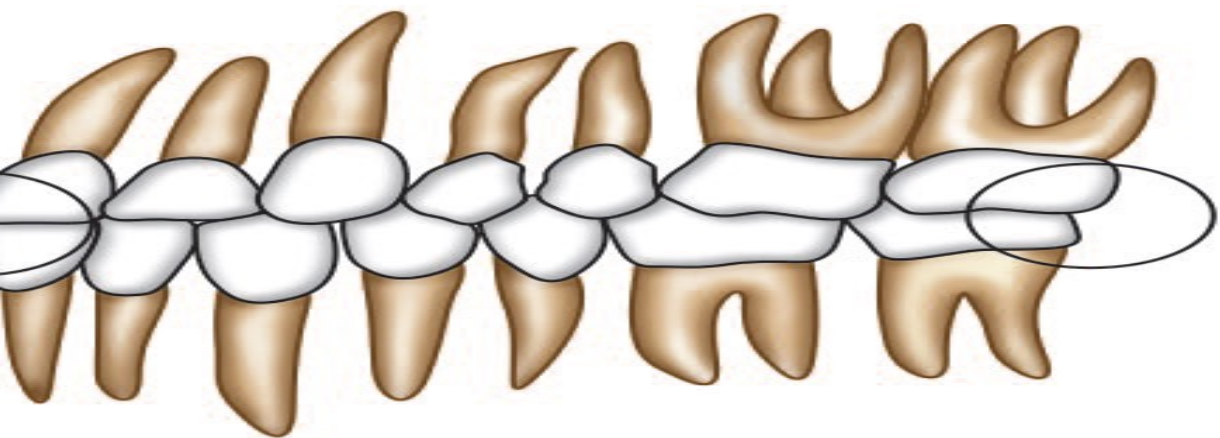
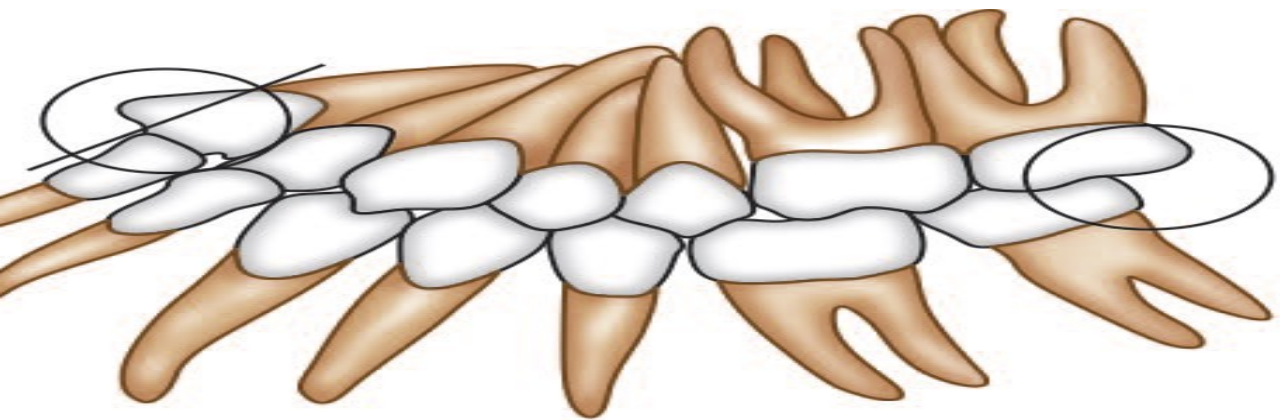
Occlusal plane should be flat with curve of Spee not exceeding 1.5 mm.

A) A deep curve of Spee results in a more confined area for the upper teeth, creating spillage of the upper teeth progressively mesially and distally;

B) A flat plane of occlusion is most receptive to normal occlusion;

C) A reverse curve of Spee results in excessive room for the upper teeth

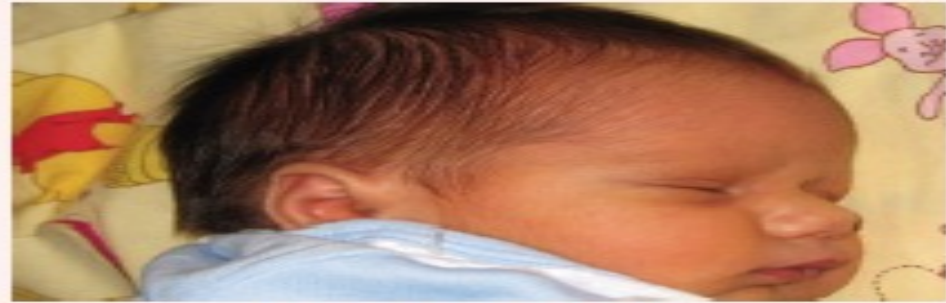



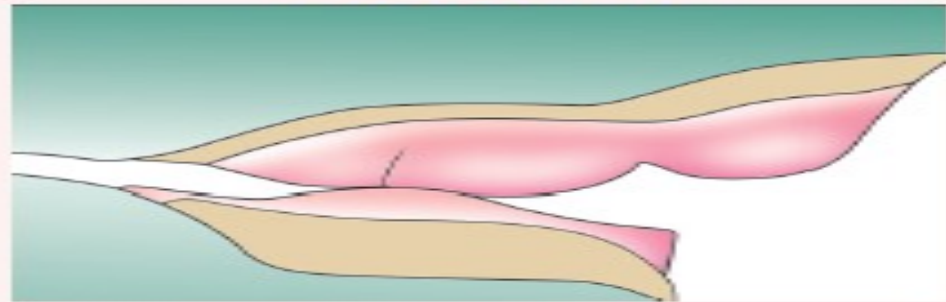
Self Correcting Anomalies:

- ▶ Pre-Dentate Period

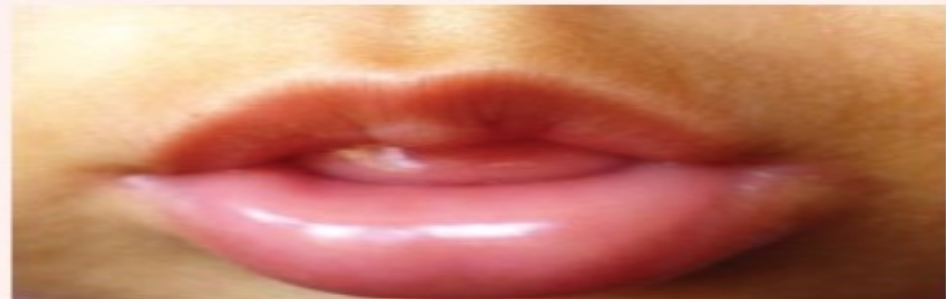Retrognathic mandible



Anterior open bite

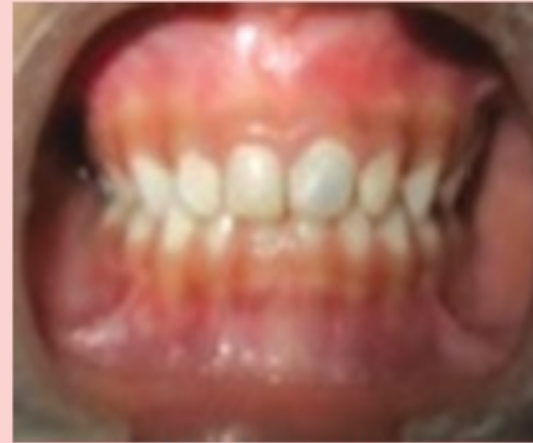

Infantile swallow

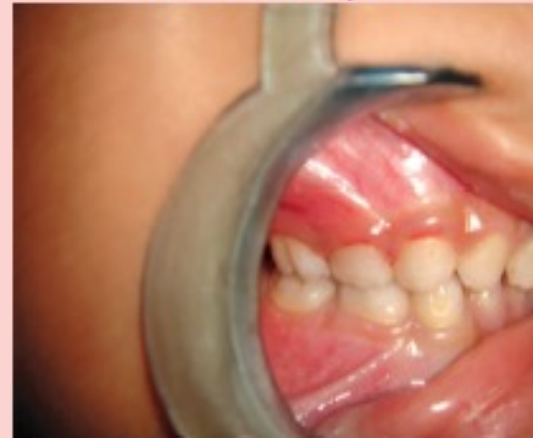

► Deciduous Dentition Period

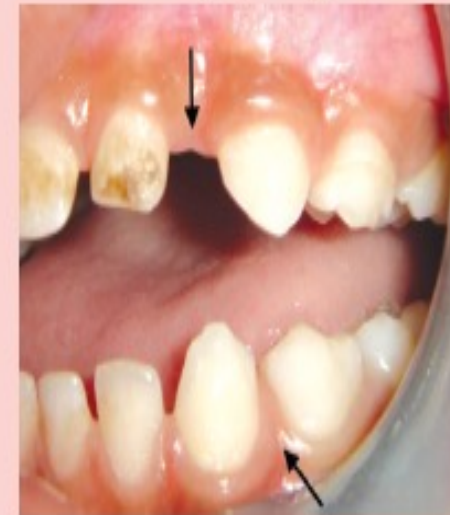Deep bite



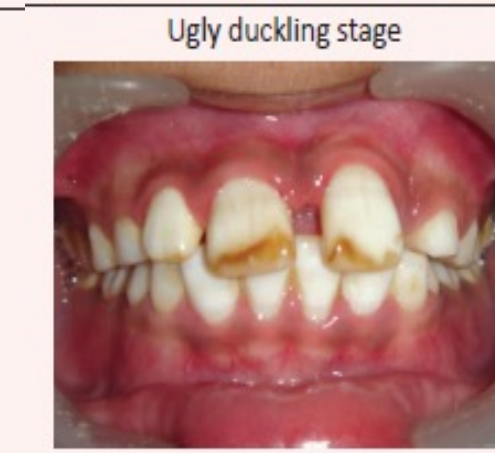
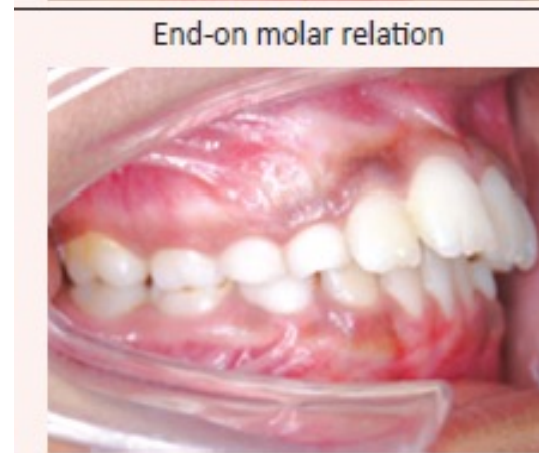
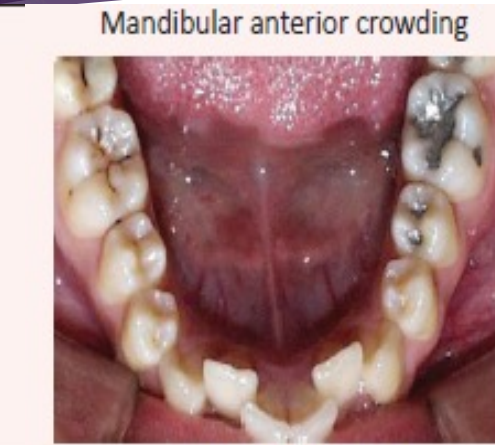
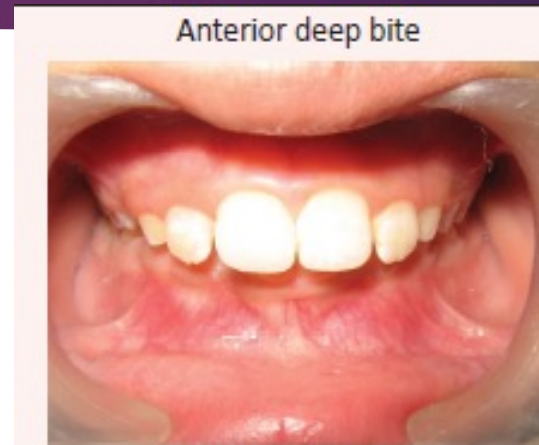Flush terminal plane



Primate and physiologic spacing



► Mixed Dentition Period





Thank You