

# SKELETAL MATURITY INDICATORS

Dr. Tilak Parikh

1

# CONTENTS

2

- INTRODUCTION
- REQUIREMENTS FOR AN IDEAL MATURITY INDICATOR
- MATURITY INDICATORS
- METHODS OF SKELETAL AGE ASSESSEMENT
- ANATOMY OF HAND AND WRIST
- METHODS OF ASSESSEMENT OF SKELETAL GROWTH USING HAND WRIST RADIOGRAPH
  1. GREULICH AND PYLE
  2. BJORK, GRAVE AND BROWN METHOD
  3. HAGG AND TARANGER METHOD
  4. FISHMAN'S SKELETAL MATURITY INDICATOR
  5. SINGER'S METHOD OF ASSESSMENT
- CERVICAL VERTEBRAE MATURATION INDEX
- TOOTH MINERALIZATION AS AN INDICATOR OF SKELETAL MATURITY
- FRONTAL SINUS DEVELOPMENT
- MID-PALATAL SUTURE OSSIFICATION

- CONCLUSION
- REFERENCES

# INTRODUCTION

- ▶ An understanding of **events of growth** is of primary importance in the practice of clinical orthodontics.
- ▶ Ricketts stated that to take advantage of growth, we must have idea of
  - 1) **Magnitude**
  - 2) **Direction**
  - 3) **Timing**

By using the element of timing, maximum growth in conjunction with one's knowledge of magnitude and direction, great orthodontic results can be achieved.

- ▶ Several methods are used to assess the **level of maturity** attained by a child during postnatal growth. Children of the same age **may vary** in their maturity status, therefore, several biologic **maturity indicators** have been developed to assess the **progress toward full maturation** of an individual at **various times during growth**.

## REQUIREMENTS FOR AN IDEAL MATURITY INDICATORS

- ▶ Should be **safe**.
- ▶ Should be **non- invasive**.
- ▶ Should be **accurate**.
- ▶ **Require minimum radiation**.
- ▶ Stages of maturity **should be well defined** and **easily identifiable**.
- ▶ **Cost-effective**.
- ▶ **Minimum armamentarium** and personnel requirements.
- ▶ Method should be **simple to conduct**.
- ▶ Should be **valid over time and across age-groups**.

# CLINICAL IMPORTANCE

- ▶ The key to successful treatment in growing patient is harnessing of growth
- ▶ Skeletal maturity indicators helps in:-
  - 1) To determine the potential vector of facial development.
  - 2) To determine the amount of significant cranio-facial growth potential left.
  - 3) To decide onset of treatment.
  - 4) To decide type of treatment.
    - a) Orthopedic
      - i) Removable
      - ii) Fixed
    - b) Orthodontic
    - c) Orthognathic surgical procedure
    - d) Combination of any of the above.
  - 5) To evaluate treatment prognosis.

# MATURITY INDICATORS

The key to successful treatment is to **start at the right age**. The age can be expressed in **number of ways:-**

1. Neural age
2. Mental age
3. Chronological age
4. Sexual/pubertal age
5. Dental age
6. Skeletal/anatomical/radiological age.

## NEURAL AGE

- ▶ The neural age helps us to understand that the **patient is mentally developed**, to understand the need for treatment and to what extent would he/she be able to cooperate and follow proper instructions.


# MENTAL AGE

9

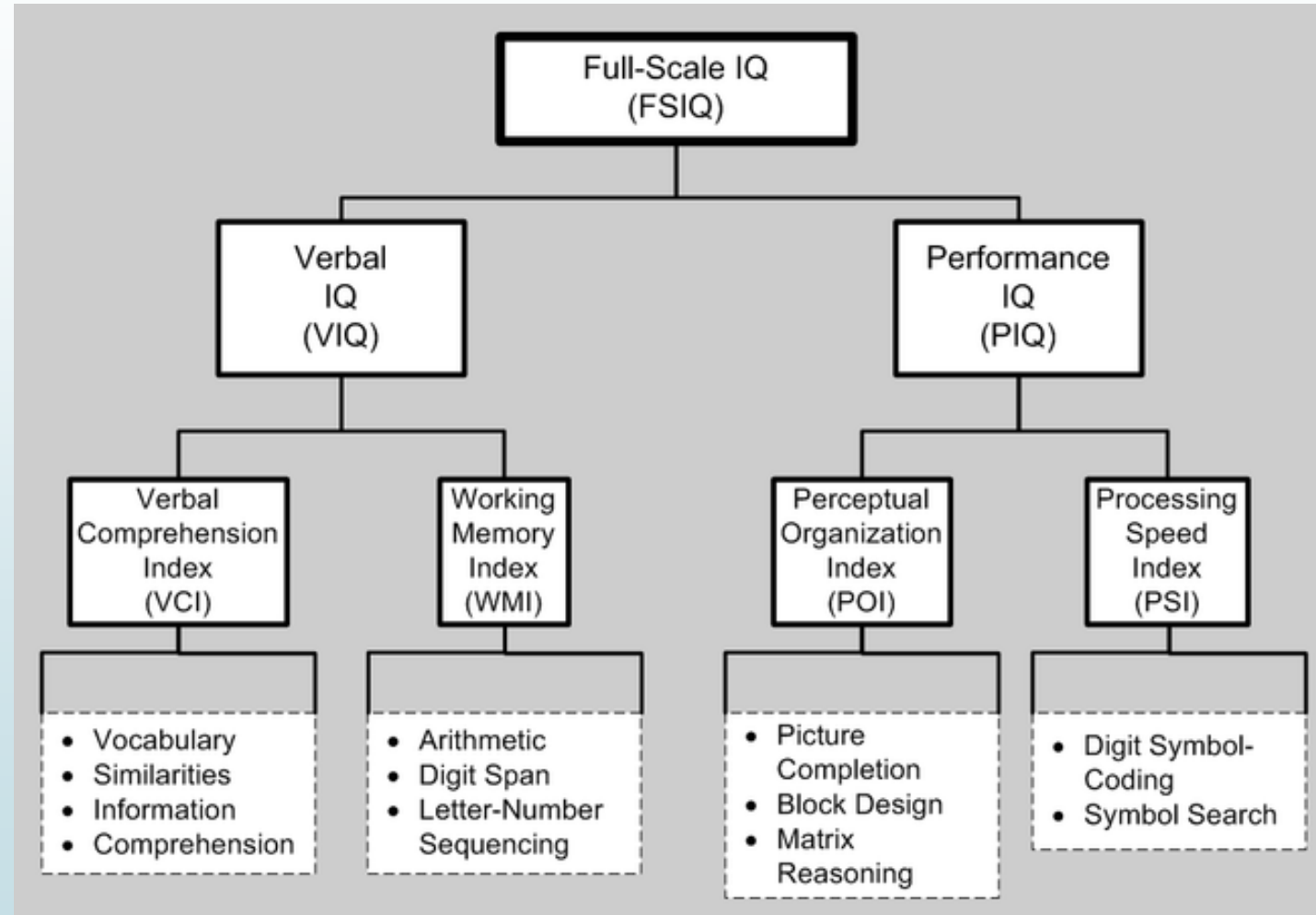
- ▶ There have been attempts to devise performance tests, which measure the elusive quantity conveniently described as "intelligence" by **the Stanford-Binet test/ the Wechsler scale.**
- ▶ **These are of importance as they help in determining the outlook of the patient towards treatment. They also help in assessing the expected level of cooperation that can be expected from a patient.**
- ▶ The mental age is thus an index of maturation of the mind, which increases at a rate depending on many intrinsic and environmental factors.

- ▶ A convenient way of classifying intelligence test performance is by the use of the concept of the **Intelligence Quotient (IQ)** which is the mental age expressed as a percentage of the chronological age.
- ▶ That is, a child with a mental age of 12 years and chronological age of 10 would have an IQ of 120.

**Stanford–Binet Fifth Edition (SB5) classification<sup>[4]</sup>**

<b>IQ Range ("deviation IQ")</b>	<b>IQ Classification</b>
<b>145–160</b>	Very gifted or highly advanced
<b>130–144</b>	Gifted or very advanced
<b>120–129</b>	Superior
<b>110–119</b>	High average
 <b>90–109</b>	Average
<b>80–89</b>	Low average
<b>70–79</b>	Borderline impaired or delayed
<b>55–69</b>	Mildly impaired or delayed
<b>40–54</b>	Moderately impaired or delayed

# Wechsler Scale



## CHRONOLOGICAL AGE

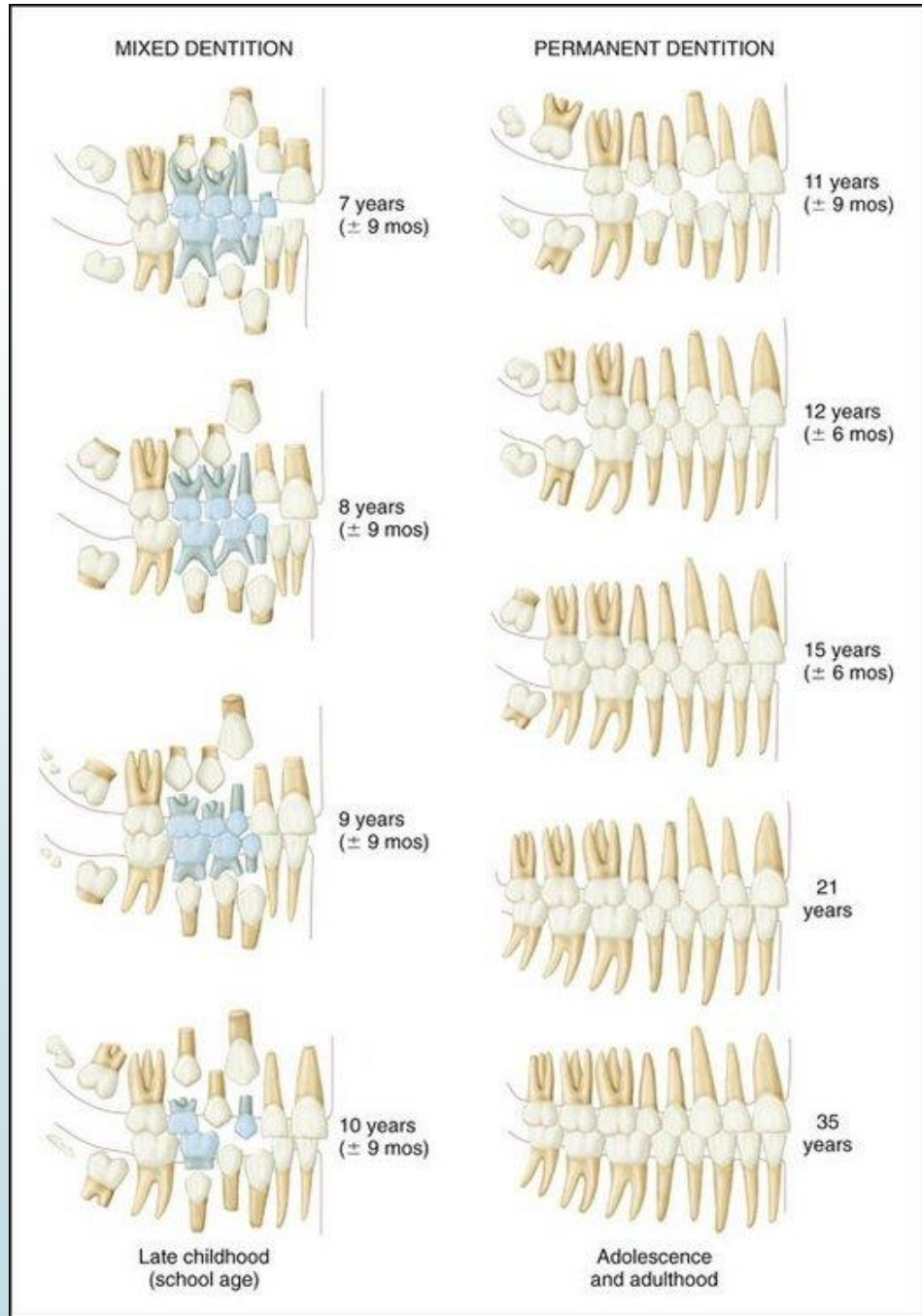
- It is defined as age **measured by years lived since birth.**
- It is considered as a **poor indicator of maturity** as it provides little validity for identifying the stages of development progress from adolescence to adulthood.
- It may help to categorize the individuals as early, average or late maturer.
- This enables an orthodontist to determine and predict the rate and magnitude of facial growth and help decide the time, duration and method of treatment

# SEXUAL/PUBERTAL AGE

- **Development of secondary sexual characteristics.**
- Puberty begins and extends over a longer period of about 5 years in boys starting from his 9 or 10 birthday till the age of 15 and in girls it extends for 3.5 years in girls from the age of 8 to 11.
- **HAGG and TARANGER (1980)** - various pubertal events:
  - **Girls** *If the menarche has occurred* - peak height velocity (PHV) has been attained and the growth rate is decelerating.
  - *If the menarche not occurred* - growth rate may be decreasing but has certainly not yet reached the level of pubertal growth spurt. (20 mm per year).
  - **Boys** *If a boy has a prepubertal voice*, - peak height velocity has not yet been reached.
  - **Voice change begun** - the boy is in the pubertal spurt.
  - If a boy has a **male voice** - the growth rate has begun to decelerate
  - No boy will reach the end of the pubertal spurt without having a male voice.

## DENTAL AGE

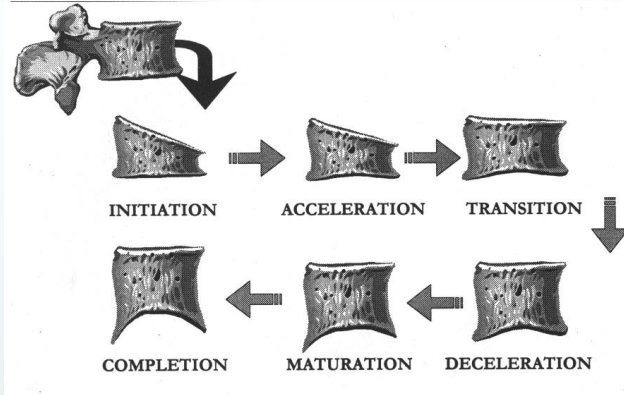
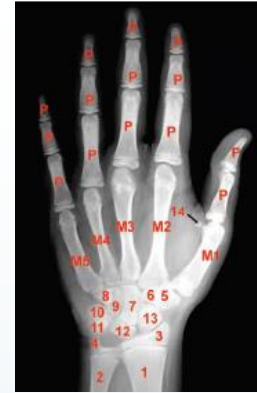- ▶ **Spier (1918)** was the **first to associate** tooth eruption to growth stature.
- ▶ **Chronological age** is correlated to the eruption time table of primary and secondary teeth.
- ▶ **Radiographic appearances of developing jaws and teeth** are taken into account.
- ▶ Factors such as **completion of crowns, cusps and roots** are studied.
- ▶ **Radiological development of root of lower canine** is considered to be an accurate method to correlate dental age to skeletal age.



## SKELETAL AGE

- ▶ Skeletal/radiological/anatomical age is considered to be the **most reliable age estimator** for assessment of growth for **orthodontic purposes**.
- ▶ It is closely related to the growth of an individual.

# HAND WRIST RADIOGRAPHS

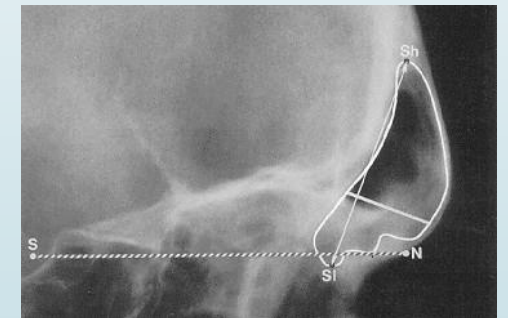
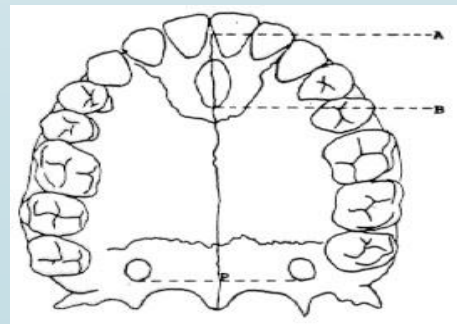


## Methods of Skeletal Age Assessment

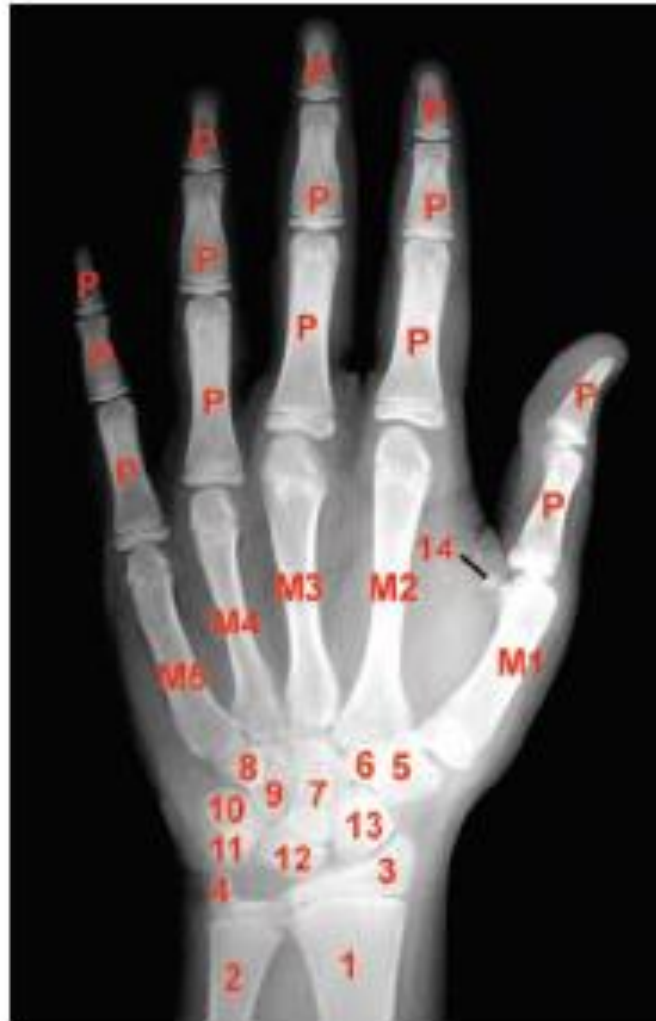Cervical Vertebrae

Frontal sinus

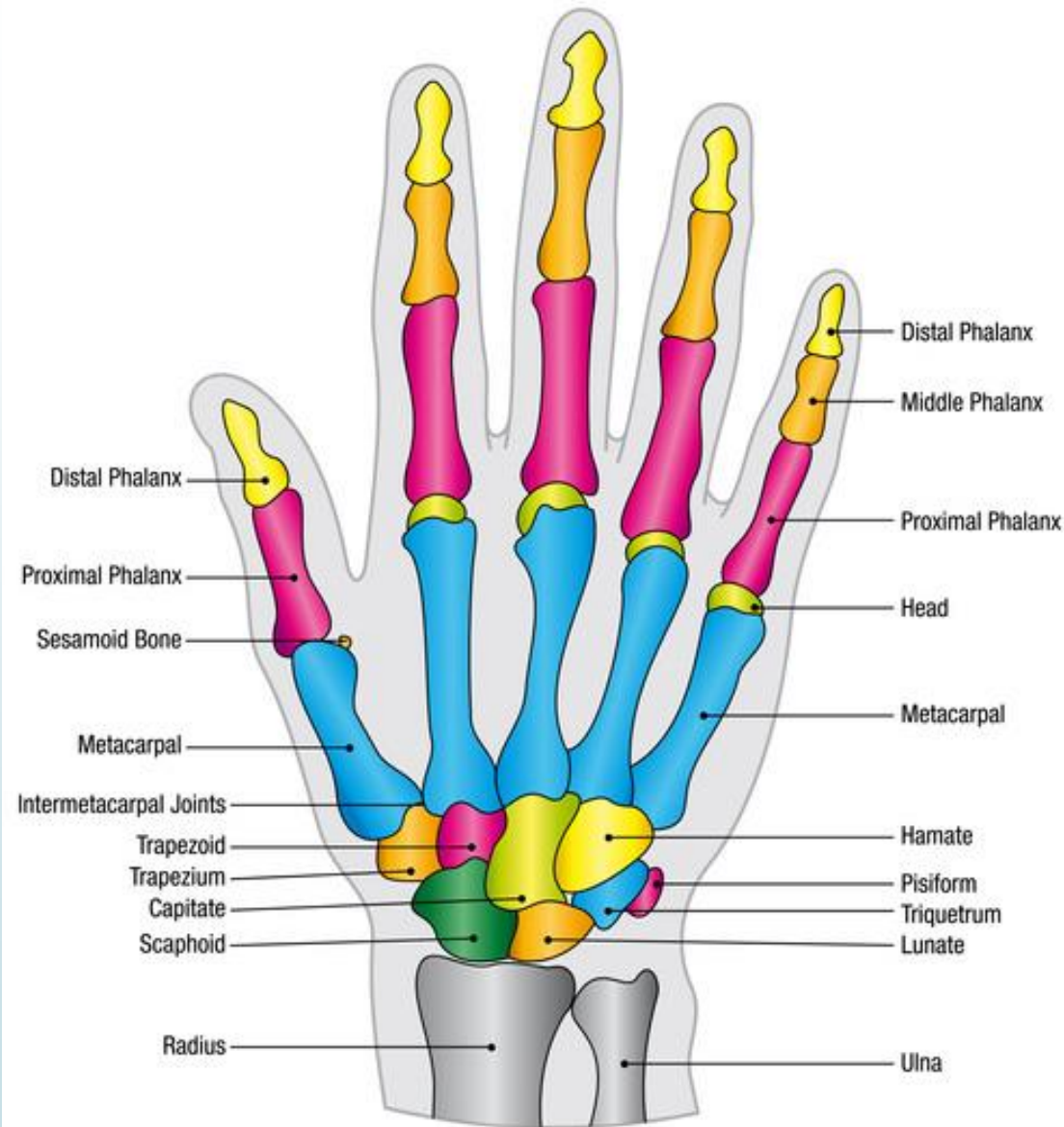
Mid sagittal suture



# HAND AND WRIST RADIOGRAPH



- 1.Radus
- 2.Ulna
- 3.Distal epiphysis of radius
- 4.Distal epiphysis of ulna
- 5.Trapezium
- 6.Trapezoid
- 7.Capitate
- 8.Hamular process of Hamate
- 9.Hamate
- 10.Triquetral
- 11.Pisiform
- 12.Lunate
- 13.Scaphoid
- 14.Sesamoid



- ▶ The hand-wrist region is made up of the following four groups of bones:
- ▶ 1. Distal ends of long bones of forearm (Radius and Ulna)
- ▶ 2. Carpals
- ▶ 3. Metacarpals
- ▶ 4. Phalanges

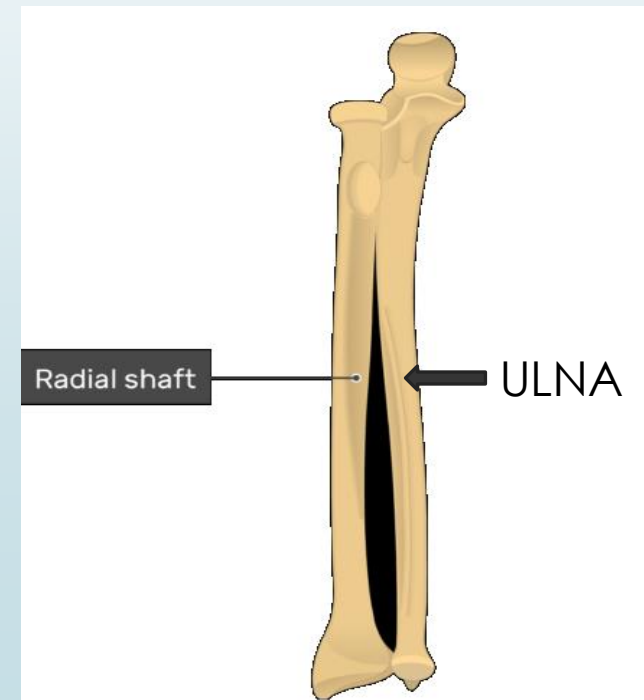
# RADIUS

- ▶ The radius is the lateral bone of the forearm. It has an upper end, shaft and lower end.
- ▶ The upper head is disc shaped which articulates with humerus at elbow joint.
- ▶ The lower end is widest part of radius



# ULNA

- ▶ The ulna is the medial bone of the forearm. It has upper end, shaft and lower end.
- ▶ The upper end has a radial notch where it articulates with the head of radius to form superior radio-ulnar joint.
- ▶ The lower end articulates with ulnar notch of the radius to form inferior radio-ulnar joint



## CARPAL BONES

They consist of 8 small bone, irregularly shaped bones arranged in two rows.

➤ Proximal row(Lateral to Medial)

➤ Scaphoid

➤ Lunate

➤ Triquetral

➤ Pisiform

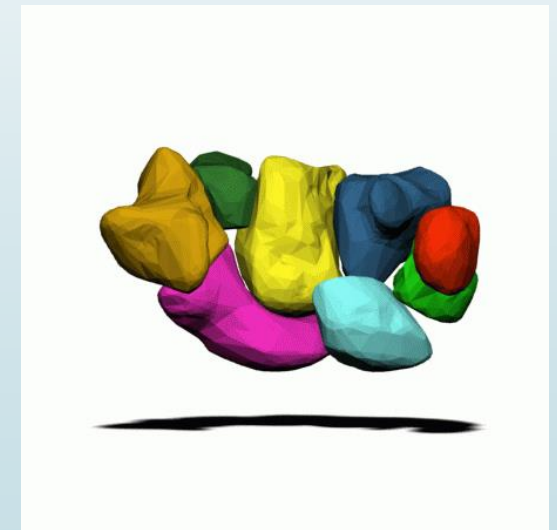
➤ Distal row(Lateral to Medial)

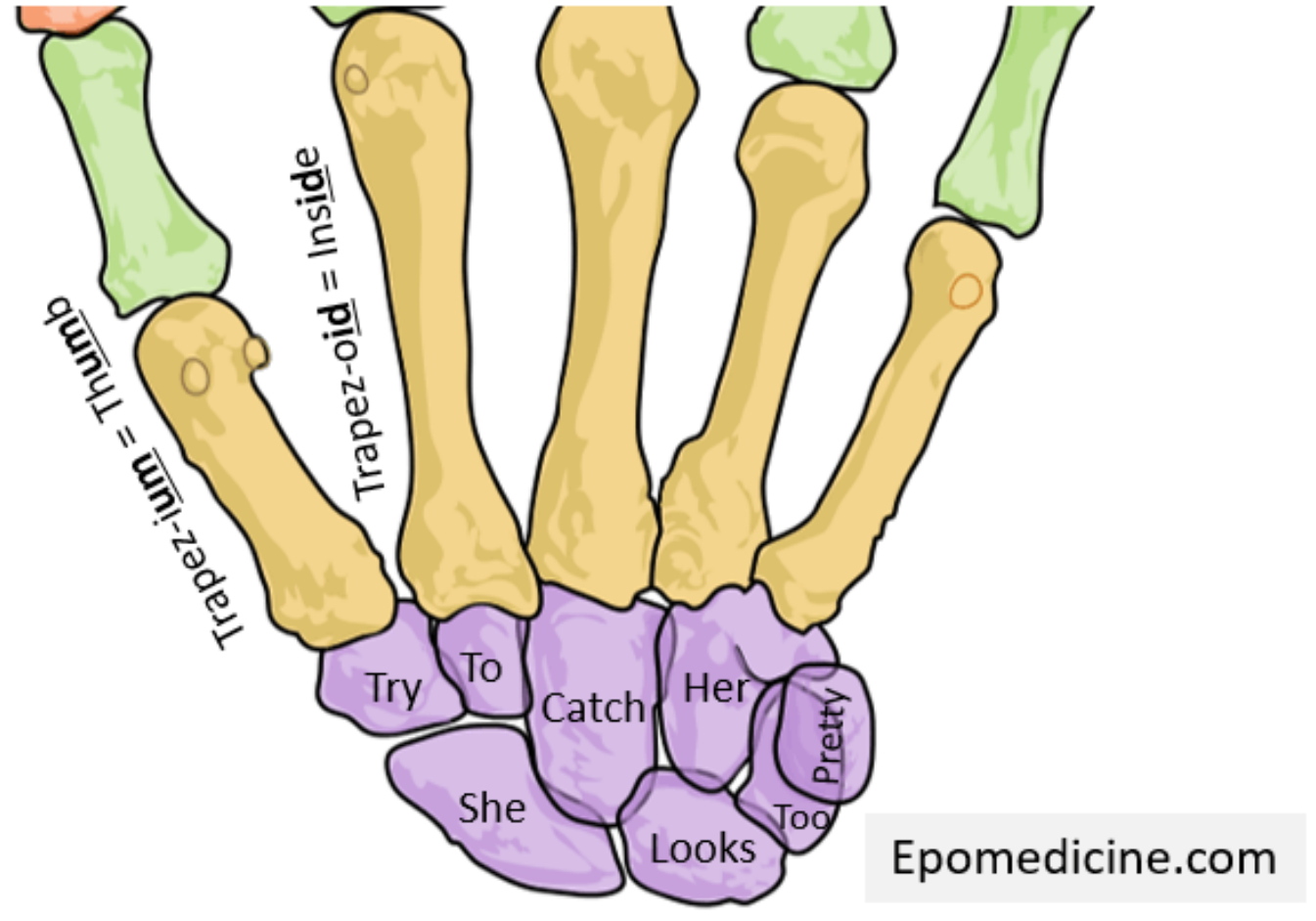
➤ Trapezium

➤ Trapezoid

➤ Capitate

➤ Hamate

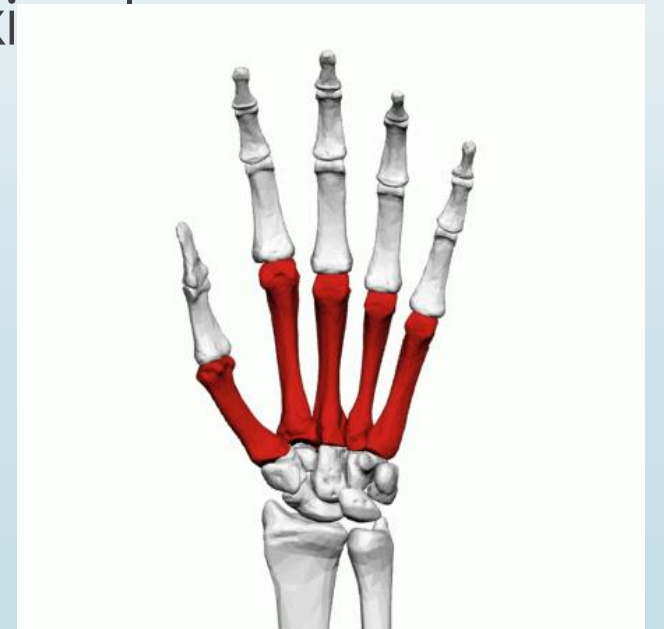




**Mnemonics- She looks to pretty**  
**Try to catch her**

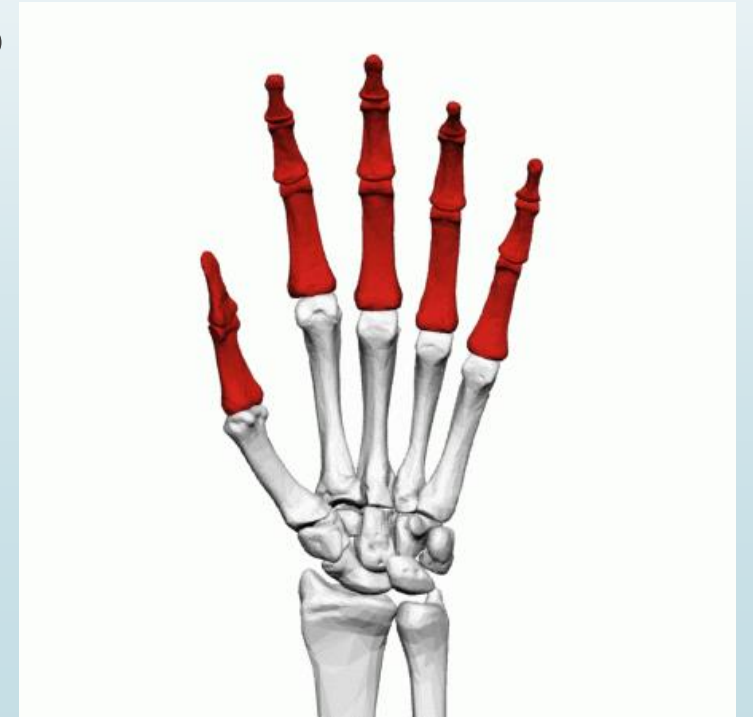## METACARPALS

- ▶ 5 miniature long bones forming the skeletal framework of the palm.
- ▶ Lies between carpals and phalanges
- ▶ Each metacarpal ossifies from one primary centre (shaft) and a secondary centre on the distal end, **except for the first metacarpal** where it appears at the proximal end.



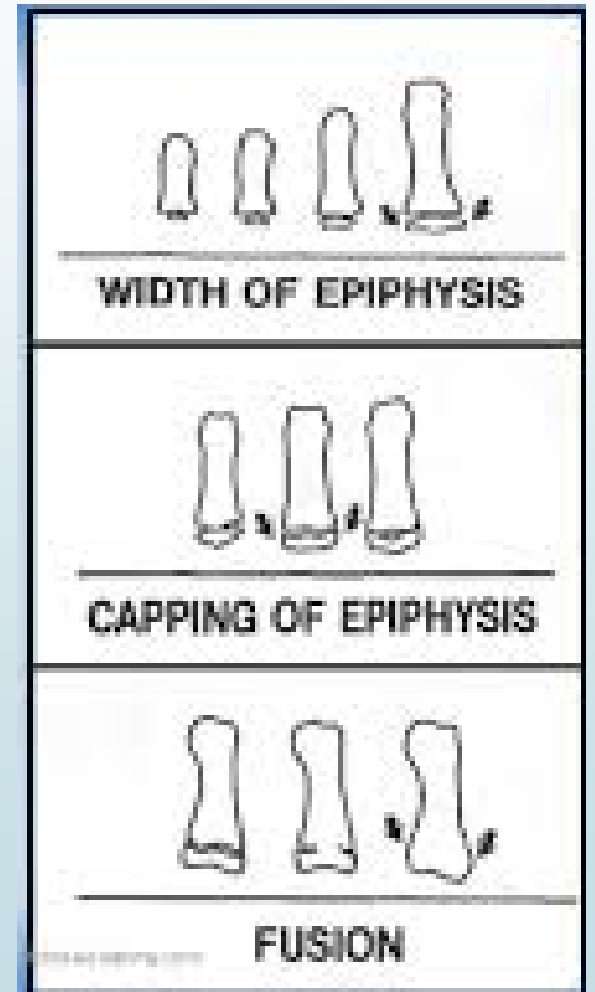
## THE PHALANGES

- There are 14 phalanges in each hand, 3 for each finger and 2 for thumb.
- Proximal, middle and distal phalanx
- Middle phalanx absent for thumb
- The small round bone located in the thumb in the tendons is called the **sesamoid bone**



The phalanges and carpal bones have a pattern of ossification,

1. Epiphysis **width less** than that of diaphysis.
2. Epiphysis **width equal to** that of diaphysis.
3. Epiphysis **caps** the diaphysis.
4. Epiphysis starts **fusing** with the diaphysis.



## METHODS OF ASSESSEMENT OF SKELETAL GROWTH

### **A) Using Hand-Wrist Radiograph**

- 1) Greulich and Pyle**
- 2) Bjork, Grave and Brown method**
- 3) Hagg and Taranger method**
- 4) Fishman's Skeletal maturity indicator**
- 5) Singers method of assessment**

### **B) Cervical vertebrae maturity indicators**

### **C) Tooth mineralization as an indicator of skeletal maturity**

### **D) Frontal sinus development**

### **E) Mid-Palatal suture ossification**

## Indications

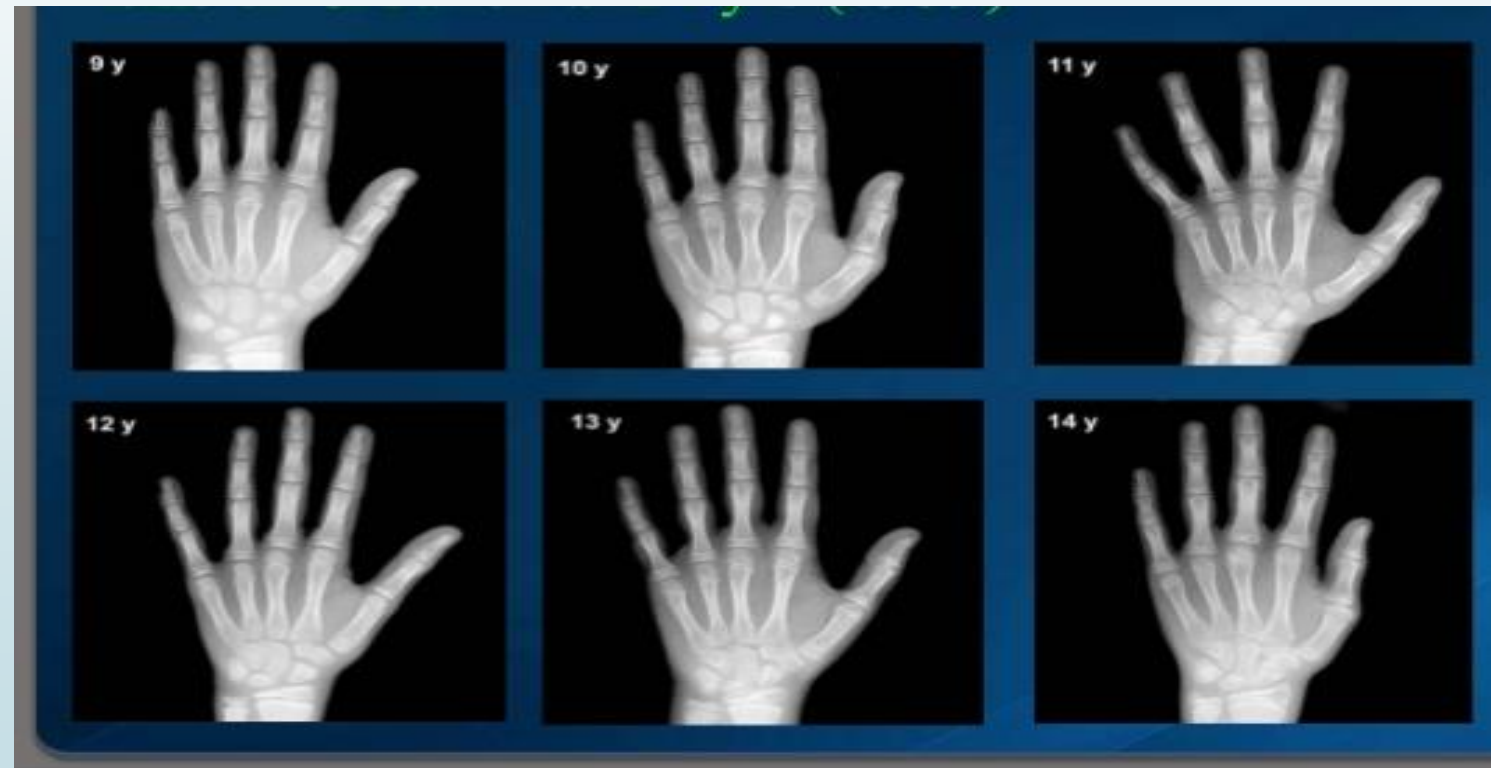
- Major **discrepancy** between **dental age and chronological age**
- Determination of skeletal maturity status **prior to treatment of skeletal malocclusion.**
- To assess the skeletal age of patient whose **growth is affected.**
- To **predict** future skeletal maturation rate and status.
- To **predict the pubertal growth spurt.**
- Indicated in patients with skeletal malocclusion needing **orthognathic surgery.**

## 1) GREULICH AND PYLE METHOD

1929 – Studies were started at Western Reserve University School of Medicine in Ohio and large number of children of different age group were enrolled for the study. Radiographs of left shoulder, elbow, hand and knee were taken.

1937 – “ Atlas of Skeletal Maturation of Hand” published by Todd based on the data collected in this study.

- Greulich and Pyle published an atlas containing ideal skeletal age pictures of hand-wrist for different chronological ages, and for each sex. Each photograph in the atlas is representative of a particular age. The patient's radiograph is matched with one of the photographs in the atlas.

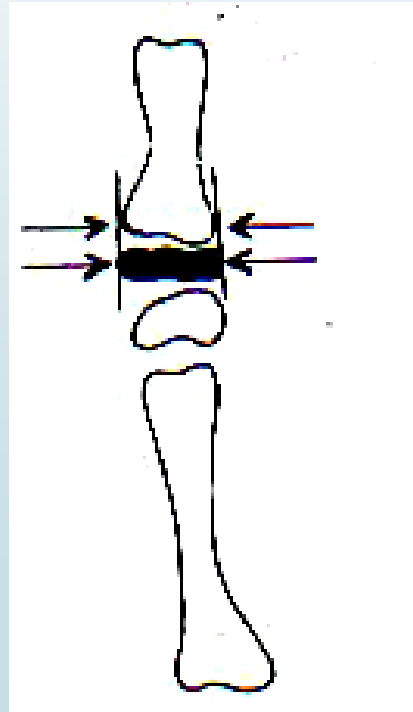


## 2) BJORK, GRAVE AND BROWN METHOD

- ▶ They have divided skeletal development into 9 stages.
- ▶ Each stage represents a level of skeletal maturity
- ▶ Schopf in 1978 associated each of these stage with a particular chronological age.

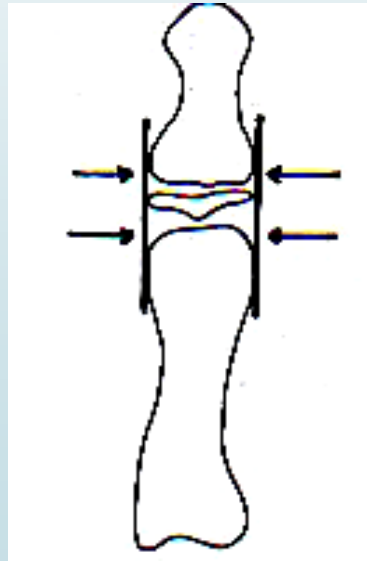
## FIRST STAGE OF MATURATION (M = 10.6Y, F = 8.1Y)

- ▶ Epiphysis of the proximal phalanx of index finger (PP2) has same width as the diaphysis.
- ▶ It occurs approximately 3 years before the peak of pubertal growth spurt.



## SECOND STAGE OF MATURATION (M = 12 Y, F=8.1 Y)

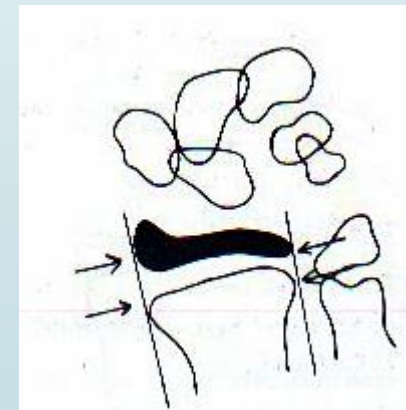
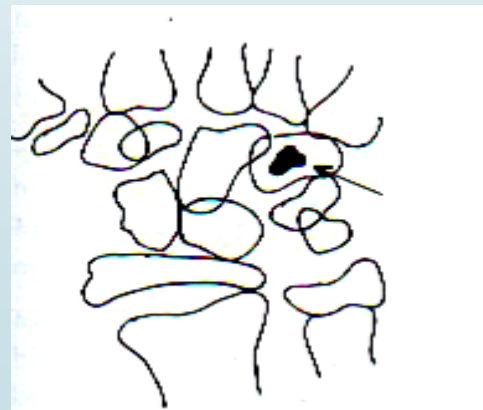
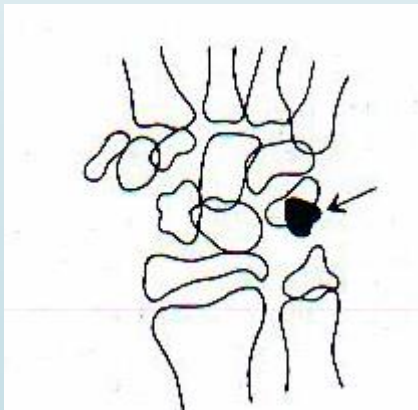
- ▶ The epiphysis of the middle phalanx of the middle finger (MP3) has same width as the diaphysis
- ▶ This stage is noticed prior to the beginning of pubertal growth spurt.



## THIRD STAGE OF MATURATION (M = 12.6Y, F= 9.6Y)

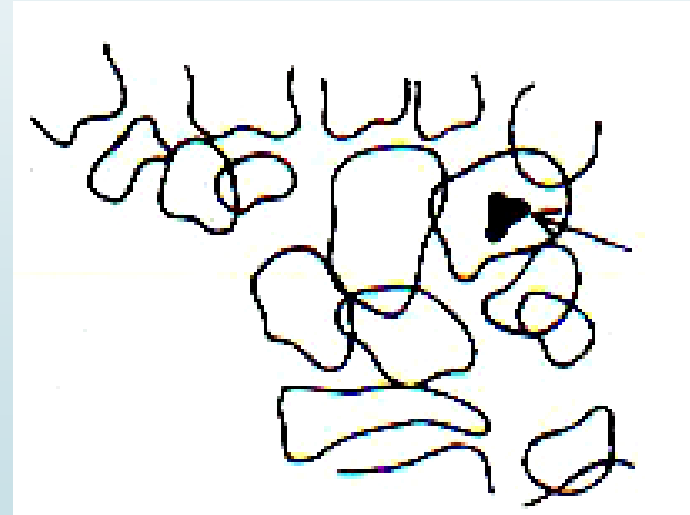
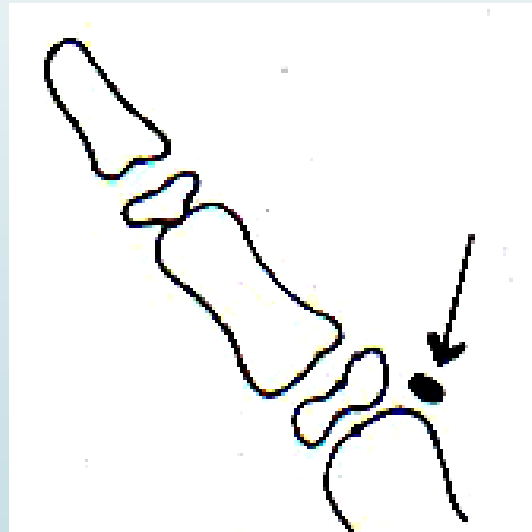
This stage is characterized by presence of 3 areas of **ossification**

- Ossification of pisiform.
- The hamular process of the hamate exhibits ossification.
- The width of epiphysis and diaphysis of radius are equal



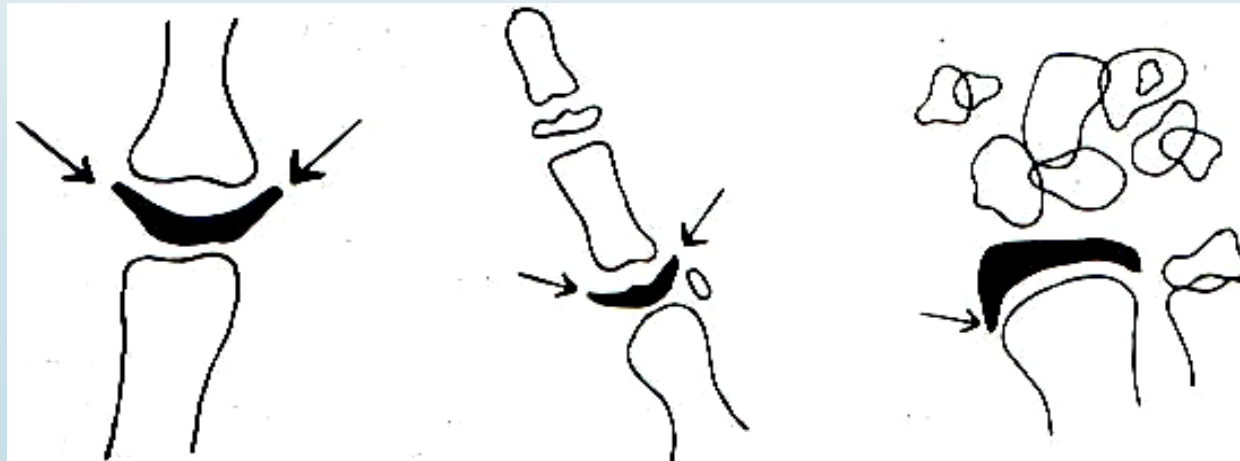
## FOURTH STAGE (M = 13Y, F= 10.6Y)

- ▶ Initial mineralization of the sesamoid bone of the thumb
- ▶ Progressive ossification of the hamular process of the hamate bone.
- ▶ This stage marks the beginning of pubertal growth spurt



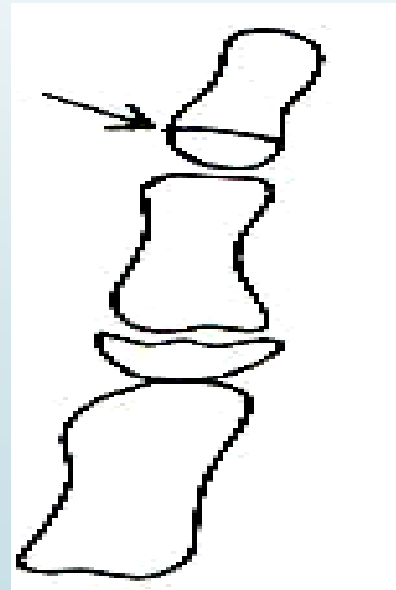
## FIFTH STAGE (M = 14Y, F= 11Y)

- ▶ **Capping of diaphysis by the epiphysis is seen in**
  - a. Middle phalanx of the third finger
  - b. Proximal phalanx of the thumb.
  - c. Radius
- ▶ This stage marks the peak of the pubertal growth spurt.



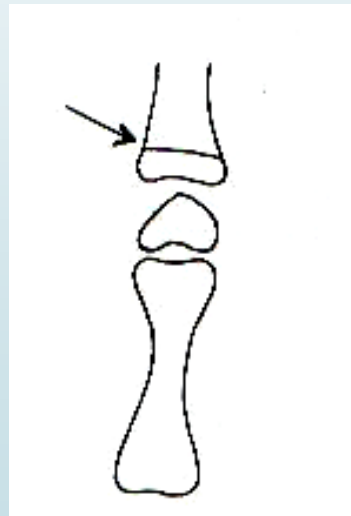
## SIXTH STAGE (M = 15Y, F= 13Y)

- ▶ **Characterized by union of epiphysis and diaphysis** of the distal phalanx of the middle finger.
- ▶ **End of the pubertal growth spurt.**



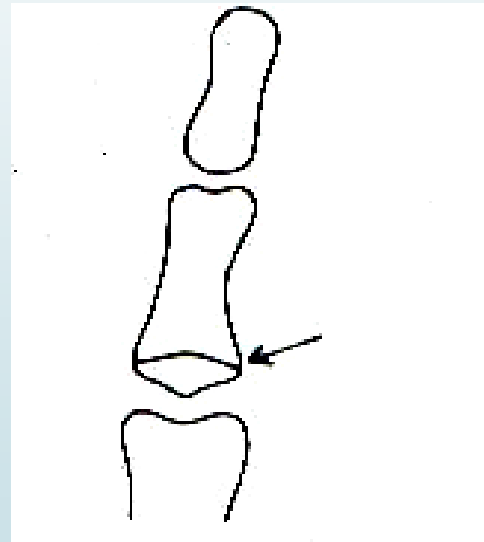
## SEVENTH STAGE (MALES 15.9Y, FEMALES 13.3 Y)

- ▶ **Union of epiphysis and diaphysis** of the proximal phalanx of the little finger.
- ▶ **Seen after a year after the growth spurt.**



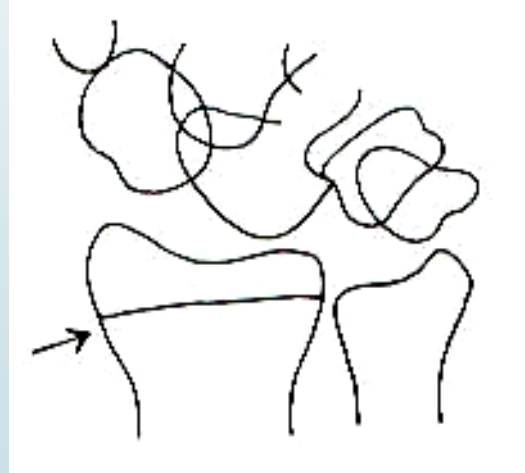## EIGHTH STAGE (MALES 15.9Y, FEMALES 13.9Y)

- **Union between the epiphysis and diaphysis** of middle phalanx of third finger.



## NINTH STAGE (MALES 18.5Y, FEMALES 16.0Y)

- ▶ This is the **last stage** and it signifies the end of skeletal growth. It is characterized by fusion of epiphysis and diaphysis of the radius.



### 3) HAGG AND TARANGER METHOD

- ▶ Hagg and Taranger analyzed yearly hand wrist radiographs of individuals from age 6 to 18 years and studied the ossification of the sesamoid (S), the middle and distal phalanges of the third finger (MP3 and DP3) and the distal epiphysis of the radius.
- ▶ Appearance of ulnar sesamoid is seen during the acceleration of pubertal growth spurt.

## MIDDLE PHALANX OF 3<sup>RD</sup> FINGER

**MP3F** : Epiphysis is as wide as metaphysis.

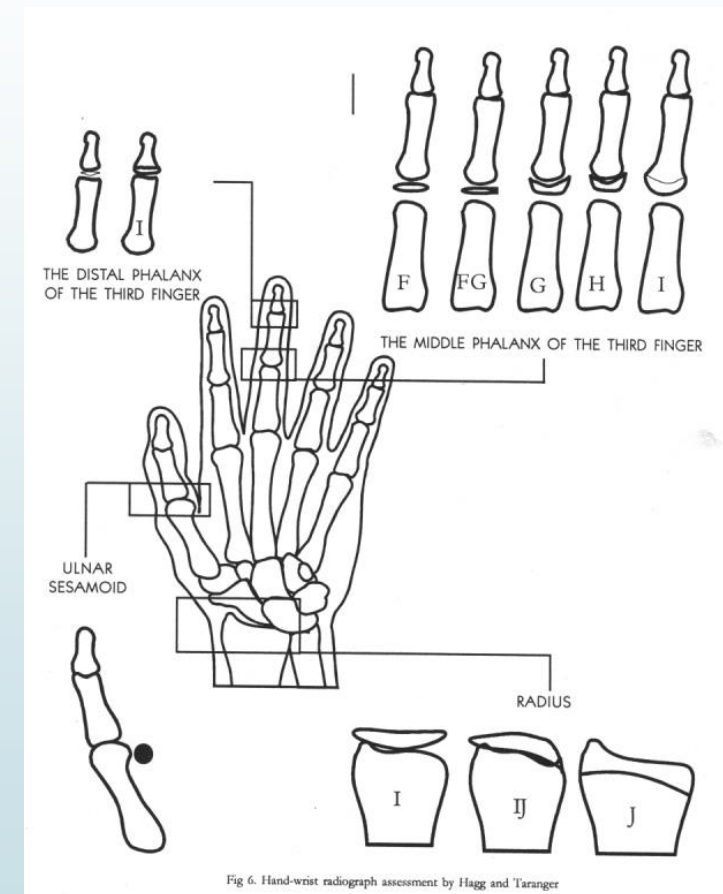
- Attained before onset of PHV by about 40% of the subjects

**MP3 FG** : Epiphysis is as wide as metaphysis.

- Distinct medial or lateral border of the epiphysis forming a line of demarcation at right angles to the distal border.
- 1 yr before or at PHV.

**MP3G** : Sides of epiphysis have thickened and caps its metaphysis, forming an edge distally at one or both sides.

- At or 1 yr after PHV.

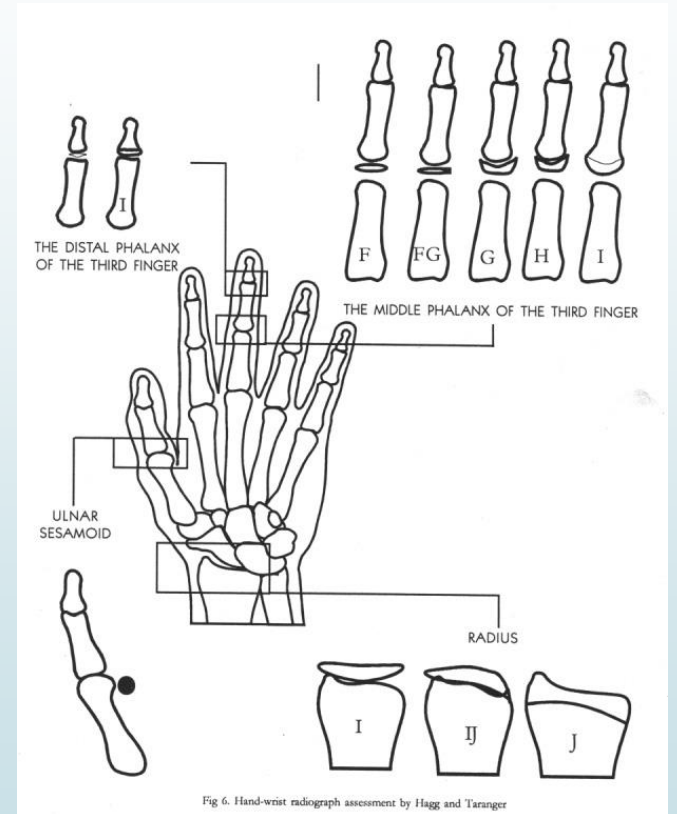


**MP3H** : Fusion of epiphysis and metaphysis has begun

➤ After PHV but before the end of growth spurt.

**MP3I**: Fusion of epiphysis and metaphysis is completed.

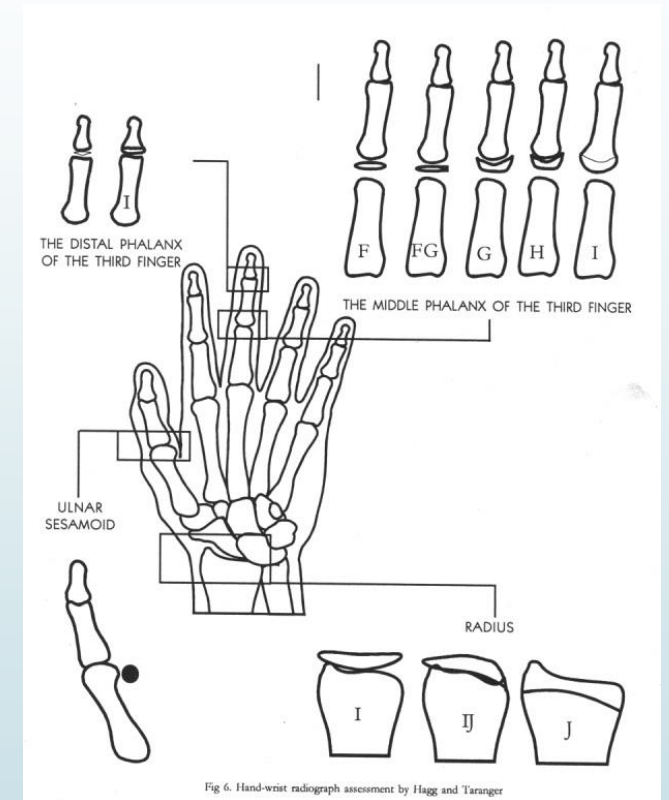
➤ Before or at the end of pubertal growth spurt



# THE DISTAL PHALANX OF 3<sup>RD</sup> FINGER

46

**DP3 I** – Fusion of epiphysis and diaphysis completed.  
It is attained during the deceleration period of the  
pubertal growth spurt



# RADIUS

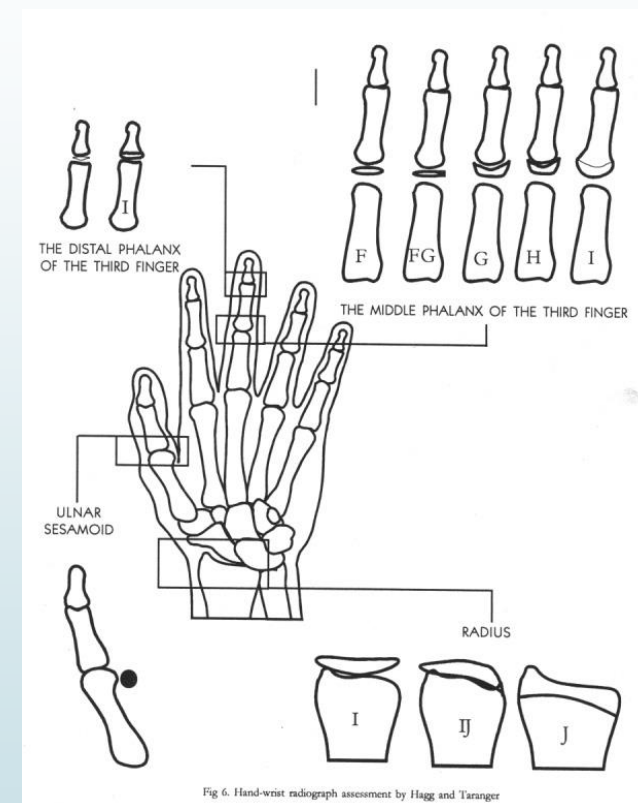
**Stage I**— Fusion of the epiphysis and metaphysis has **begun**.

- 1 year before or at end of growth spurt

**Stage IJ**— Fusion is **almost completed** but there is still a small gap at one or both margins.

**Stage J**— fusion of the epiphysis and metaphysis is **completed**.

- These stages were not attained before end of PHV by any subject.

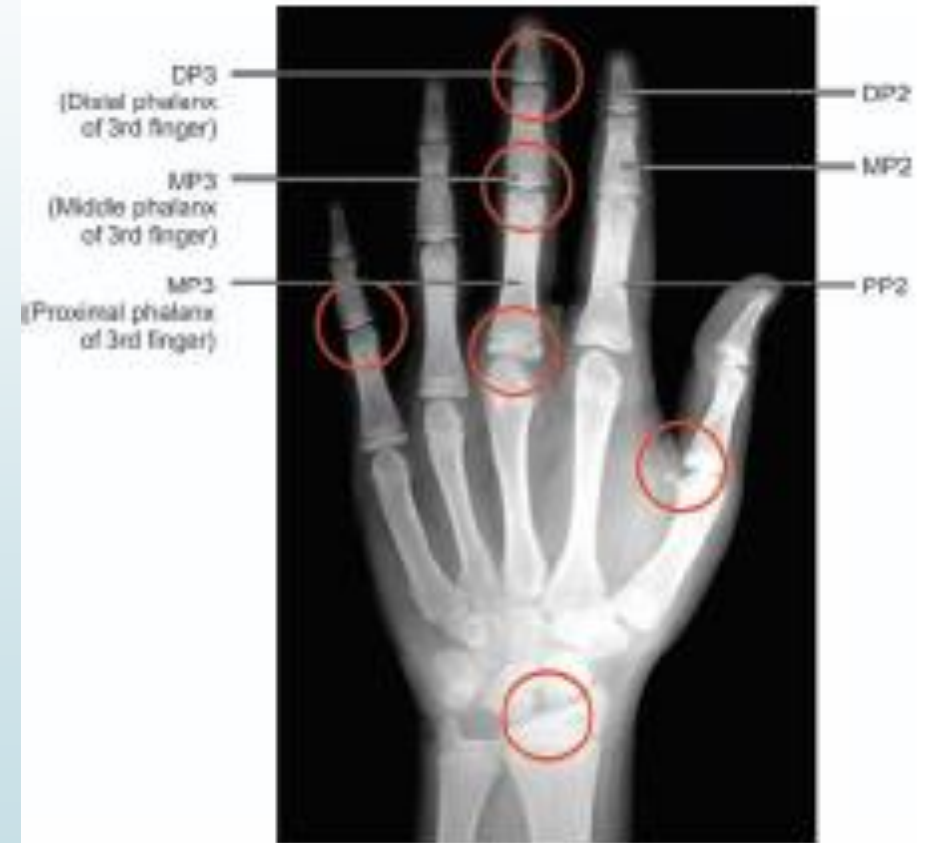
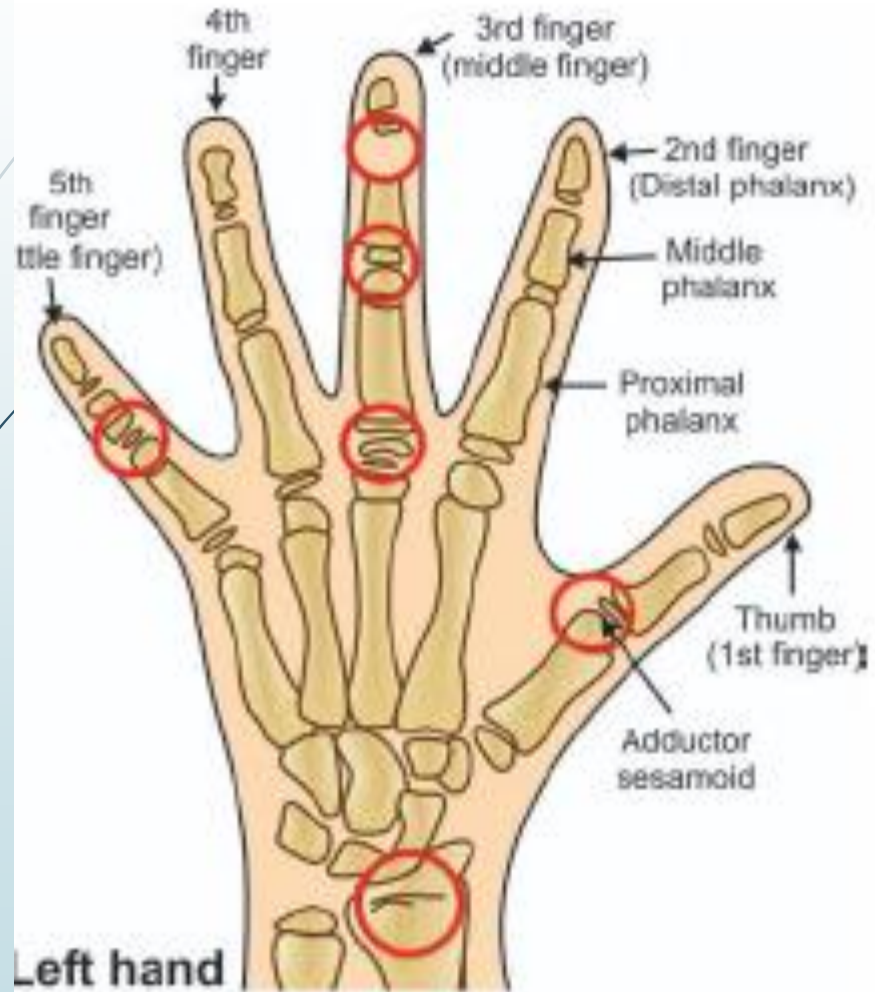

## 4) FISHMAN'S SKELETAL MATURITY INDICATORS

- ▶ Keonord S Fishman proposed a system for evaluation for skeletal maturation in 1982.
- ▶ Fishman made use of four anatomical sites located on the thumb third finger, fifth finger and radius.
- ▶ Eleven discrete adolescent skeletal maturity indicators (SMI's) were proposed which covered the entire period of adolescent development.

## The four ossification stages are:

- ▶ Epiphysis equal in width to diaphysis .
- ▶ Appearance of adductor sesamoid of the thumb
- ▶ Capping of epiphysis
- ▶ Fusion of epiphysis & diaphysis



## The eleven skeletal maturity indicators are as follows:

- ▶ *SMI 1*: The third finger proximal phalanx shows equal width of epiphysis and diaphysis.
- ▶ *SMI 2*: Width of epiphysis equal to that of diaphysis in the middle phalanx of third finger.
- ▶ *SMI 3*: Width of epiphysis equal to that of diaphysis in the middle phalanx of fifth finger.
- ▶ *SMI 4*: Appearance of adductor sesamoid of the thumb.
- ▶ *SMI 5*: Capping of epiphysis seen in distal phalanx of third finger.

- ▶ *SMI 6*: Capping of epiphysis seen in middle phalanx of third finger.
- ▶ *SMI 7*: Capping of epiphysis seen in middle phalanx of fifth finger.
- ▶ *SMI 8*: Fusion of epiphysis and diaphysis in the distal phalanx of third finger.
- ▶ *SMI 9*: Fusion of epiphysis and diaphysis in proximal phalanx of third finger.
- ▶ *SMI 10*: Fusion of epiphysis and diaphysis in the middle phalanx of third finger.
- ▶ *SMI 11*: Fusion of epiphysis and diaphysis seen in the radius.

## 5) SINGERS METHOD OF ASSESSMENT

- ▶ Julian Singer in 1980 proposed a system of hand wrist radiograph assessment which enables the clinicians to rapidly and with some degree of reliability helps to determine the maturational status of patient
- ▶ Singer has described six stage of hand wrist development

### Stage 1 (Early)

- ▶ Absence of pisiform
- ▶ Absence of hook of hamate
- ▶ Proximal phalanx of second finger - Epiphysis narrower than its diaphysis

### Stage 2 (Prepubertal)

- ▶ Initial ossification - hook of hamate
- ▶ Initial ossification - pisiform
- ▶ Proximal phalanx of second finger - Epiphysis = diaphysis
- ▶ Represents period prior to adolescent growth spurt during which significant amount of mandibular growth is possible
- ▶ Class II molar relation can be easily corrected with considerable speed if treatment is carried out during this stage.

### Stage 3 (Pubertal onset)

- ▶ Beginning of calcification of ulnar sesamoid
- ▶ Proximal Phalanx of second finger - Increased width of epiphysis
- ▶ Ossification of hook of hamate
- ▶ Ossification of pisiform
- ▶ Signifies the onset of pubertal growth spurt

### Stage 4 (Pubertal)

- Calcified ulnar sesamoid
- Capping of diaphysis of middle phalanx of third finger by its epiphysis
- Accelerating phase of pubertal growth spurt

### Stage 5 (Pubertal deceleration)

- Fully calcified ulnar sesamoid
- Fusion of epiphysis of distal phalanx of third finger with its shaft
- Epiphysis of radius and ulna not fully fused with respective shafts
- This stage represents period of growth when orthodontic treatment might be completed and the patient is in retention therapy

### Stage 6 (growth completion)

- No remaining growth sites seen. Signifies growth completion.

## 6) CERVICAL VERTEBRAE MATURATION INDEX

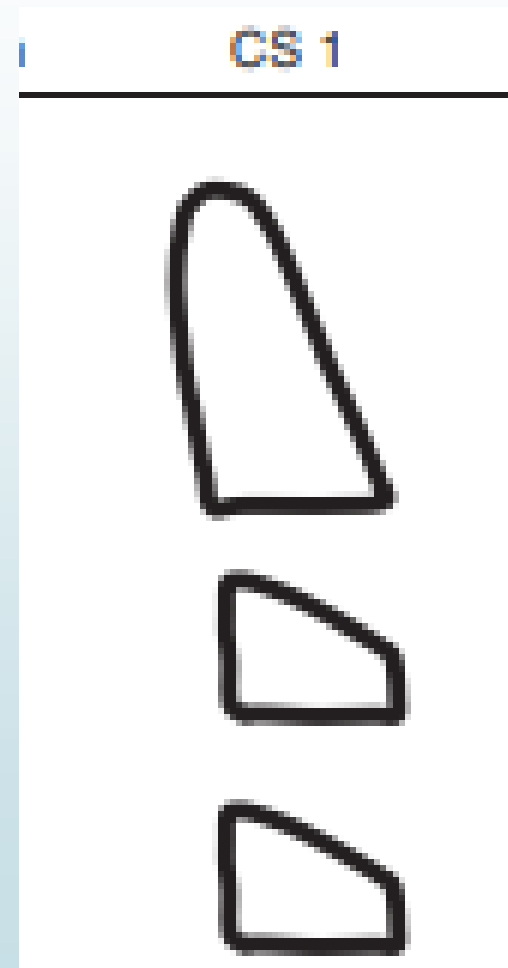
- Hassel and Farman developed a system of skeletal maturation system determination using the cervical vertebrae.
- The shape of the cervical are seen different at each level of skeletal development.
- This provided a means to determine skeletal maturity of an individual.
- The shape of vertebral bodies of C3 and C4 changed from wedge shaped to rectangular followed by square.
- In addition they even became taller as skeletal maturity progressed.
- The inferior borders are flat when immature, and becomes concave on maturing.

- ▶ It is accurate in assessment
- ▶ Evaluation of morphology of 3 vertebrae C2, C3&C4.
  
- ▶ Hassel and Farman had put forward the following six stage in vertebral development.

# STAGES

## Cervical stage 1 - **INITIATION.**

- Inferior borders C2 to C4 are flat
- The vertebrae were wedge shaped.
- Remaining growth – 80 to 100%




## Cervical stage 2 - **ACCELERATION**

- ▶ Growth acceleration begins at this stage.
- ▶ Concavities starts developing on inferior border of C2 and C3
- ▶ Inferior border of C4 remains flat.
- ▶ C3 and C4 nearly rectangular in shape
- ▶ Remaining growth – **65 – 85%**



### Cervical stage 3 -**TRANSITION**

- ▶ It corresponds to growth of peak height velocity
- ▶ Distinct concavities seen on C2 and C3
- ▶ Concavity starts to develop on inferior border of C4
- ▶ C3 and C4 bodies - rectangular shape
- ▶ Remaining growth – **25% to 65%**



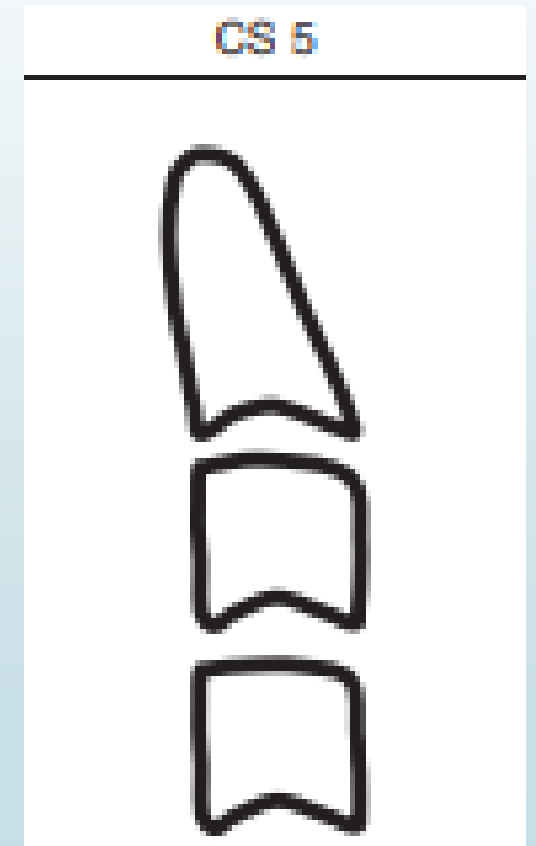
## Cervical stage 4- **Deceleration**

- ▶ It corresponds to deceleration of adolescent growth spurt
- ▶ Distinct concavities seen in lower border of C2, C3 and C4
- ▶ The bodies of C3 and C4 – nearly square in shape.
- ▶ Remaining growth – **10 to 25%**



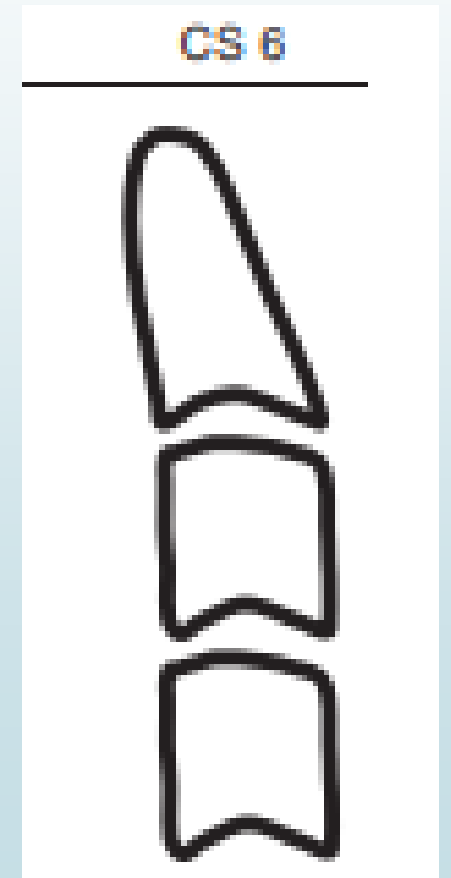
## Cervical stage 5 **MATURATION**

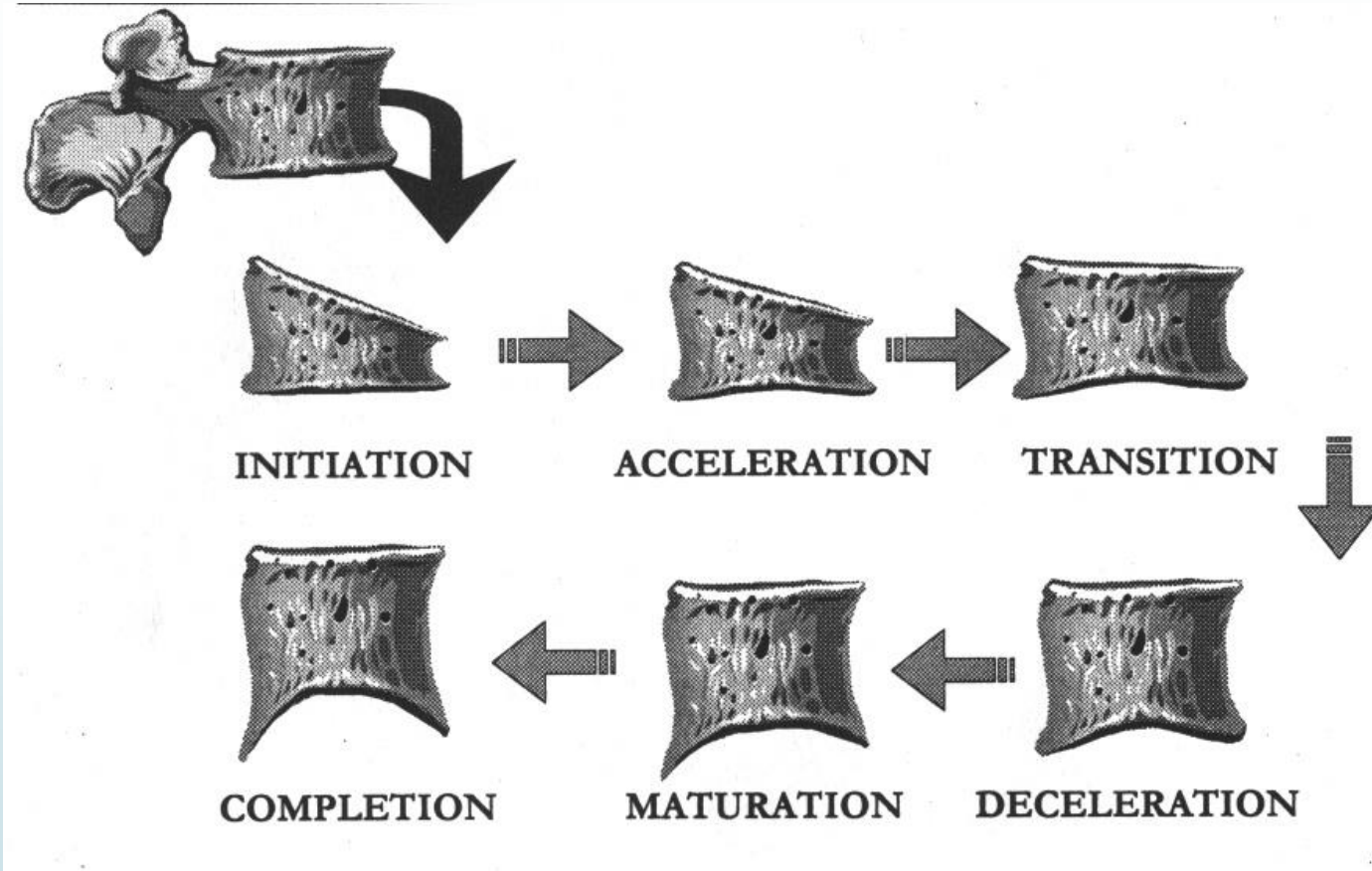
- ▶ C2, C3, and C4 - More accentuated concavities
- ▶ The bodies of C3 and C4 – nearly square in shape.
- ▶ Remaining growth- **5% to 10%**



## Cervical stage 6 **COMPLETION.**

- ▶ Growth was considered to be complete at this stage. Little or no adolescent growth was expected.
- ▶ Deep concavities in inferior borders of C2, C3, and C4.
- ▶ The bodies of C3 and C4 – square in shape





## 7) TOOTH MINERALIZATION AS AN INDICATOR OF SKELETAL MATURITY

Calcification patterns and stages of mineralization of teeth is believed to have a close relation to skeletal maturation

Dental development is assessed by phase tooth eruption or stage of tooth calcification.

**Seymour Chertkow** described a method of determining skeletal maturity based on mineralization of lower canine.

Demirjain , Goldstein and Tanner described similar method.

## Stage A

Calcification of single occlusal point without fusion of different calcifications

## ► Stage B

Fusion of mineralization points. Contour of occlusal surface is recognizable.

## ► Stage C

Enamel formation completed on occlusal surface

Dentin formation commenced

Pulp chamber curved

No pulp horns

## ► Stage D

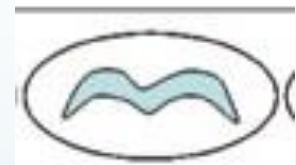
Crown formation completed upto CEJ.

Root formation commenced

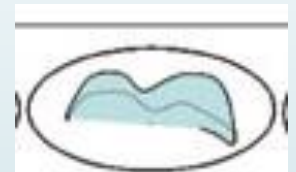
Pulp horns are beginning to differentiate but wall of pulp chamber is curved.



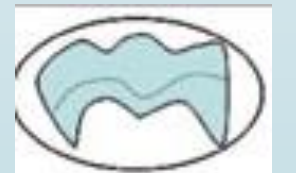
A



B



C



D

**► Stage E**

Root length shorter than crown height

Wall of pulp chamber straight

Pulp horns more differentiated

Molars – radicular bifurcation commenced to calcify.

**► Stage F**

Wall of pulp chamber isosceles triangle

Root length  $\geq$  crown height

Molars – bifurcation developed to give the roots more distinct form

**► Stage G**

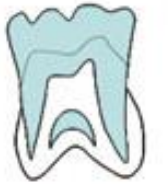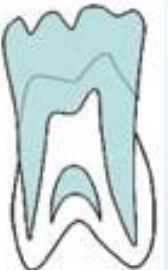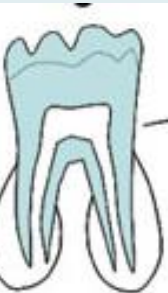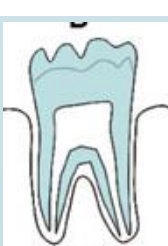Wall of root canal – parallel

apical end partially open

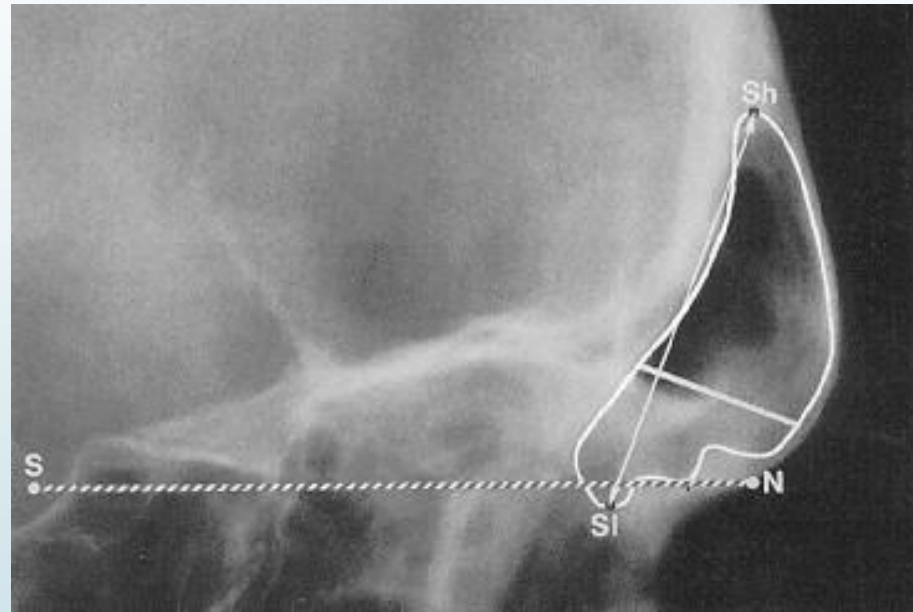
**► Stage H**

Root apex completely closed.

PDL membrane is uniform in width throughout.

**E****F****G****H**

## 8) FRONTAL SINUS DEVELOPMENT



**Frontal sinus development as an indicator for somatic maturity at puberty?  
Am J Orthod Dentofac Orthop 1996; 110:476-82.**

Frontal sinus growth velocity at puberty is closely related to **body height growth velocity**.

- Frontal sinus growth shows a **well-defined pubertal peak** (Sp), which on the average, occurs 1.4 years after the pubertal body height peak (Bp).
- In male subjects, the average age at frontal sinus peak is **15.1 years** and in female subjects around **13.9 years**.
- In a one-year observation interval, a peak growth velocity in the frontal sinus of at least 1.3 mm/yr. is attained by 84% of the subjects .

*Rossouw, Lombard, and Harris: Frontal sinus and mandibular growth prediction.  
Am J Orthod 1991: vol: 542-546*

## 9) MIDPALATAL SUTURE OSSIFICATION

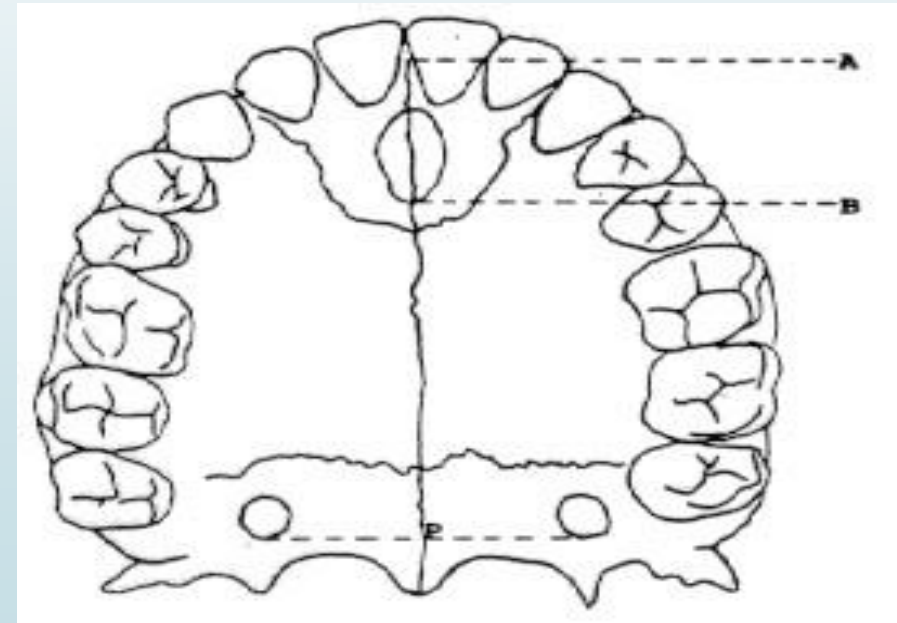
Stages of ossification of the midpalatal suture were compared with Fishman's standards of skeletal maturation indicators (SMI stages 1 to 11), allowing for comparison of the differences of maturational development between delayed, average, and accelerated maturation.

**Maturational evaluation of ossification of the midpalatal suture**

**Bernal Revelo, DDS, Leonard S. Fishman, DDS**

**Am J Orthod Dentofac Orthop March 1994, Volume 105, Issue 3, Pages 288–29**

- ▶ The following key landmarks and planes were identified:
  - Point A, most anterior point of the premaxilla
  - Point B, most posterior point on the posterior wall of the incisive foramen
  - Point P, point tangent to a line connecting the posterior walls of the greater palatine foramina.
- ▶ Measurements of length and associated percentage of osseous development were recorded for the following dimensions:
  - A-B (anterior dimension of the suture)
  - B-P (posterior dimension of the suture).
  - A-P (total dimension of the suture)



- ▶ Both the male and female subjects demonstrated an **increase in the amount of sutural approximation** (fusion) as the SMI stages progressed through adolescence.
- ▶ Very little midpalatal approximation existed during **the early maturational stages, SMI 1 to 2.**
- ▶ **Very large increases** in approximation are evident during the **late maturation period, from SMI 8 to 11.**
- ▶ There is **no significant difference** between the amount of midpalatal sutural approximation between the male and female groups, although the male values were slightly higher in numerical value.

# CONCLUSION

1963 Bjork study showed

1. There was a **discernible**, but not necessarily significant, spurt in condylar growth in less than 25% of the sample.
2. The **magnitude, duration, and timing** of the spurt varied widely even in this selected subsample of 11 subjects.
3. There was no relationship between the **intensity of the growth and its direction**.

- ▶ In 1990 Moore, Moyer, and DuBois assessed that growth spurts could not be observed on an **individual basis** and the correlations between adolescent growth acceleration and deceleration in the **facial dimensions**, with both standing height and skeletal maturity as determined from wrist x-rays, were not clinically significant for prediction.

## REFERENCES

- ▶ Text book of Orthodontics – Gurkeerat Singh Second Edition
- ▶ Textbook of Contemporary Orthodontics – William Profitt
- ▶ Textbook Orthodontics- Bhalajhi Sixth Edition
- ▶ Chertlow: Tooth mineralization as an indicator of the pubertal growth spurt. Am J Orthod 1980; vol: 79-91
- ▶ Demirjian, Buschang, Tanguay, and Patters: Interrelationships among measures of somatic, skeletal, dental, and sexual maturity
- ▶ Grave and Brown: Skeletal ossification and adolescent growth spurt. Am J Orthod 1976; vol: 69-80
- ▶ Hagg and Taranger: Maturation indicators and the pubertal growth spurt. Am J Orthod 1982; vol: 299-309
- ▶ Hassel and Farman: Skeletal maturation evaluation. Am J Orthjod 1995; vol: 58-66
- ▶ Julian Singer: Physiologic timing of orthodontic treatment. Am J Orthod 1980; vol: 322-333

- ▶ Leite, O'Reilly, and Close: Skeletal age assessment with first, second, and third finger. *Am J Orthod* 1987; vol: 492-498
- ▶ Leonard Fishman: Radiographic evaluation of skeletal maturity. *Angle Orthodont* 1982; vol: 88-112
- ▶ Moore, Moyer and DuBois: Skeletal maturation and craniofacial growth. *Am J Orthod* 1990; vol: 33-34
- ▶ Revelo and Fishman: *Maturational evaluation of ossification of the midpalatal suture, Am J Orthod* 1994, p288–29
- ▶ Rossouw, Lombard, and Harris: *Frontal sinus and mandibular growth prediction. Am J Orthod* 1991: vol: 542-546
- ▶ *Frontal sinus development as an indicator for somatic maturity at puberty Am J Orthod Dentofac Orthop* 1996; 110:476-82.

