

# MANAGEMENT OF OPEN-BITE IN ORTHODONTICS

*Dr. Harsh Modi*

# Overview

- **Introduction**
- **Classification**
- **Etiology**
- **Diagnosis**
- **Management**
  - **Orthodontic**
  - **Surgical**
- **Retention and Relapse**
- **Conclusion**

# Introduction

- Definition: Open bite is the failure of a tooth or teeth to meet their antagonist in the opposite arch.
- Open bite is a condition of malocclusion wherein there is an overlap between the maxillary and mandibular dentition.

# Problems Posed by Open Bite

- Open bite creates significant problems such as
  - **Difficulty in speech (dysphonia)**
  - **TMJ disorders**
  - **Functional imbalance**
  - **Bad aesthetics**
  - **Alteration of incisor guidance**
  - **Reduction of normal functional activity**

# Features of Open Bite

- Increase in the lower facial height
- Clockwise rotation of the mandible
- Extrusion of molars

# Classification

- Open bite is classified :
  - On the basis of region involved as
    - Anterior Open Bite
    - Posterior Open Bite
  - On the basis of etiological factors as
    - Skeletal Open Bite
    - Dental Open Bite
  - On the basis of Molar Relationship as
    - Class I Open Bite
    - Class II
    - Class III

# Classification (Cont)

- On the basis of clinical evaluation as
  - Simple (occurs between the incisors)
  - Complex (extends from premolars or deciduous molars from one side to the other)
  - Compound/Infantile open bite (completely open including the molars)
  - Iatrogenic Open Bite (consequence of orthodontic or surgical therapy)

# Etiology

- Can be classified in to
  - Epigenetic
  - Environmental
- OR
  - Disturbances in the eruption of teeth or alveolar growth (ankylosed teeth)
  - Mechanical interference with eruption and alveolar growth (thumb or digit sucking)
  - Vertical skeletal dysplasias

# Epigenetic factors

- Posture, morphology and size of the tongue
- Skeletal growth patterns of the maxilla and the mandible
- The vertical relationship of the jaw bases

# Environmental Factors

- Abnormal function
  - Thumb or digit sucking habit
  - Tongue thrusting habit
- Improper respiration
  - Mouth breathing

# Environmental Factors

- Thumb or digit sucking habit
  - This is one of the most common habits seen in children.
  - The habit is quite reversible till the age of 3 or 4
  - Beyond this age, this habit becomes the cause of many malocclusions.
  - Causes of the habit
    - Sigmund Freud- emotional security derived from the oral phase of psychological development of first 3 years of life

# Environmental Factors

- Tongue thrust habit
  - Infantile / visceral swallowing is the physiological basis for the neonate/infant to create a proper lip seal during suckling. When the deciduous teeth erupt, the pattern of swallowing changes to adult/mature swallow. If the visceral swallow persists after the 4th year of life, the habit is called retained infantile swallow or tongue thrust.

# Environmental Factors

- Sean and Wise (1950) stated that digit sucking led to thumb sucking
- Benjamin's theory- the basis of thumb sucking is found in the physiological rooting reflex of infancy where the infant reflexively sucks the nipple of the breast, a teat of a feeding bottle, or a finger.
- Psychological lability- thumb sucking is a sign of lack of parental love or fundamental psychological insecurity.
- Learned behaviour: children learn the habit from siblings or toddler friends.

# Environmental Factors

- Etiology of tongue thrust
  - Genetic factors
  - Learned behaviour
  - Maturational factors
  - Mechanical restrictions
    - Macroglossia
    - Constrictive dental abscess
    - Adenoid hypertrophy
    - Neurological disturbances
      - hyposensitive palate
      - Moderate motor disability
  - Psychogenic factors

# Environmental Factors

- Classification of tongue thrust activity (Bohr & Holt):
  - Tongue thrust without deformation
  - Tongue thrust causing anterior deformation
    - Anterior / Simple Open Bite
  - Tongue thrust causing buccal segment deformation with a posterior open bite (lateral tongue thrust)
  - Combine tongue thrust causing both anterior and posterior open bite (complex open bite)

# Environmental Factors

- Mouth breathing habit
  - The mode of respiration influences the posture of the jaws, the tongue and to a lesser extent, the head. Hence mouth breathing can result in altered jaw and tongue posture thereby altering the oro-facial equilibrium leading to malocclusion.

# Environmental Factors

- Classification of mouth breathers
  - Obstructive
    - Complete or partial obstruction of the nasal passage
  - Habitual
    - Unconsciously performed act whereby breathing occurs despite removal of obstruction
  - Anatomic
    - Lip morphology does not permit complete closure of the mouth

# Environmental Factors

- Clinical features of mouth breathers
  - Long and narrow face
  - Narrow nose and nasal passage
  - Short and flaccid upper lip
  - Contracted maxillary arch
  - Flaring of incisors
  - Anterior marginal gingivitis

# Diagnosis

- Clinical
  - Pseudo-open bite (overjet and overbite < 1mm)
  - Simple open bite (open bite >1mm)
  - Complex open bite (open bite extending from deciduous molars on one side together)
  - Compound or infantile open bite (completely open including molars)
  - Iatrogenic open bite (consequence of orthodontic or surgical treatment)

# Diagnosis

- Cephalometric
  - Dento-alveolar open bite ( depends on the extent of eruption of the teeth)
    - Vertical growth pattern
      - protrusion of upper anterior, lingual inclination of lower incisors
    - Horizontal growth pattern
      - upward and forward tipping of the maxillary base

# Diagnosis

- Skeletal open bite
  - Excessive anterior facial height but decreased posterior facial height
    - Mandibular base
      - » Usually normal
      - » Antegonial arching
      - » Ramus is short
      - » Increased bony angle
      - » Growth pattern is vertical

# Diagnosis

## – Maxillary base

- » **Upward tipping of the forward end of the maxillary base**
  - » **Downward tipping of the posterior end of the maxillary base**
  - » **Increased total anterior facial height with no difference in the cranial base**
- In skeletal open bite the anterior teeth are either normally erupted or over erupted
  - In dento-alveolar open bite the anterior teeth are under erupted due to certain interferences (certain habits)

# Management

Management is based on etiology and localization of malocclusion

- Management in dento-alveolar open bite
  - Habit control and elimination of abnormal perioral muscle function
- Management in skeletal open bite
  - During active growth phase
    - Redirection of growth
  - After active growth phase
    - Extraction and orthodontics or orthognathic surgery

# Management

- Management in combined dento-alveolar and skeletal open bite
  - Combined therapeutic approach is needed to achieve optimum results

# Management

- The timing of treatment and determination of growth pattern are crucial. Based on type of dentition, the management can be divided into
  - Management in deciduous dentition
  - Management in mixed dentition
  - Management in permanent dentition

# Management

- Management in deciduous dentition
  - Dento-alveolar
    - Tongue crib, oral screen, reminder appliance, activator, etc.
    - Open bite is usually corrected as soon as the habit is broken
  - Skeletal
    - Phase I
      - Extra-oral orthopaedic appliances (chin cap)
    - Phase II
      - Habit control

# Management

- Management of mixed dentition
  - Dento-alveolar
    - Early mixed dentition
      - Screening appliances and habit breaking appliances
    - Late mixed dentition
      - Multi-attachment fixed appliances
      - Extended retention phase
      - Swallowing exercises
  - Skeletal
    - Management depends on severity of malocclusion and possibility of a DA compensation

## – Skeletal (cont.)

- The inclination of the maxillary base plays a vital role in the management. If the jaw bases are divergent, the prognosis is poor.
- If the maxillary base is tipped downward and forward, functional appliance therapy may be successful.
- If the jaw bases are divergent, fixed appliance therapy is indicated
- In severe cases, orthognathic surgery with impaction of buccal segments is performed.
- If the lip sealing ability is disturbed, surgical resection of the mentalis muscle is performed to reduce the ‘golf ball’ chin effect.
- Schili insists on surgery after eruption of lower canines to enhance stability

# Management

- Combined dento-alveolar and skeletal
  - Elimination of abnormal perioral function
    - Screening and habit breaking appliances, serial extraction, activators, etc.
  - Improvement of the skeletal relationship
    - Fixed appliances or orthognathic surgery (severe)

# Management

- Management in permanent dentition
  - Multi-attachment, fixed mechano-therapy
  - Screening appliances
  - Screening appliances with active extrusive force on incisors (tongue crib with active labial bow)
  - Repelling and attracting magnets
  - Functional appliances can be used in the retention phase to prevent over eruption in the posterior segments

# Management Of Open Bite

- Management of open bite can be majorly classified as:
  - **Orthodontic correction**
  - **Surgical correction**
  - **Combination of orthodontic and surgical correction**

# Orthodontic Correction

- Habit breaking appliances
  - Tongue crib
  - Reminder appliance
  - Vestibular screen
  - Others
- Myofunctional appliances
  - Activator
  - Bionator
  - FR-IV
  - Twin Block
  - Jasper jumper

# Orthodontic Correction

- Multiloop edge wise arch wire technique
- Tip edge technique
- Headgears
- Elastics
- Magnets
- Implants
- Posterior bite blocks
- TCA
- SAS
- Thera Spoon

# Surgical Correction

- **Anterior maxillary and mandibular subapical osteotomy**
- **Kole's modification of subapical osteotomy**
- **Sagittal split ramus osteotomy**
- **LeFort I osteotomy**
- **Adjunctive surgical procedures**
  - **The V excision**
  - **The Keyhole procedure**
  - **Deep Lingual Frenectomy**
- **Genioplasty**
- **TMJ considerations**

# Orthodontic Correction

- Habit breaking appliances
  - Tongue crib
    - Anterior open bite
      - A palatal acrylic plate with a horseshoe shaped wire crib and labial bow
      - Crib placed 3 to 4 mm lingual to upper incisors or at gingival 1/3.
    - Posterior open bite
      - The crib is placed 2-3 mm away from the teeth
      - Fixed tongue cribs are also used.
  - Reminder appliances
    - An acrylic plate in which a bead or a wire mesh is embedded
    - Reminds the patient not to go back to the habit

# Orthodontic Correction

- Vestibular screen
  - An acrylic shield extending vertically from the upper labial fold to the lower labial fold and horizontally from the distal margin of the last erupted molar on one side to that on the other
  - Edge to edge bite registered
  - Achieves proper lip seal, thereby creating a somatic swallow pattern
  - Worn at night and 2 to 3 hours during daytime
  - Lip exercises along with the appliance
    - Modifications
      - Vestibular screen with breathing holes
      - Vestibular screen with tongue crib

# Orthodontic Correction

- Other methods
  - Psychological approach
    - Parent counselling
    - Patient counselling and motivation
    - Dunlop's Beta hypothesis
  - Chemical approach
    - Bitter tasting or foul smelling preparation placed on the thumb or digit

# Orthodontic Correction

- **Myofunctional appliances**
  - **Activator**
    - Used to correct anterior open bite.
    - Increases salivary secretion, swallowing activity, muscle contraction and amount of intermittent forced applied to the tooth..
    - Forward positioning of the mandible not necessary
    - Open bite correct by selective trimming
    - Intrusion of molars achieved by loading the cusps
    - Extrusion of incisors achieved by loading the lingual surfaces above the area of greatest concavity and also with the labial bow above the area of greatest convexity.

# Activator

- A modification, the Elastic Activator similar to Stockfish's kinetor was used in the treatment of anterior open bite by A. Stellzig et.al in 1999.
  - The intermaxillary acrylic of the lateral occlusive zones is replaced by elastic rubber tubes
  - Intrusion of both upper and lower posterior teeth by orthopaedic gymnastics

# The Bionator

- The open bite bionator inhibits abnormal posture and function of the tongue.
- Construction bite is as low as possible
- The palatal part moves the tongue into a more posterior position
- The labial bow run between the incisal edges of the upper and lower incisors at the height of correct lip closure to achieve a competent lip seal
- Reduced bulk and full time wear are the advantages
- The labial bow's lateral extensions have a screening effect.

# FR-IV

- The FR –IV is used in the treatment of skeletal open bite and maxillary protrusion
- It has two buccal shields, two lower lip guards, an upper labial wire, and four occlusal rests.
- The occlusal rests prevent eruption of the posterior teeth.
- Lip-seal exercises should be advocated along with FR-IV.

## Modifications:

- FR-IV with chin cap.
- FR-IV with a tongue crib.

# Twin Block

- Consists of simple upper and lower bite blocks that engage on occlusal incline planes and modify them effectively
- Contact between occlusal bite blocks and posterior teeth should be maintained to prevent eruption of the posterior teeth
- Modifications
  - Headgear tubes can be attached and high pull traction can be applied to a modified face bow (concorde) for intrusion of molars
  - Vertical elastics (Mills)
  - Repelling rare earth magnets
  - Palatal spinner can be added to the upper appliance

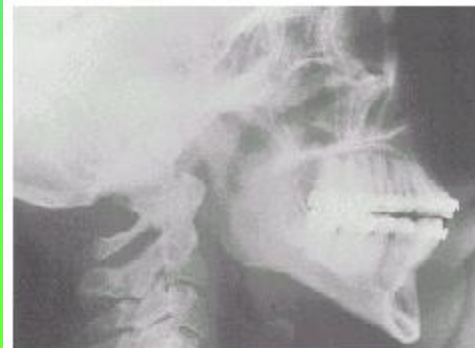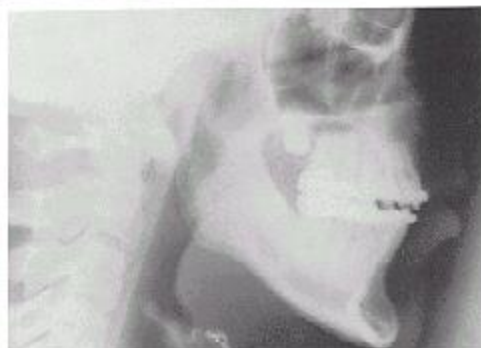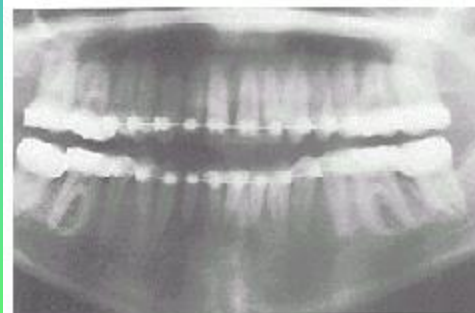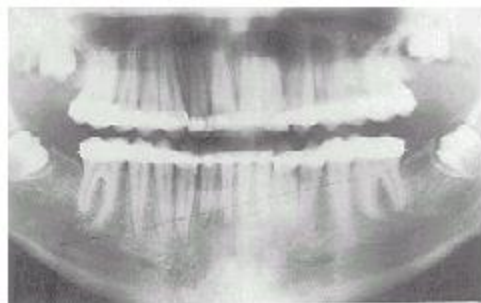
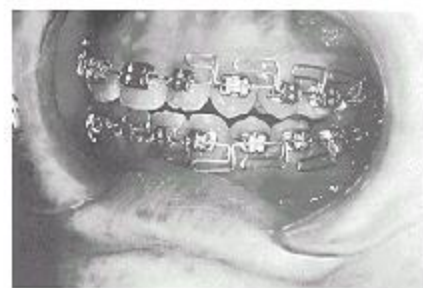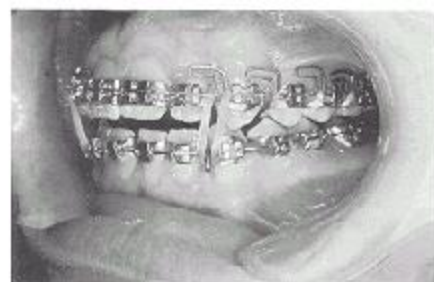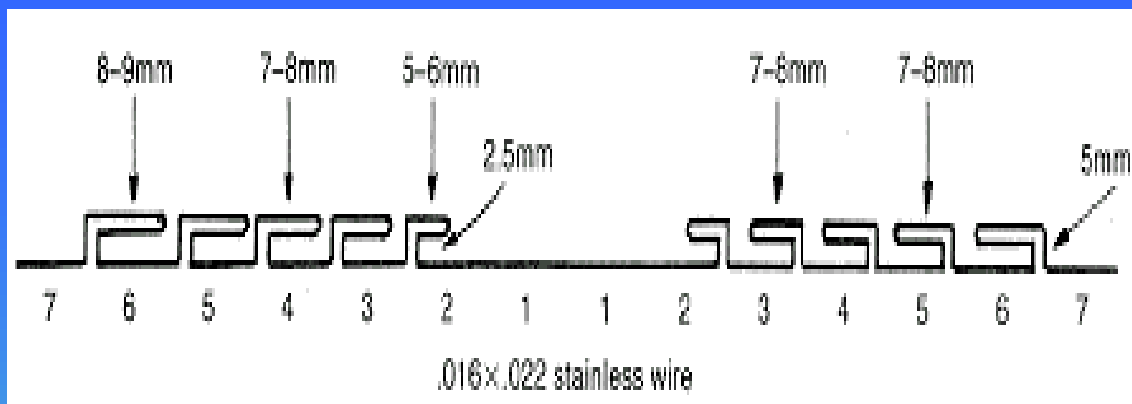
# Jasper jumper

- Robert G. Cash in 1987 used Jasper jumper to treat open bite
- The Jasper jumper was used to distalize and intrude maxillary molars

# The Multiloop Edgewise Archwire Technique (MEAW)

- Young H. Kim in 1987 used the MEAW technique to correct anterior open bite
- This is one of the most effective treatment modalities for anterior open bite malocclusions
- The MEAW technique lowers the load deflection rate and allows the tooth to move independently

- It uses double edgewise brackets with 0.018 inch slots with an auxiliary vertical slot
- Archwire used is 0.016 x 0.022 inch rectangular SS wire and there are five loops on either side
- Vertical loop components are centered at interproximal areas and the horizontal loop components are directed mesially.
- Wire used is 2 ½ times more than normal and hence a tenfold reduction in the load deflection rate.
- The curve and reverse curve of Spee in both archwires worsen the open bite and this is counteracted by using anterior vertical elastics full time
- The completed archwire is treated to about 900 deg F. to increase resiliency and stiffness
- Extraction of second and third molars offers a feasible therapeutic situation by eliminating the dynamic blocking effect and also cortical bone



# Modifications Of MEAW

- Haruo Takayama et al, in 1990 used double key-hole archwire loops in the posterior region in open-bite with Turner's syndrome.
- Ahyanenacar et al, in 1996 used 0.016 x 0.022 Niti wires instead of SS wires along with heavy inter maxillary elastics in the canine region.

# The Tip-edge Technique

- Kesling in 1986 designed the Tip-edge brackets which are dynamic and upright teeth easily and automatically with or without intermaxillary elastics.
- No loops are required for uprighting.
- Anteriorly placed class III elastics with Tip-edge brackets were used to correct anterior open-bite.
- Kim's philosophy + Tip-edge brackets produced stable results in a very short period of time.

# Headgears

Headgears have been used to correct open-bite by molar intrusion.

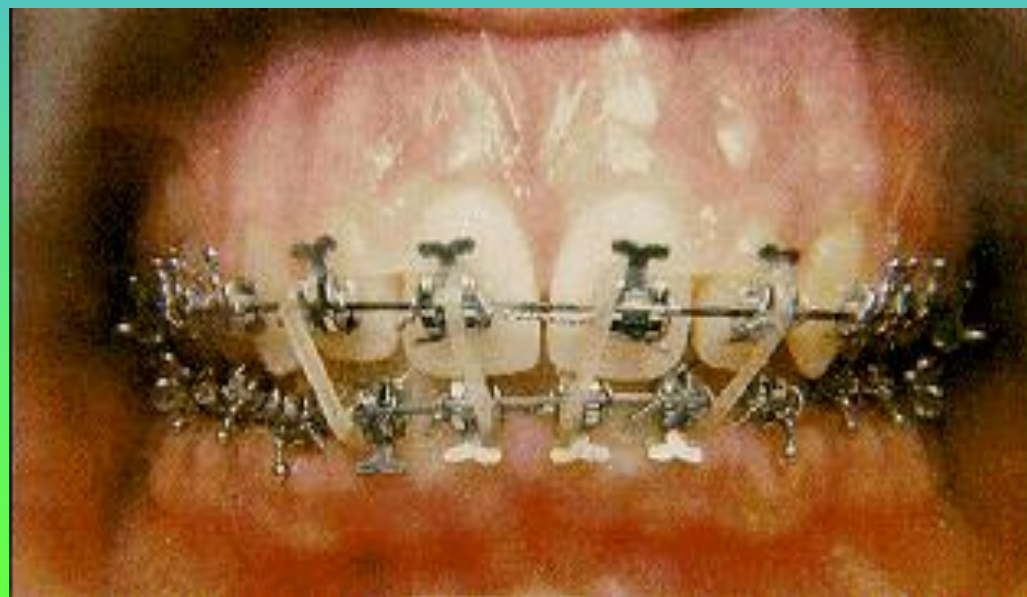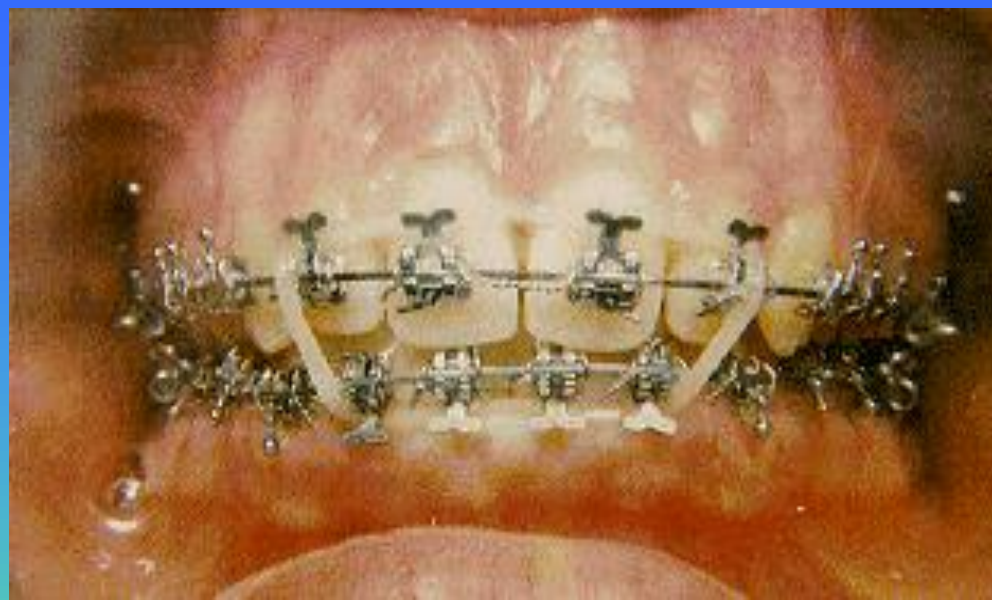
- Galletto in 1990, used posterior bite blocks in conjunction with high-pull headgear and archwire mechanics to correct adult anterior open-bite.
- Roberto Martina et al in 1990, used a cervical pull J-hook type headgear attached at the anterior part of the archwire.
- Allison et al in 1994, used a cervical pull headgear and a lower utility archwire in growing patients.

# Headgears & Elastics

- David Gehring et al in 1998, used a high pull headgear with vertical elastics to treat class II div.1 cases with anterior open-bite.
- Roy Sabri in 1998, used used a high pull headgear with class II & vertical elastics, to treat class II div.1 cases with anterior open-bite.
- Smith& Alexander in 1999, used a cervical pull headgear, Cl.II & Ant. Box elastics, and gingivally placed brackets to correct Cl.II div.1 sub-division right open-bite.

# Elastics

- Viazis in 1991, used a combination of upper SS wire, lower rect. Niti wire & vertical elastics to correct both ant. & post. Open-bites.
- Rinchuse in 1994, used two vertical elastics, one on either side of the mid-line, extending from a Kobiyashi hook on the lower centrals to the upper centrals and then to the lower laterals to correct ant. Open-bite.



# Magnets

Since the introduction of rare earth magnets such as Samarium Cobalt by Becker in 1970, their use in the field of Orthodontics has become increasingly popular.

- Eugene Dellinger in 1986 was the first to use them to correct anterior open-bite in his Active Vertical Corrector. The AVC consists of upper & lower bite blocks with Samarium Cobalt magnets in stainless steel cases embedded in them. The method of action is reciprocal intrusion of the maxillary & mandibular posterior teeth leading to the autorotation of the mandible, closure of the open-bite & reduction of lower anterior facial height.

# Magnets

- Kalra & Burstone in 1989 introduced a fixed magnetic appliance which consisted of upper & lower acrylic splints with Samarium Cobalt magnets in SS cases in the repelling mode, in open-bite cases.
- Killiardis used magnets in bite-blocks in the correction of open-bite.
- Noar, Shell & Hunt used Neodymium-Iron-Boron magnets with an acrylic coating in treating ant. Open-bite.

# Magnets

- Ali Darendeliler in 1995 used the MAD IV (Magnetic Activator Device IV ) to correct anterior open-bite.

The MAD IV consists of anterior attracting & posterior repelling magnets. It consists of removable upper & lower acrylic plates, each containing 3 cylindrical Neodymium magnets coated with stainless steel. The attracting force of the anterior magnets is 300gm & the repelling force of the posterior magnets is also 300gm.


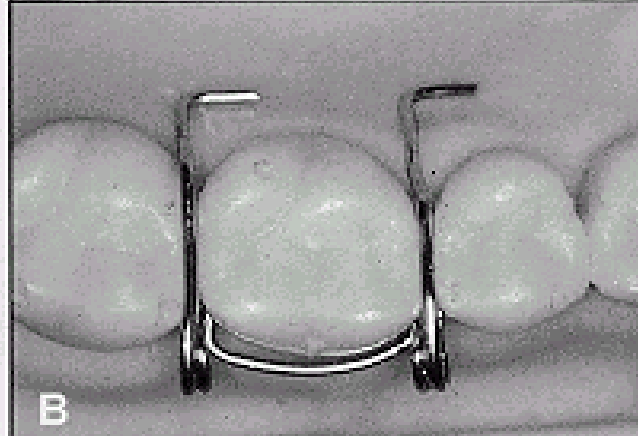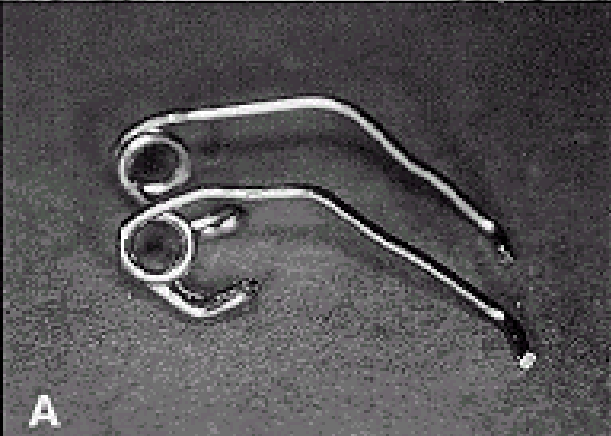
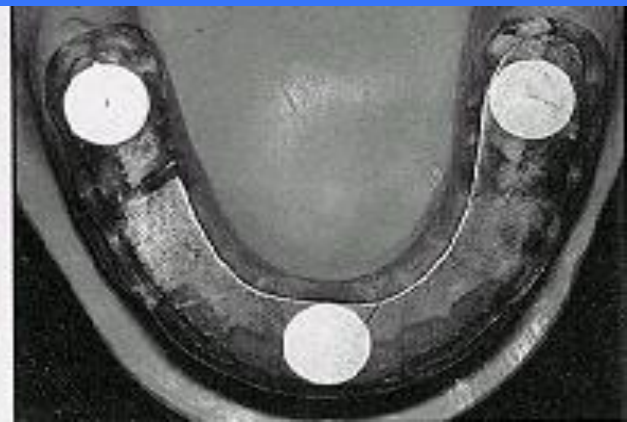
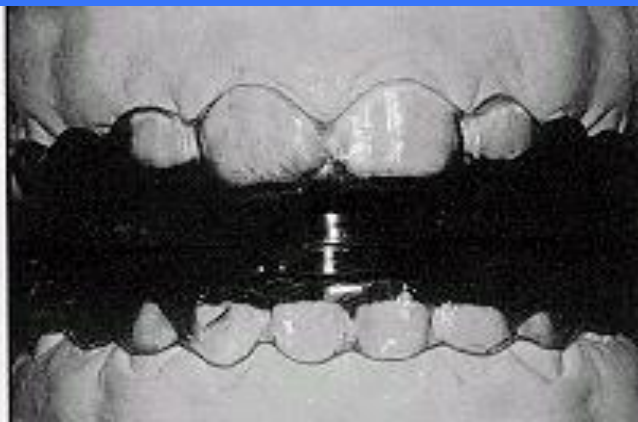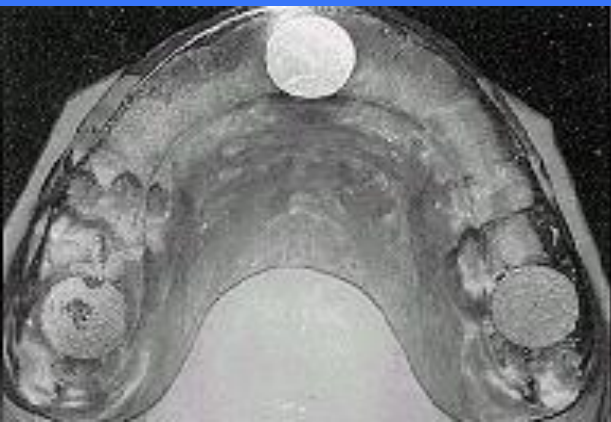# Magnets

In the mixed & permanent dentition, the plates are retained mechanically but, in the late mixed dentition, mod. Adams clasps & Torquing springs give added retention.

MAD IV a: used in cases where the max. ant. Segment is vertically overdeveloped.

MAD IV b: used when an additional extrusive effect is required in the max. ant. region.

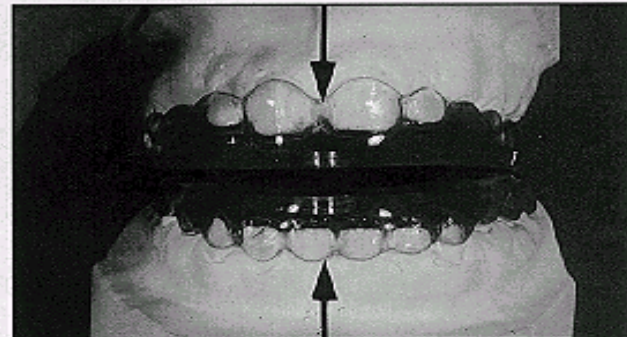
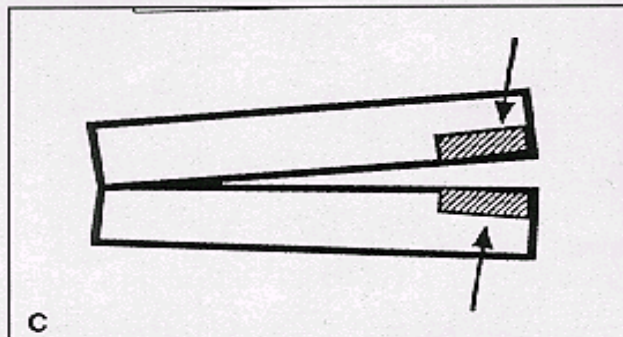
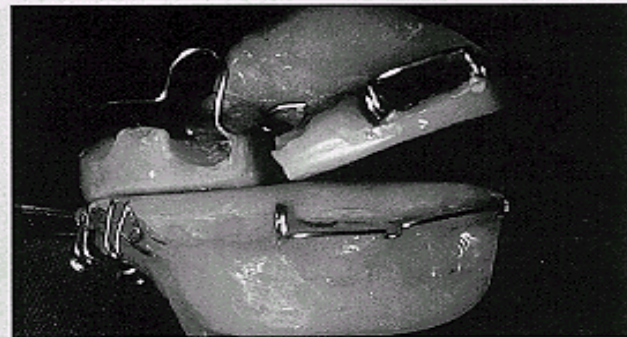
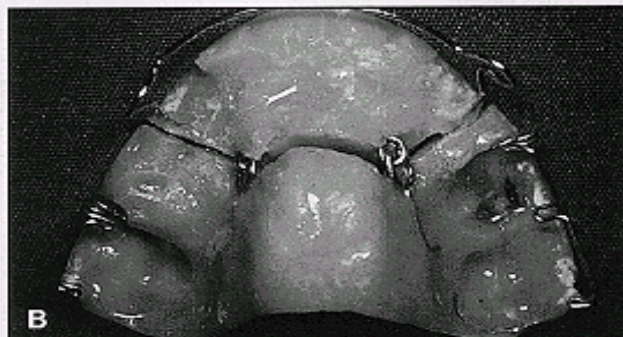
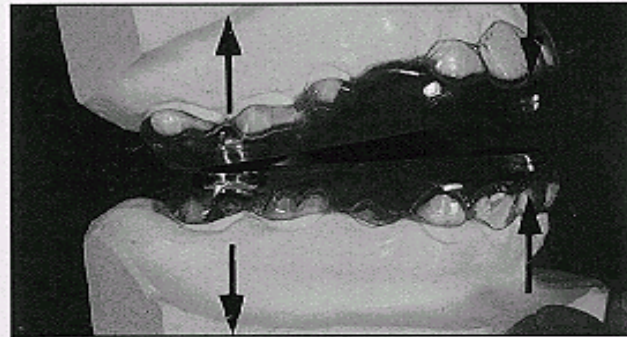
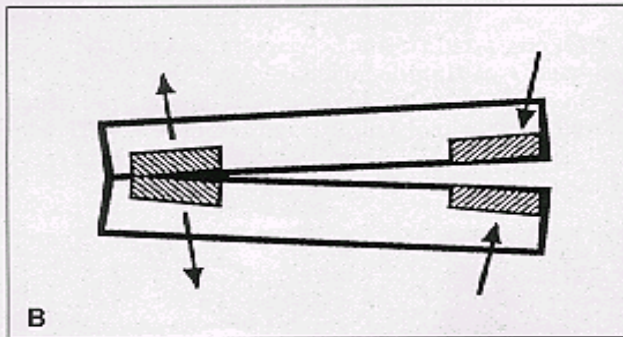
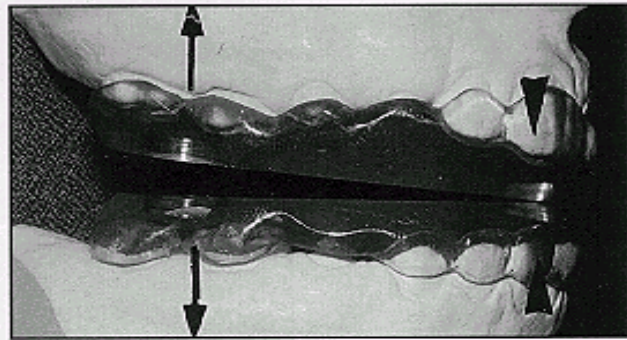
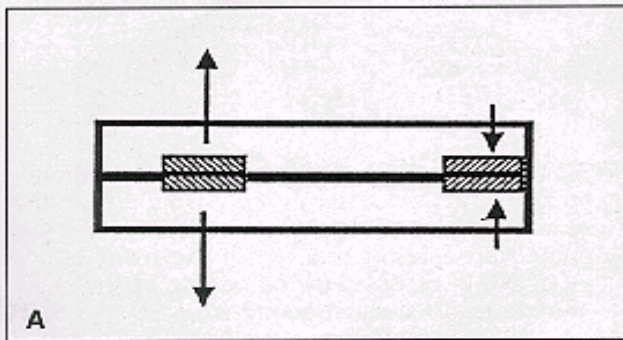
MAD IV c: used when only anterior extrusion is needed.

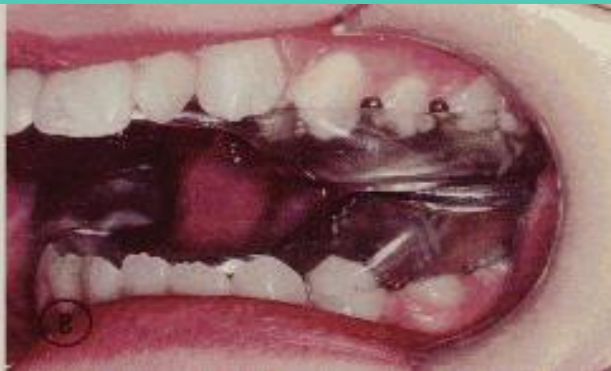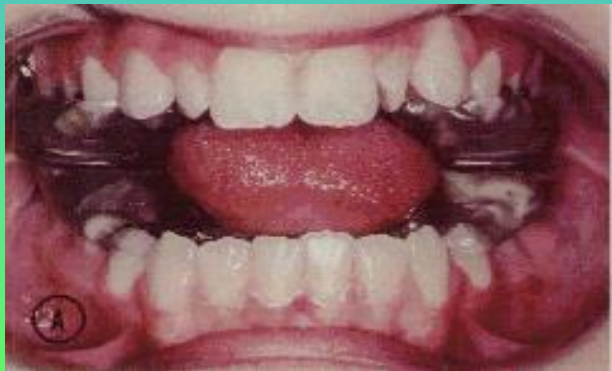
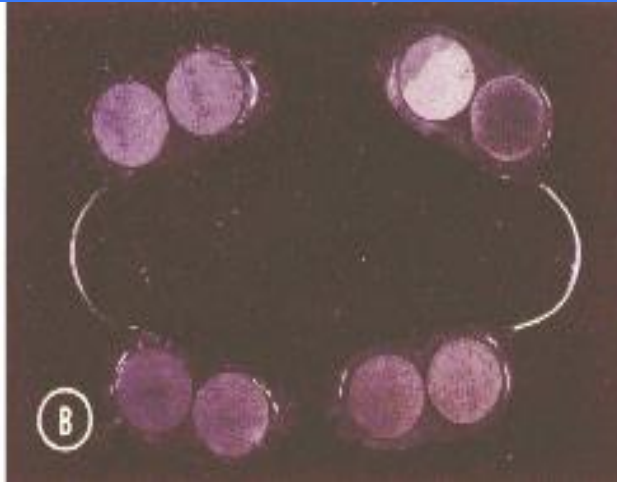
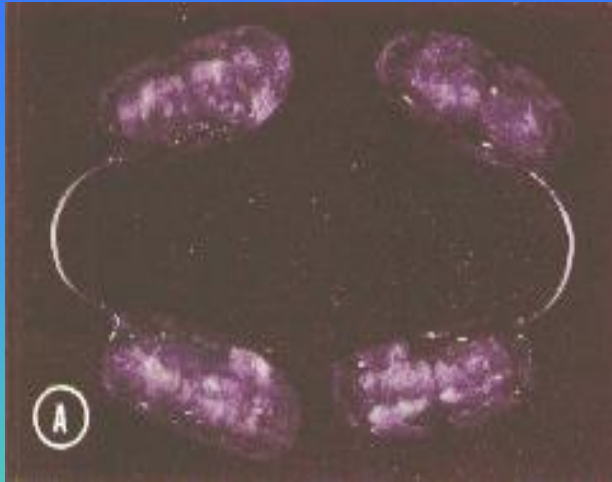


A

B

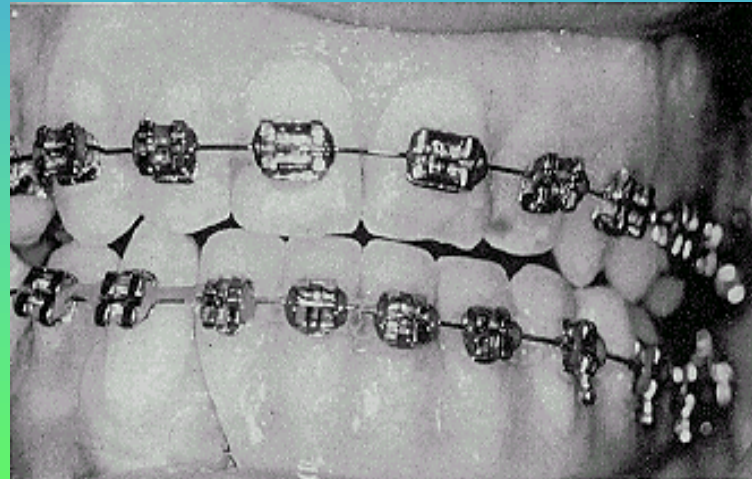
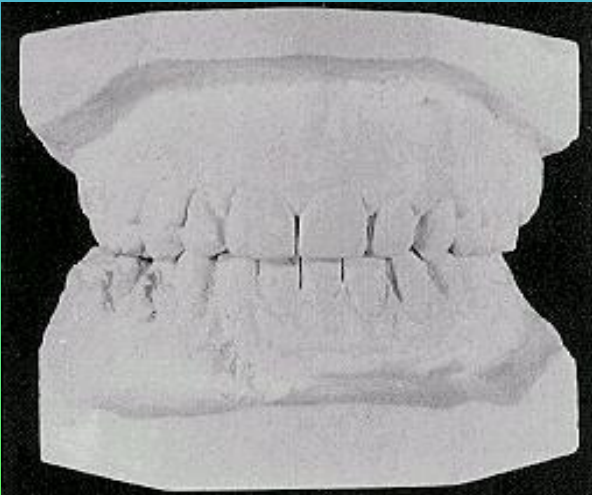
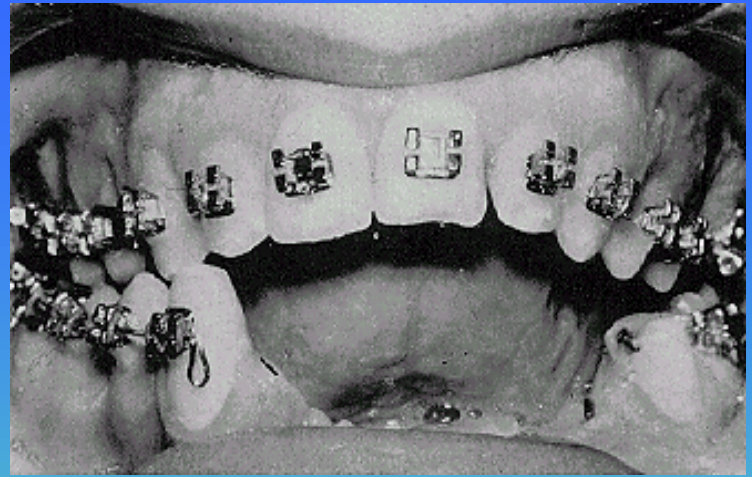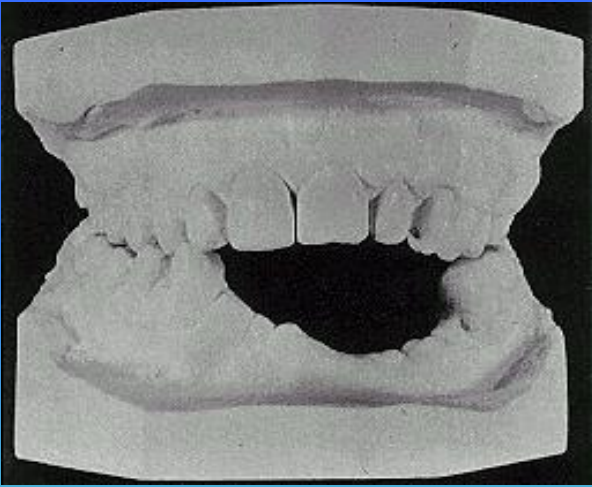
C





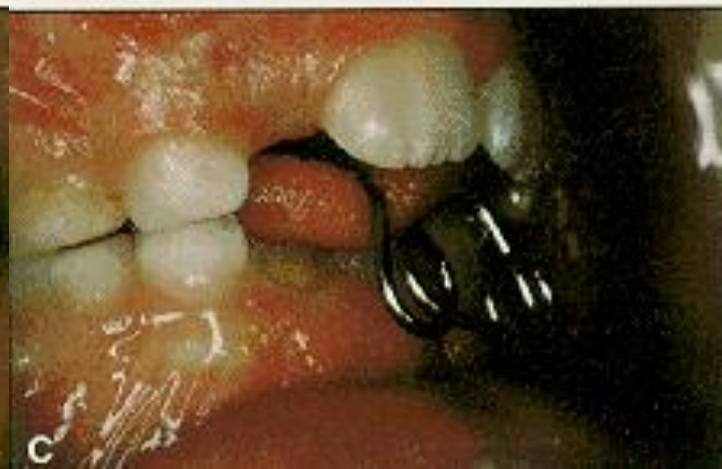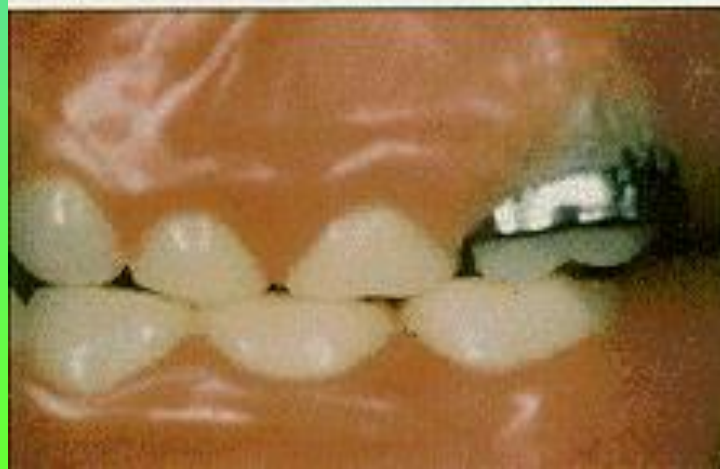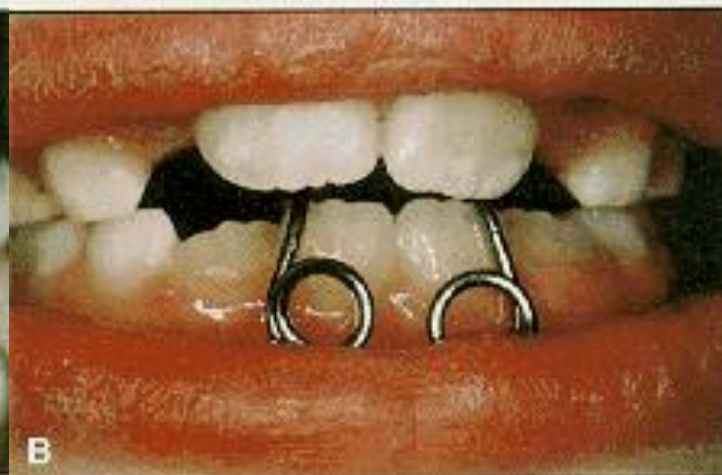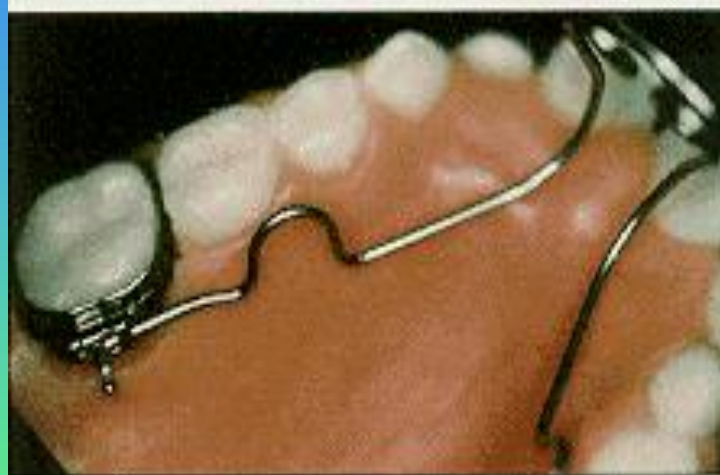
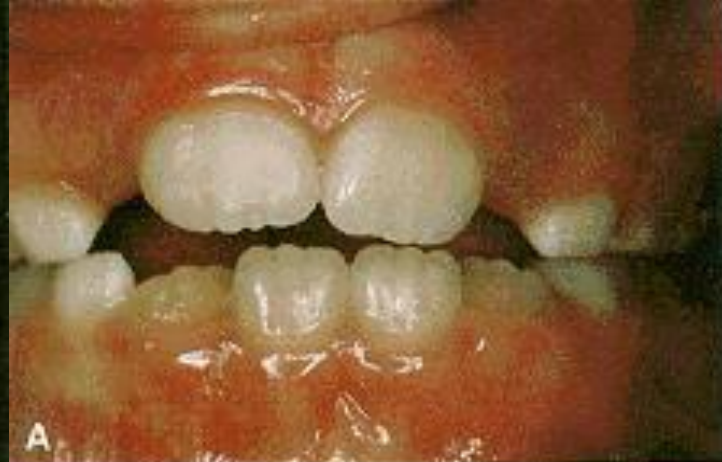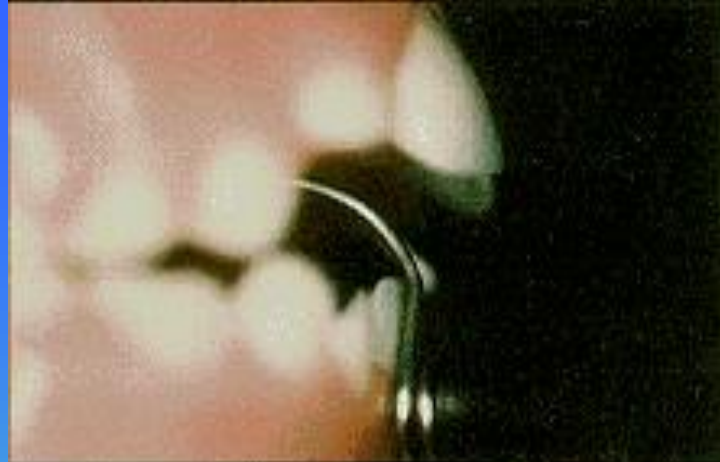# IMPLANTS

- Beth Prosterman et al. In 1995 has described the use of implants for correction of open bite.
- He concluded that since osseointegrated titanium implants show remarkable resilience to pressure they can prevent extrusion of mandibular post. teeth thereby preventing increase in ant. facial height
- He advocated the use of implants in conjunction with fixed appliances to correct ant. open bite.



# TCA

- Viazis in 1993 described the Thumb sucking / tongue thrusting / tongue posturing correction appliances.
- The TCA consists of a palatal wire that is inserted in the upper lingual molar sheaths & carries over to the lower incisors ending 1-2 mm. above the labial surface.
- The TCA prevents the habits by blocking the tongue from the ant. teeth.
- The TCA should be worn for at least 3 months.



# SAS

- Mikako Umemori et al. in 1999 described the SAS (Skeletal Anchorage System for open bite correction).
- The SAS consists of a titanium mini plate implanted in the maxilla or mandible.
- The mini plates were fixed in the buccal aspect of the bone at the apical region of first & second molars on both sides.
- Elastic threads were used as a source of orthodontic force for intrusion ( intrusion of 3-5 mm. achieved with SAS ).

# SAS

- Advantages of SAS :
  - No serious side effects.
  - Simplified treatment mechanics.
  - Shortened treatment period.
  - Minimum discomfort.
  - Control of the level of occlusal plane.

# Thera Spoon

- Bennett et al. In 1999 described the efficacy of open bite treatment with Thera spoon
- Compared to the Tongue crib where there is complete closure of ant. open bite & significant extrusion of the incisors , the Thera spoon does not show remarkable results.

# SURGICAL CORRECTION

- Hulliten in 1849, was the first to surgically correct an ant. open bite.( Ant. Mand. Sub-apical Osteotomy ).
- Cohn-stock in 1921, introduced Ant. Max. Osteotomy which was modified by Wassmund, Wunderer & Cupor.
- Schuchardt introduced Post. Max. Osteotomy as a two-stage procedure which was modified to a single-stage procedure by Kufner.

# SURGICAL CORRECTION

- Limberg in 1925, introduced Closed Subcondylar & Open oblique Osteotomy.

The present-day surgical techniques to correct open bite involves, Max. surgery for ant. extrusion & post. intrusion, and Mand. surgery to elevate the incisor segment. The choice of the appropriate surgical technique requires careful diagnostic evaluation.

# ANTERIOR MAX. & MAND. SUB-APICAL OSTEOTOMY

- INDICATIONS FOR MAXILLARY ASO

A small open bite with minimal tooth exposure, lip incompetance , good nasolabial angle & adequate lower ant.facial height.

An unaesthetic edentulous appearance due to concealed maxillary incisors.

- INDICATIONS FOR MAND. ASO

Ant. open bite due to reverse curve in the mandibular arch.

Transverse max.-mand. harmony & good aesthetic balance between upper lip & max. ant. teeth.

After surgery the max. & mand. Ant. Segment are immobilised for 5-6 weeks. Relapse potential is very minimal.

# KOLE MODIFICATION OF SUB-APICAL OSTEOTOMY

- INDICATIONS

Mandibular prognathism with ant. open bite.

Severe reverse curve.

Excessive chin height.

Functional post. occlusion.

Satisfactory lip-tooth relationship & no transverse deficiency in maxilla.

The principle disadvantage here relates unpredictable soft tissue profile changes & chin height changes.

# SAGITTAL SPLIT RAMUS OSTEOTOMY

- This surgery can be performed in both extraction & non-extraction cases.
- It is indicated in open-bite cases with severe mand. deficiency or prognathism.
- It is usually done along with maxillary osteotomy to minimize relapse.
- If performed separately, posterior overcorrection with an interocclusal splint, supra-hyoid myotomy and cervical collar should be considered to prevent relapse.

# LE FORT-I MAXILLARY OSTEOTOMY

This surgery is indicated in open-bite cases with:

- High & constricted palatal vault.
- Lip incompetence.
- High mand. plane angle.
- Increased distance between the palatal root apices & the nasal floor.

- If the inferior turbinates are interfering with the repositioning of the maxilla, they are trimmed with a Mayo scissors (Adjunctive Inferior Turbinectomy ).
- Stabilization of the maxilla is done with trans-osseous 26-guage wire sutures.
- If there are bony defects after surgery, bone grafts from the Iliac crest or Hydroxyapatite crystals are used to bridge them.

# ADJUNCTIVE SURGICAL PROCEDURES

Adjunctive surgical procedures have to be performed to combat either, a large tongue or a tongue with abnormal function, which cause open-bite or even its recurrence.

To correct True, Relative or Functional Macroglossia the following procedures are performed:

- The V excision for partial glossectomy.
- Keyhole procedure for partial glossectomy.
- Deep lingual frenectomy.

# THE 'V' EXCISION

A 'V' shaped excision is made from the front of the tongue, lateral to the midline & extending posteriorly in nearly a straight line, converging at the midline at about 4mm from the Circumvallate papillae. The dorsum of the tongue is closed by layers using 3-0 & 4-0 chromic sutures & the ventral surface is sutured by one layer.

# THE KEYHOLE PROCEDURE

A Keyhole shaped mass of muscle is excised when the tongue is too large in the molar area and the ant. fourth is nearly normal.

The ant. incision begins at the tip of the tongue and extends posteriorly until it reaches the expanded part of the keyhole begins. The posterior incision curves laterally and forward and then towards the midline until it joins the posterior end of the ant. incision. A mirror image incision is

made through its opposite side. The posterior incision should taper like a funnel to avoid any injury to the Lingual artery, nerve, vein, & the Hypoglossal nerve.

After surgery the jaws must be immobilised so that the mouth has a fixed volume and also act as a splint. Tongue exercises are advocated after the 14th post-op day.

# DEEP LINGUAL FRENECTOMY

- Deep lingual frenectomy with 'Z' plasty is indicated in Ankyloglossia or Functional macroglossia where the tongue does not adapt after ortho. or surgical treatment.
- A linear excision of the mucosal portion of the thickened frenum is made (care-submandibular duct opening). The dissection of the fibrosed Genioglossus extends posteriorly until desired amount of mobility is achieved. Exercises should be advocated till about 2 months after surgery.

# GENIOPLASTY

Fridrich et al. in 1997 described various Genioplasty strategies for anterior facial vertical dysplasias.

Different types of Genioplasty:

- Sliding advancement genioplasty
- Genioplasty with parallel osteotomy
- Genioplasty with down graft
- Genioplasty with anteriorly tapered osteotomy
- Sliding setback genioplasty

Fridrich stated that failure to recognise vertical dysplasia of the mandible will lead to post-op mentalis strain.

He concluded that, in vertical dysplasias, genioplasty gives good esthetic results with functional harmony.

# TMJ CONSIDERATIONS

The status of the TMJ is of great importance before surgery, because the movements associated with surgery increase pressure in the joint until the muscles, soft tissues & dento-osseous structures readapt.

Hence, if pre-existing TMJ disorders are carefully assessed and appropriately managed, the TMJ is stable after the surgery is performed.

# **RETENTION & RELAPSE**

**The main etiological factors responsible for relapse after ortho correction are:**

- Latent vertical growth of the face.**
- The role of the tongue.**

**The main etiological factors responsible for relapse after surgical correction are:**

- Mandibular musculature**
- Incompletely understood biomechanical factors influencing the Elevator group & Suprahyoid group of muscles.**

# RETENTION & RELAPSE

The success of treatment depends upon the ratio:

$$\text{Success} = \frac{\text{Magnitude of improvement}}{\text{Magnitude of relapse}}$$

Wick Alexander stated that retention begins with Diagnosis & Treatment planning.

‘Begin with the end in mind’ should be the philosophy of treatment.

# RETENTION & RELAPSE

## RETENTION AFTER ORTHODONTIC CORRECTION :

Criteria to begin retention are :

- Coincidence of Centric relation & occlusion.
- Class I cuspid relation.
- Maintenance of mand. cuspid width.
- Interincisal angle close to normal.
- Normal ant. Overbite & Overjet.
- Normal Buccal Overjet.

# RETENTION & RELAPSE

## **Criteria:**

- Levelled max. & mand. arches.
- All spaces closed & all rotations eliminated.
- Roots parallel near extraction sites.
- Posterior cusps may or may not be settled.

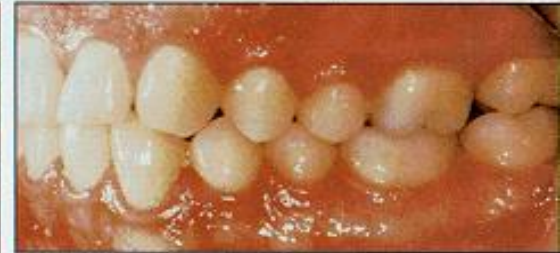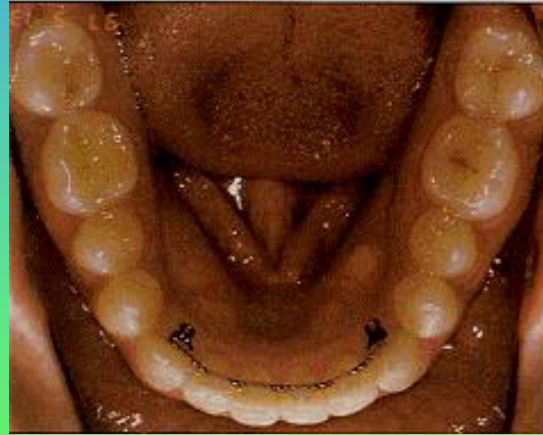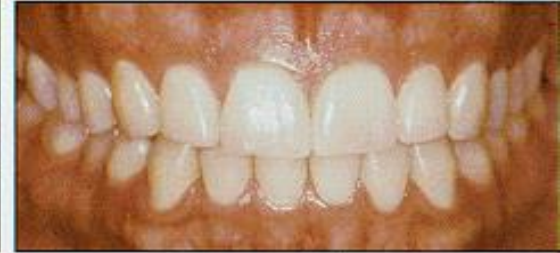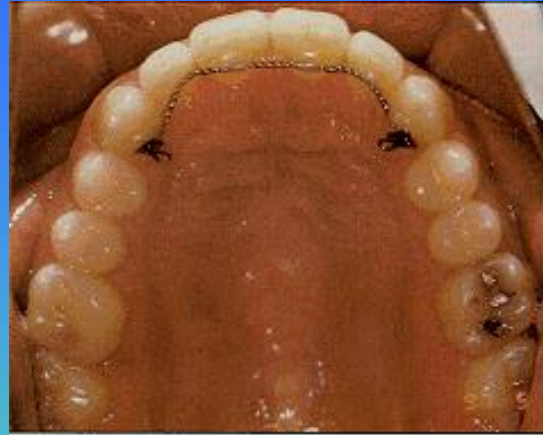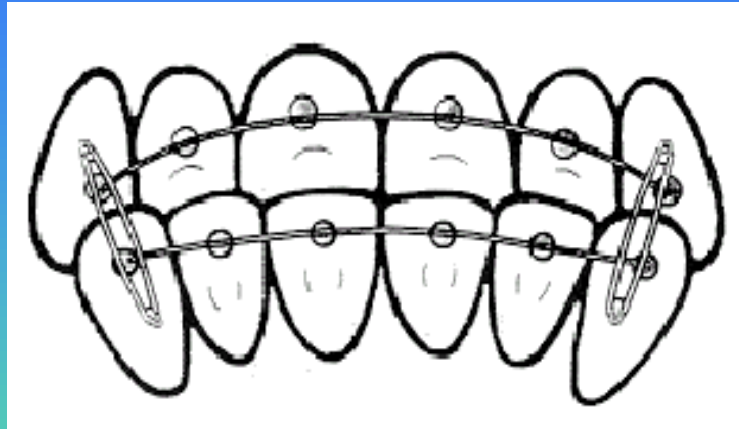
# RETENTION & RELAPSE

Active retention normally utilizes :

- A maxillary wraparound retainer and a mandibular 3x3 bonded retainer.
- A full coverage clear acrylic appliance.
- In conjunction with myofunctional therapy, tongue position exercises are advocated.

# RETENTION & RELAPSE

John Sheridan in 1997, described the Force Amplified System for corrected open-bite. It involves the use of conventional max. & mand. cuspid to cuspid bonded lingual retainers, low-profile bonded lingual Caplin hooks and intraoral elastics. The retainers are bonded to each tooth to distribute the elastic forces.



# RETENTION & RELAPSE

## RETENTION AFTER SURGICAL CORRECTION :

- Upper & lower border wiring of the mandible.
- Steinmann pins to stabilize the maxilla.
- Skeletal wire fixation(Circumzygomatic & Circummandibular wires).
- Rigid fixation.

**CONCLUSION**

