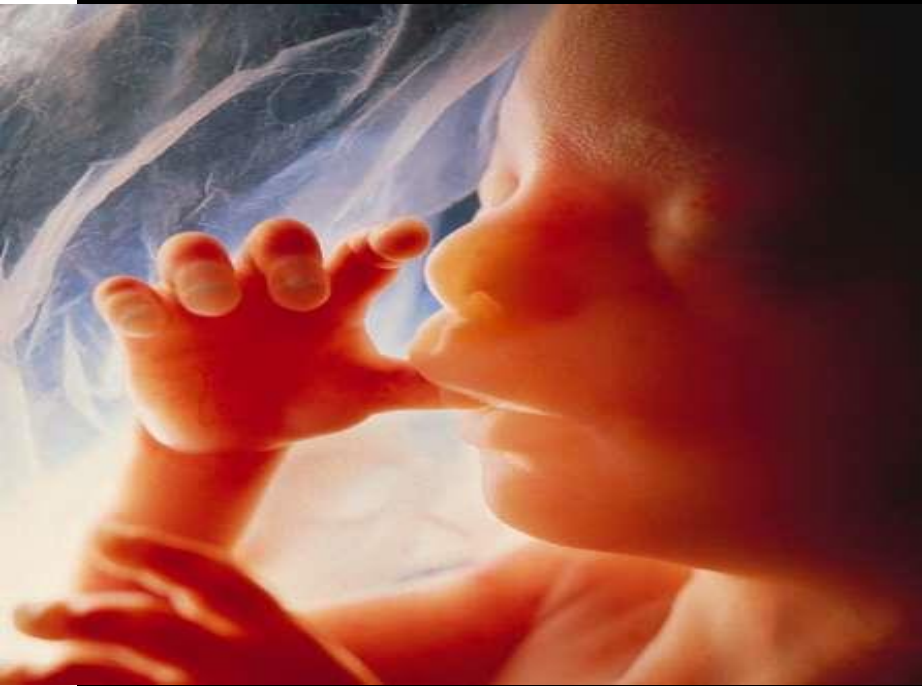



ORAL HABITS

BY - DR MEGHA GOSWAMI

Contents

- Habit
 - Definition
 - Classification
 - Trident of habit
 - Dental response to pressure habits
 - Treatment philosophy
- Thumb Or digit sucking
- Tongue thrusting
- Mouth breathing
- Nail biting
- Cheek biting
- Bruxism

Habit

- **William James-**

From psychological view, Is a Pathway of discharge formed in brain by which certain incoming currents ever after tend to escape....

- **Dorland –**

Fixed or constant practice established by frequent repetition

- **Moyer**

Habits are learnt pattern of muscle contraction of a very complex nature

Habits: Classification

Obsessive

(Deep rooted)

- Intentional OR meaningful
- Masochistic or Self-inflicting injurious habit

Non- obsessive

(Easily learned)

- Empty or Unintentional
 - Abnormal pillowing, chin propping
- Functional
 - Tongue thrusting

Habits: Classification

- James (1923)/ Graber
 - Useful
 - Harmful
- Kingsley
 - Functional oral habit
 - Muscular habit
 - combined
- Finn (1987)
 - Compulsive habits
 - Non- compulsive habit
 - ✱ Primary habit
 - ✱ Secondary habit
- Klein (1977)
 - Empty
 - meaningful



- Morris and Bohanna (1969)

- Non pressure habit

- Pressure habit

- Sucking habit

- Lip, Thumb sucking, Tongue thrusting

- Biting habit

- Nail biting, Needle, Thread holding

- Posturing habit

- Pillow, Hand rest

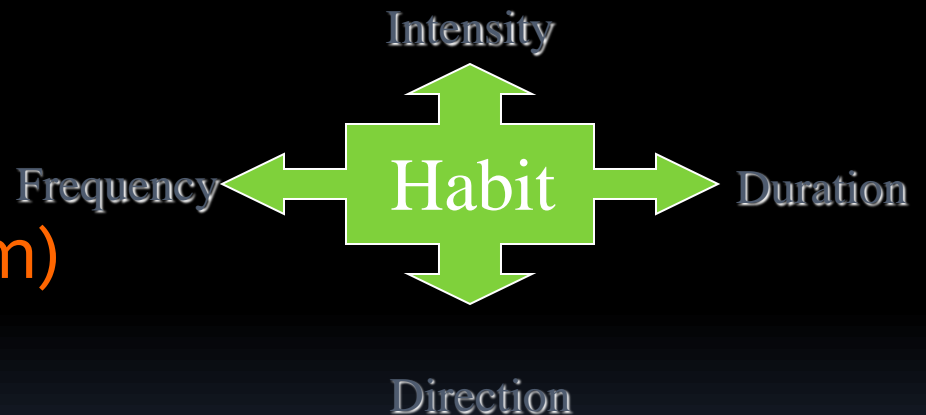
- Miscellaneous

- Bruxism, Cheek biting
- 

Trident of Habit

- Intensity
- Frequency
- Duration

- **Direction (Pinkham)**





THUMB SUCKING



Thumb or Digit sucking

- **Definition -**

Placement of thumb or one or more fingers in various depths into the mouth or oral cavity

- **Synonyms**

- Thumb sucking/ Digit sucking/ Finger sucking



Classification

- Normal thumb sucking
- Abnormal thumb sucking

● Psychological

● Habitual

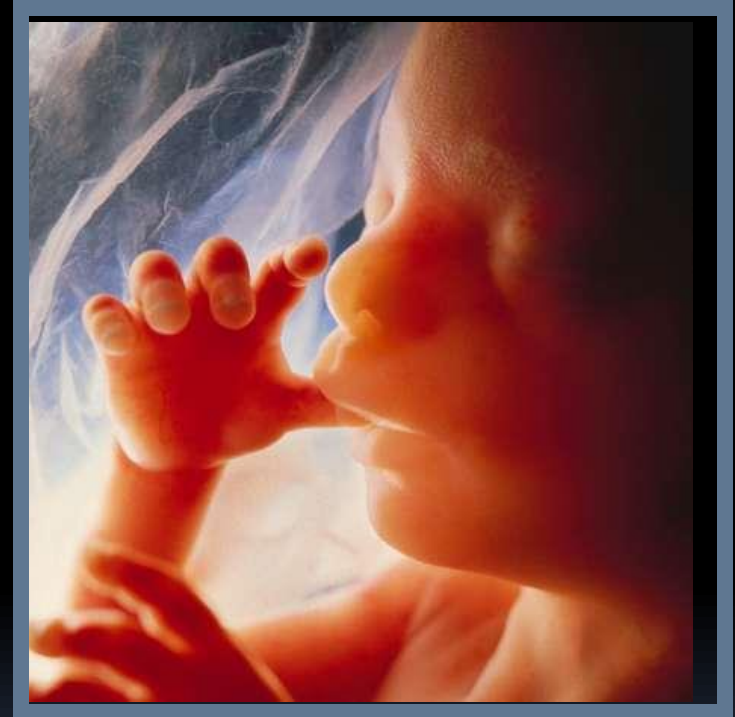

■ Sucking reflex

- Starts at 29 week I.U.
- Disappear by 3 - 4 yr
- First coordinated muscular activity
- Psychological and nutritive need

■ Rooting(Placing) reflex

- Well defined sensory area around mouth
- Head turning and opening of mouth by stimulation



Initiation of digit sucking (Infantile)

- Development of muscular coordination
- Ability to reach the face with hand
- Exploration of environment by placing objects in mouth
- Introjection and Projection



Retained digit sucking

- Lack of oral gratification
- Separation from mother
- Social structure or culture
 - Eskimo study
 - Burlington study



■ Theories (Etiology)


- Classical Freudian theory (1905)
 - Biologic sucking drive (I.U.)
 - Oral phase- Center of attraction (Oro -erotic zone)
 - Deprivation of activity - Insecurity
 - Assoc. With pleasurable stimuli, but not discarded at usual time due to psychological disturbance
 - Substitution with less desirable habit



- Benjamin theory (1962)


Experimentation on monkey

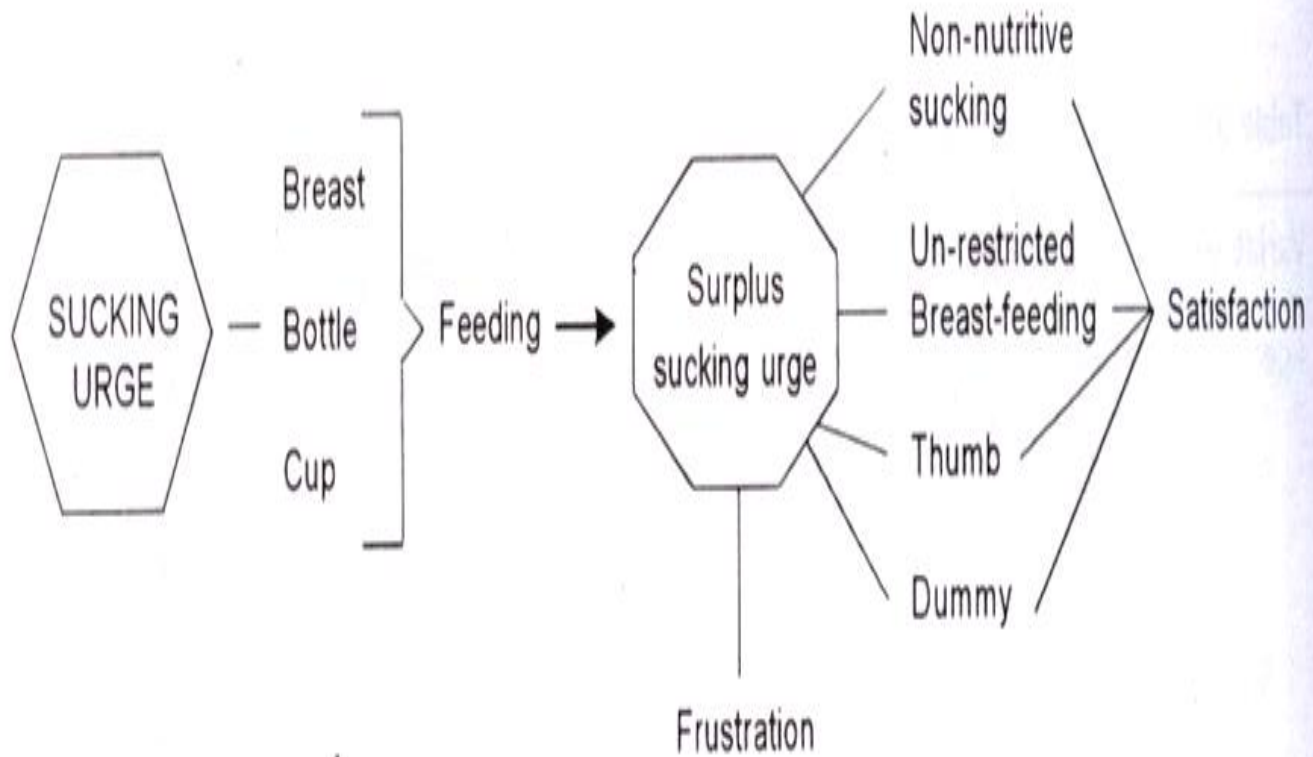
Two theories

- Thumb sucking - Expression associated with sucking along with primary reinforcing aspect of feeding
 - Thumb sucking from Rooting and placing reflex
- 



- Learning theory: Davidson (1967)

- Adaptive response to pleasurable feeling
 - No underlying cause
 - No emotional or psychological problem
 - No substitute
- 



➤ Causative factors

1. Parent's occupation
 1. Socioeconomic status
- Working mother
 - ▶ Absence – insecurity
- No. of siblings
 - ▶ Compensation for neglect

4. Order of birth of child
 1. Imitation
5. Social adjustment and stress
 1. Peer pressure, scolding parents
6. Feeding practices
 1. Negative relation between breast feeding and habit

7 Age:

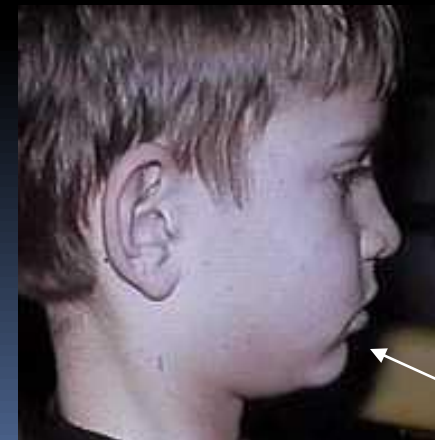
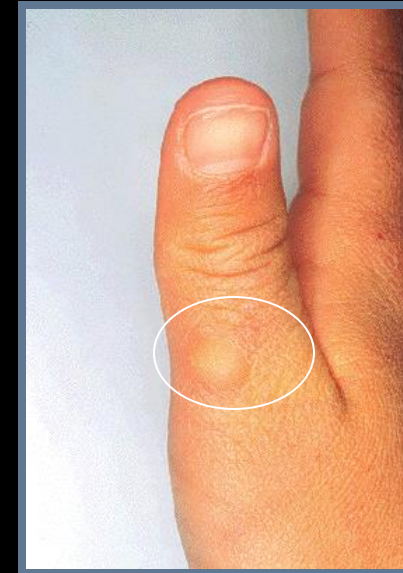1. In neonates
 1. Well developed suckling mechanism
 2. Primitive Demand for hunger
2. During eruption of primary molar- Teething
3. Still later (Active after 4 year)
 1. Emotional tensions
 2. Stress outlet mechanism

Diagnosis

- Emotional status
 - Meaningful or empty
- Case history
 - Active performance
 - Information from mother
 - Feeding practice
 - Parental care
 - Presence of other habits


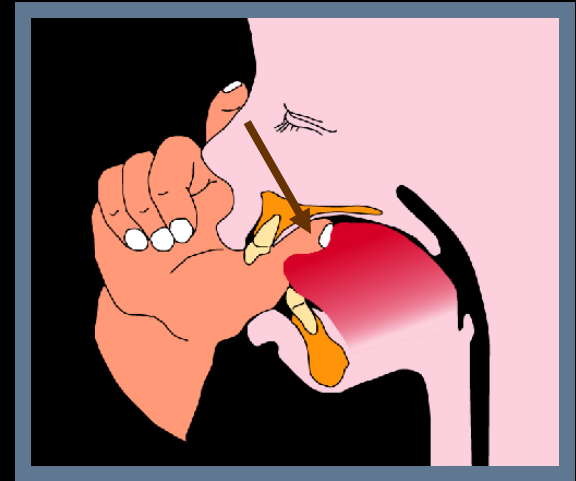
Extra oral examination

- Digit
 - Reddened, clean, chapped, short fingernail (dishpan thumb)
 - Chronic suckers - fibrous, roughened callus on superior aspect of finger
 - Deformation of finger
- Lip
 - Position at rest, During swallowing
 - Hypotonic upper lip
 - Hyperactive lower lips



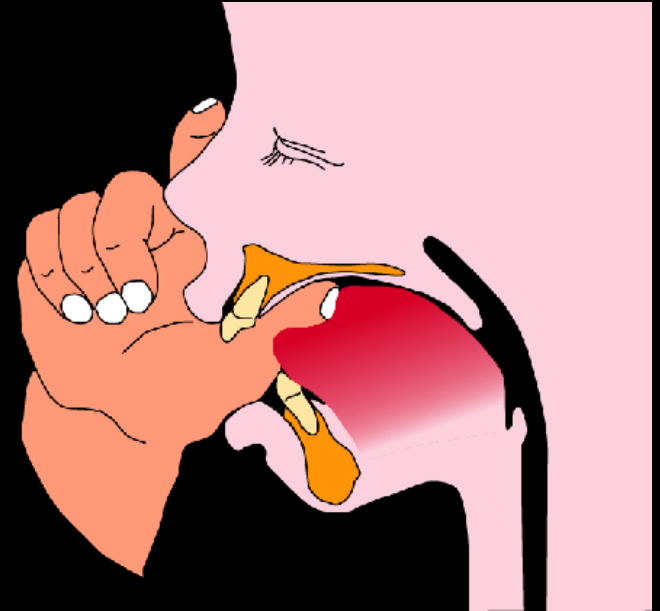
■ Facial form analysis

- Maxillary protrusion
- Mandibular retrusion
- High mandibular plane angle
- Profile
- Mentalis muscle contraction



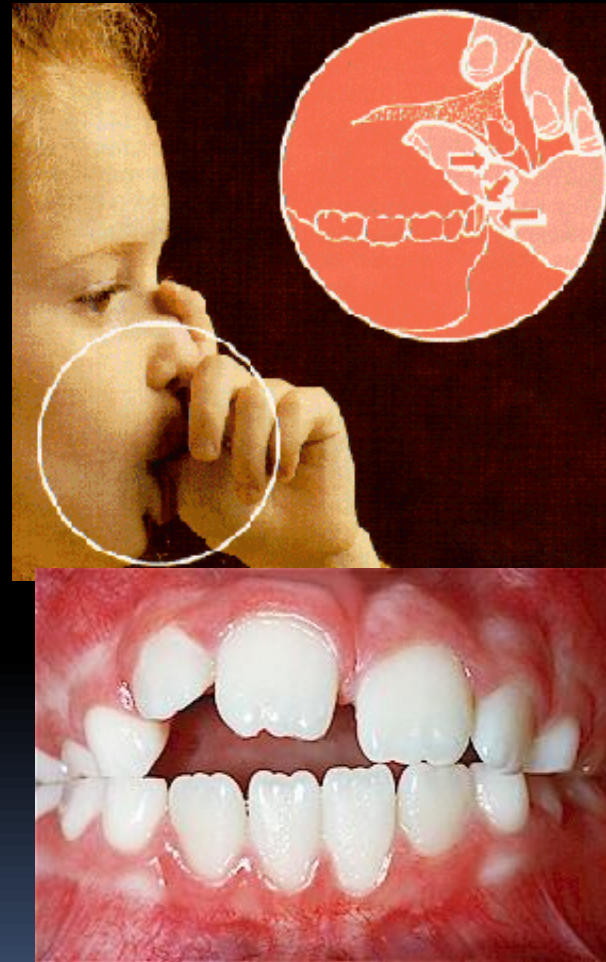
Intraoral examination

- Tongue
 - Position at rest , during swallowing
- Gingiva
 - Evidence of mouth breathing
 - Itching
 - Staining on max. labial surface



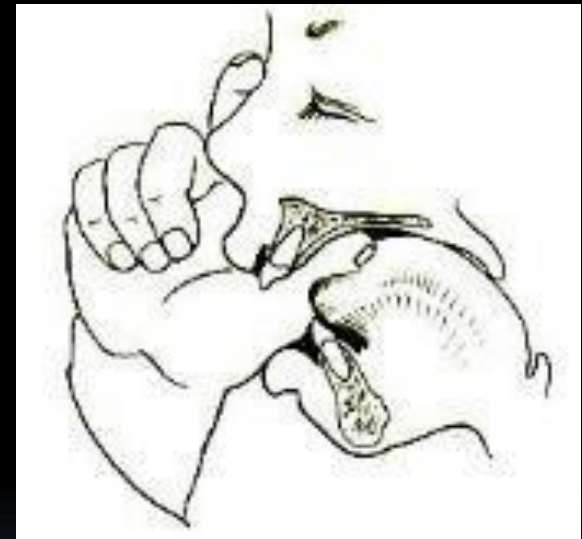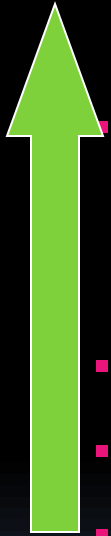Intra oral examination

- Dento alveolar structure
 - Flared , proclined maxillary anteriors with diastema
 - Retroclined mandibular anteriors
 - Deformed right or left sided max. arch



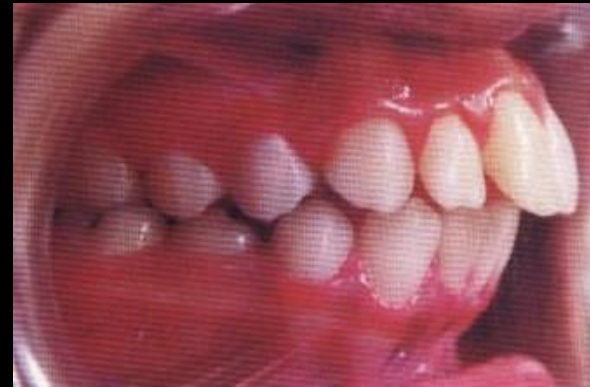Effects on maxilla

- Maxillary arch length
- Clinical crown length of incisors
- Counterclockwise rotation of occlusal plane
- Atypical root formation
- Trauma to incisors
- Palatal arch width

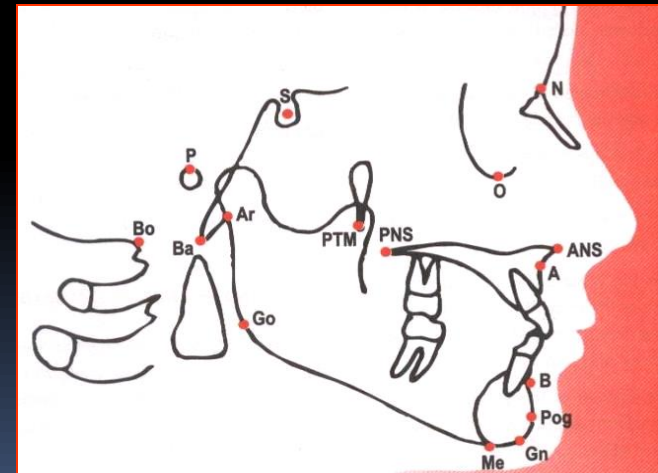


Effect on mandible

- Proclination of incisors (Finger sucking)
- Increased Intermolar distance

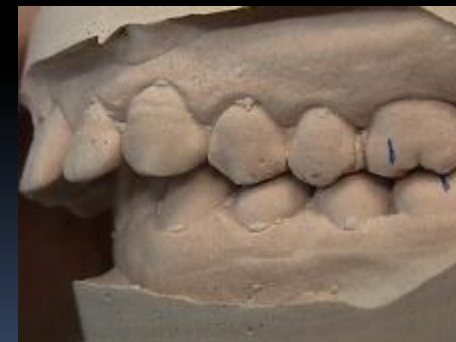
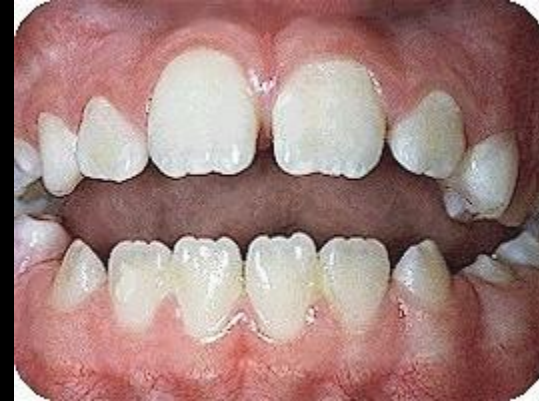
- Increased Distal position of B point

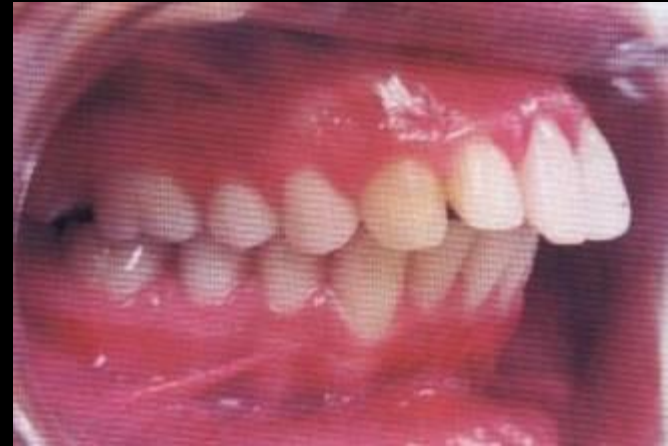

CLINICAL FEATURES

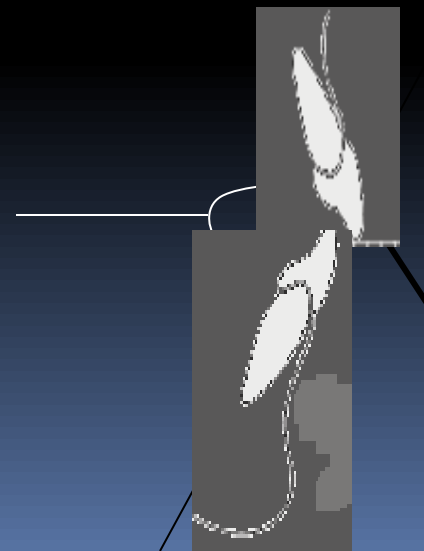
- Effect on interarch relationship
 - Anterior open bite
 - Increased over jet



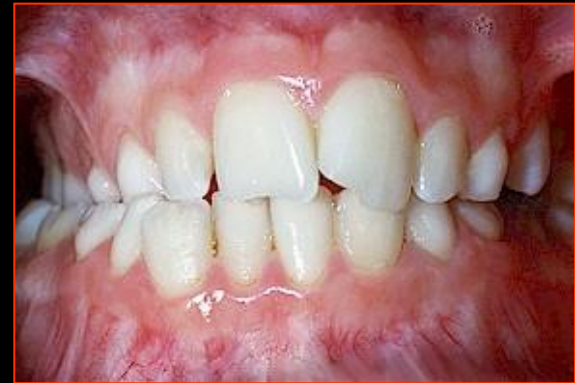Increased unilateral
and bilateral CI II
malocclusion



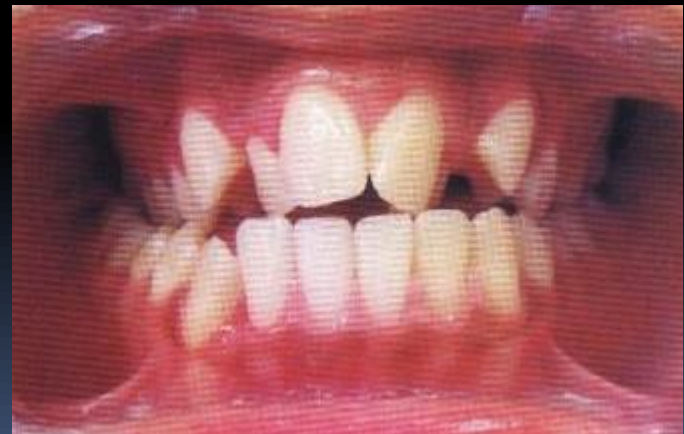Decreased U/ L incisal angle



- Decreased overbite



- Increased posterior cross bite




Clinical aspect (Moyer: 1955)

- Phase I
 - Normal or sub clinically significant sucking (Pre school infant)
 - Birth to 3 yr
 - Prophylactic approach
- Phase II
 - Clinically significant sucking (Grade school)
 - 3 – 7 yrs
 - Related to anxiety
 - Time for dental correction
 - Firm and definitive programme of correction



□ Phase III

- Intractable sucking (Teenage child)
 - Beyond 4th yr
 - Psychotherapy
 - Treatment for malocclusion
- 

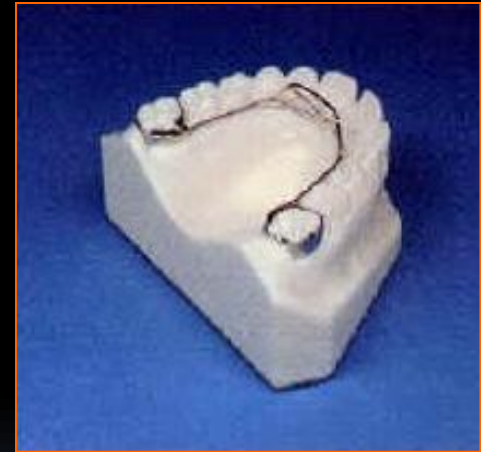Treatment

- Psychological
 - Avoidance of scolding, frightening
 - Reassurance and positive reinforcement
 - Friendly reminders
 - Brauer (1965)
 - Constructive parental education
 - Favorable contact with environment
 - Providence of age specific suitable play material
 - Avoidance of unnecessary regulation

- β- Hypothesis or Dunlop's hypothesis
 - Forced purposeful repetition
 - Abandonment of habit following unpleasant reaction
- chemical treatment
 - Least effective
 - Bitter or sour chemical over the finger
 - E.g. : Foul smelling Quinine, Asofoctine, Pepper , Caster oil, Femite etc

Mechanical or reminder therapy

- Removable and fixed appliance
 - Palatal crib
 - Breaks the suction and force on anterior segment
 - Reminder
 - Makes the habit nonpleasurable

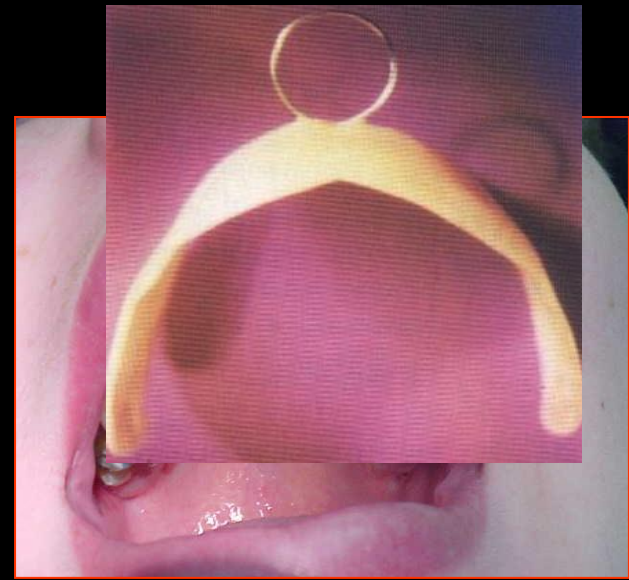

- **Oral screen**

- Functional appliance
 - Redirection of muscular and soft tissue pressure
- Prevention of placement of thumb in mouth

- **Quad helix**

- Expansion of constricted maxillary arch
- Helixes as a reminder
- Posterior cross bite correction



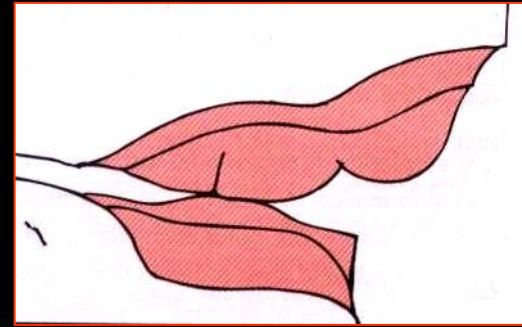


TONGUE THRUSTING

Tongue thrusting

- Embryonic life
 - Proportion of tongue to developing mandible

- Spacing between Gum pads



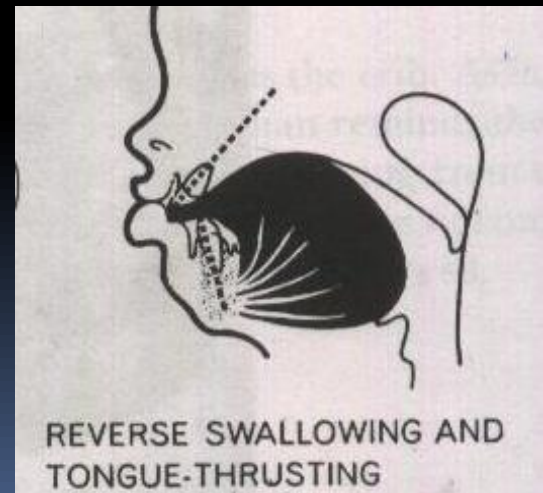
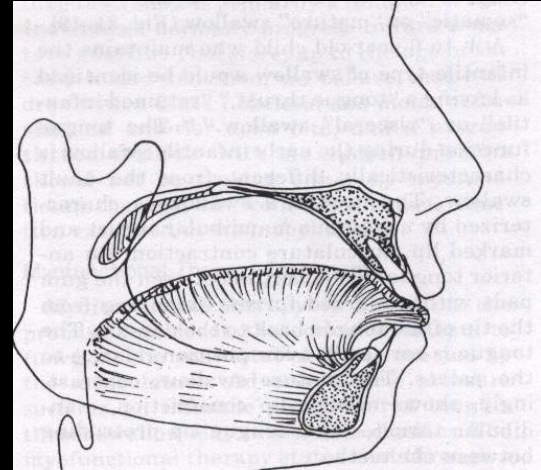
Anatomy and Physiology of Sucking and swallowing

Sucking –

First Coordinated muscular activity

Infantile swallow (Moyer)

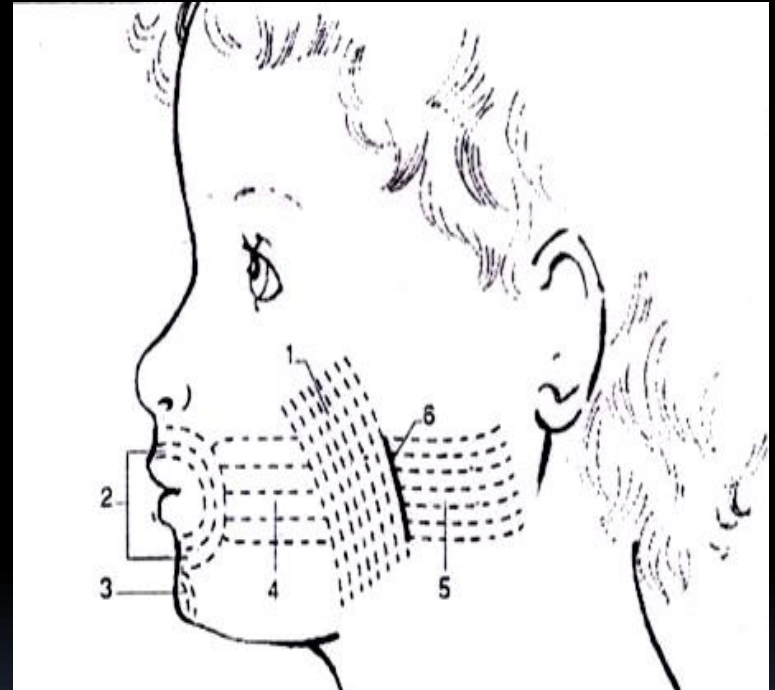
- Anterior tongue thrust between gum pads
- Mandibular thrust, and stabilization by contraction of facial muscles
- Lip constriction



Infantile swallow


Muscles involved

1. Masseter
2. Orbicularis oris
3. Mentalis
4. Buccinator
5. Superior pharyngeal constrictor
6. Pterygomandibular raphe



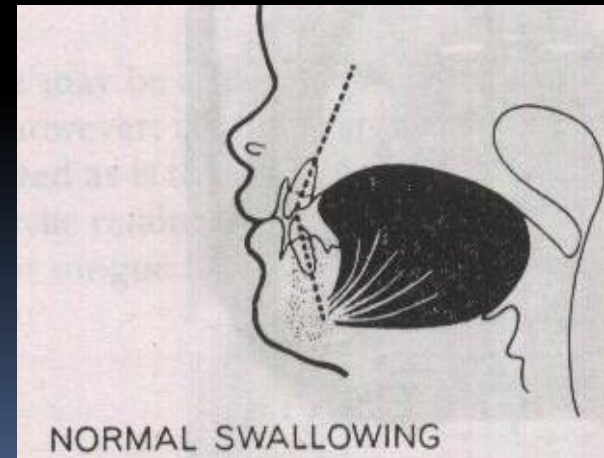
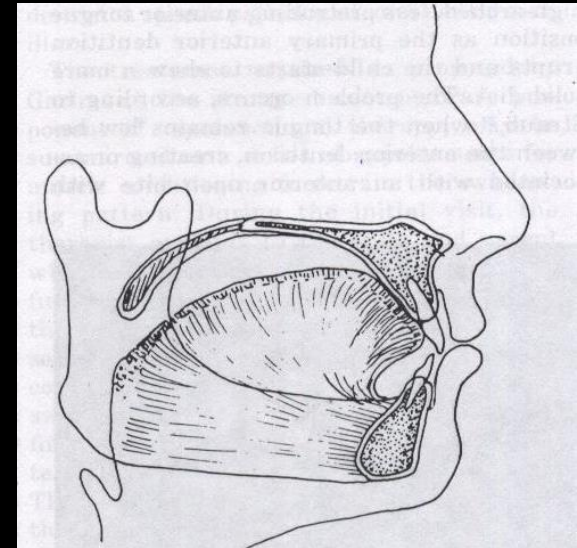


- **Transitional swallow**

- Inter mixing of normal infantile swallow and mature swallow
 - Diminishing Buccinator activity
 - Contraction of mandibular elevator during swallow to stabilize teeth in occlusion
- 

Mature swallow

- **Position of tongue (Stewart)**
 - Tongue tip
 - Mid portion
 - Posterior aspect- 45° angulation against pharyngeal wall
- Lip seal
- **Function of masseter, Mentalis, and facial muscles**



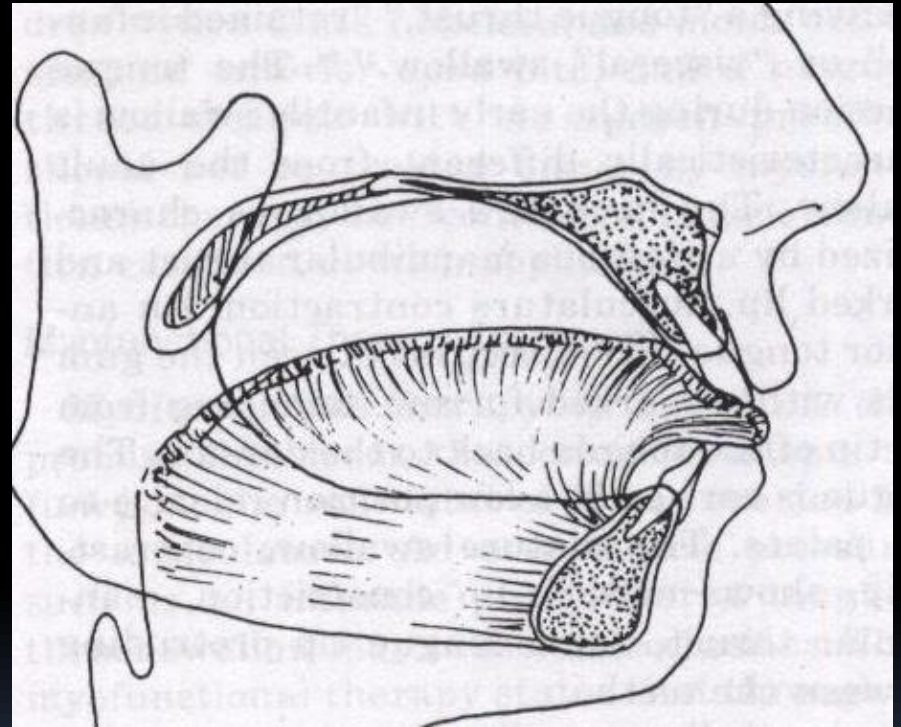
- **Abnormal swallow (Stewart)**

- **Position of tongue**

- Tip
- Mid portion
- Posterior aspect

- **Faulty Masseter activity**

- **Mentalis activity**



Definition

- Brauer -


Tongue thrust is said to be present if the tongue is observed thrusting between and the teeth did not close in centric occlusion during deglutition

- Tulley -

Forward movement of tongue tip between the teeth to meet the lower lip during deglutition and in sounds of speech , so that the tongue becomes interdental



Classification

- Physiologic
 - Infancy
 - Habitual
 - Present after correction of malocclusion
 - Functional (Profit)
 - Overjet, Open bite
 - Anatomical
 - Macroglossia
- 

Type I : Non-deforming tongue thrust

Type II : Deforming anterior tongue thrust

Sub group 1 : Anterior open bite

Sub group 2 : Anterior proclination

Sub group 3 : Posterior crossbite

Type III : Deforming lateral tongue thrust

Sub group 1: Posterior open bite

Sub group 2 : Posterior crossbite

Sub group 3 : Deep overbite

Type IV : Deforming anterior and lateral tongue thrust

Sub group 1: Anterior and posterior open bite

Sub group 2 : Proclination of anterior teeth

Sub group 3 : Posterior crossbite

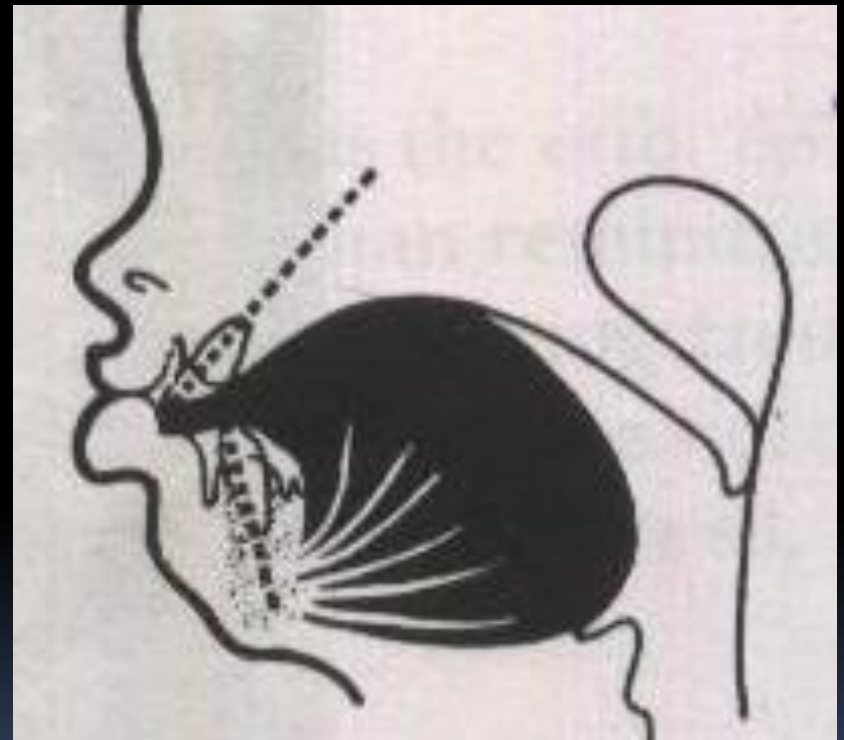
Simple Classification of Tongue thrust

Simple tongue thrust

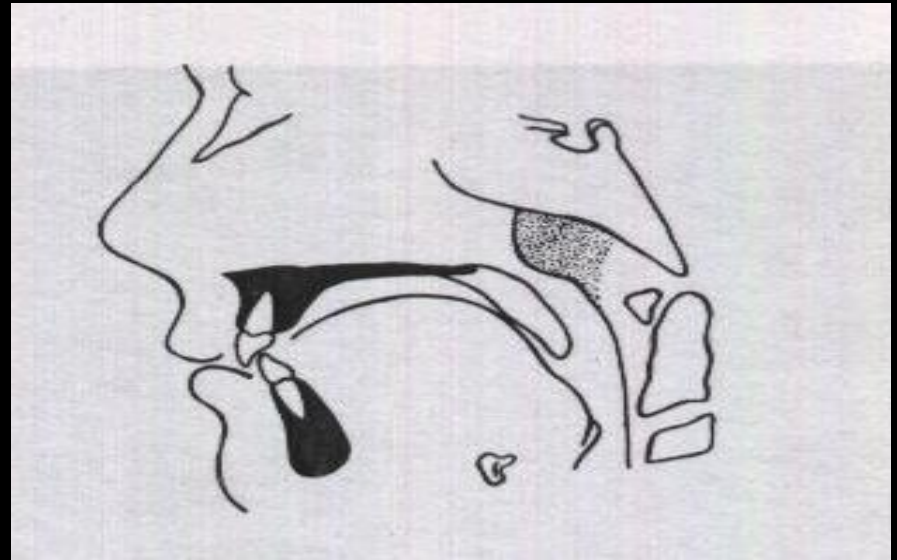
Complex tongue thrust

Etiology

- **Retained infantile swallow**
- Retention of infantile suckling mechanism
- Incisor eruption – No drop of tongue
- Altered Tongue posture at rest
- Contraction of lips , facial muscles
- Increased buccinator activity
- Inexpressive face
- Poor prognosis



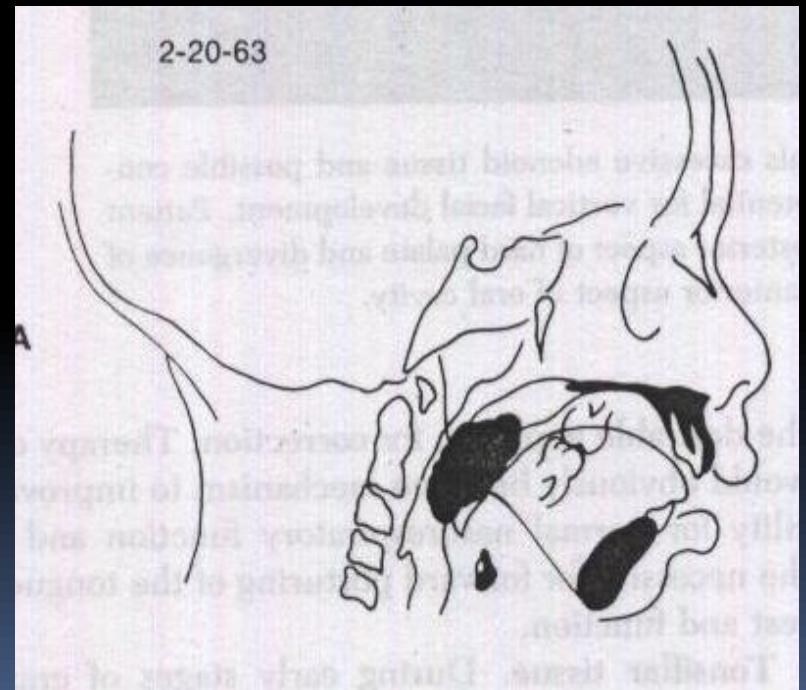
- Adenoids



- Lymphoid tissue (Tonsils)

- Hypertrophy

- Obstruction of oropharyngeal area

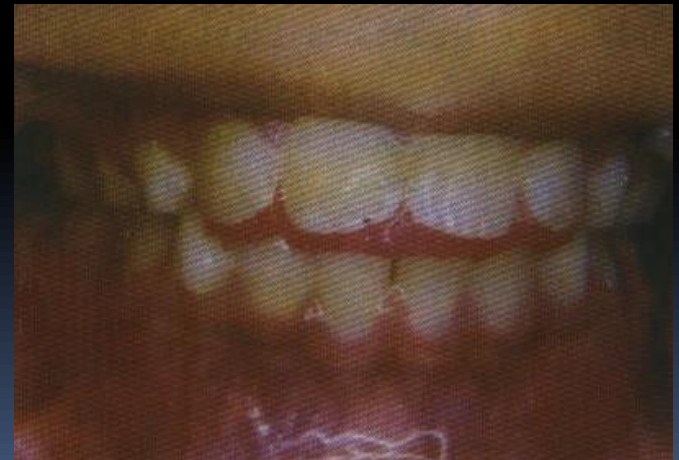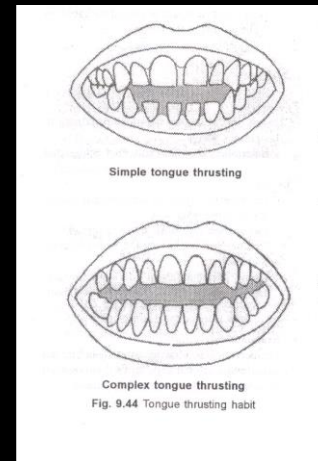


Classification of etiological factors: Fletcher (1975)

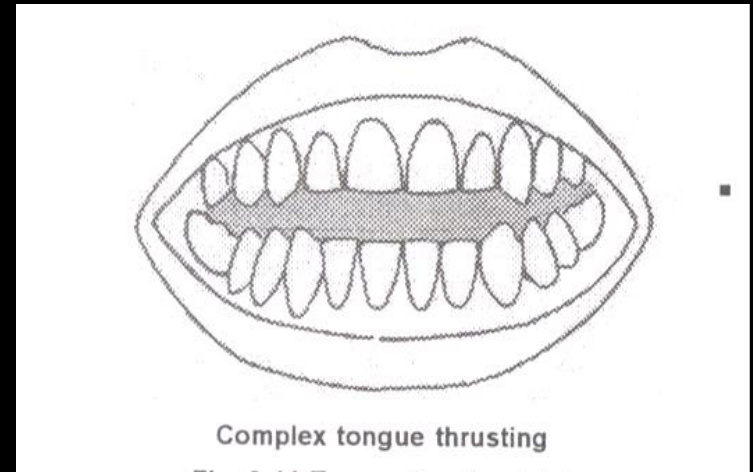
1. Genetic factor
 1. Inherited variation in orofacial form
 - Constricted arch
2. Learned behavior
 1. Acquired habits
 2. Prolonged Tonsillar hypertrophy, URTI
3. Maturational
 1. Delayed progression from infantile to mature
4. Mechanical restriction
 1. Macroglossia, constricted dental arches, Enlarged adenoids
5. Neurological disturbances
 1. Hyposensitive palate, motor disability
6. Psychological factors
 1. Effect from forced discontinuation of other habit



Diagnosis

- Simple tongue thrust
- Molar occlusion
- Ant. Open bite
- Contraction of lips, Mentalis, mandibular elevators
- Adaptive mech to maintain an open bite
 - well circumscribed
 - Precise intercuspatation
 - Simple treatment
 - Diminishes with age



- **Complex tongue thrust**
- Generalized open bite
- Absence of contraction of mand elevators .
- Contractions of lips, facial and mentalis muscles
- Teeth apart swallow
- Diffuse open bite
- Poor occlusal fit
- Does not diminish with age
- Poor prognosis.



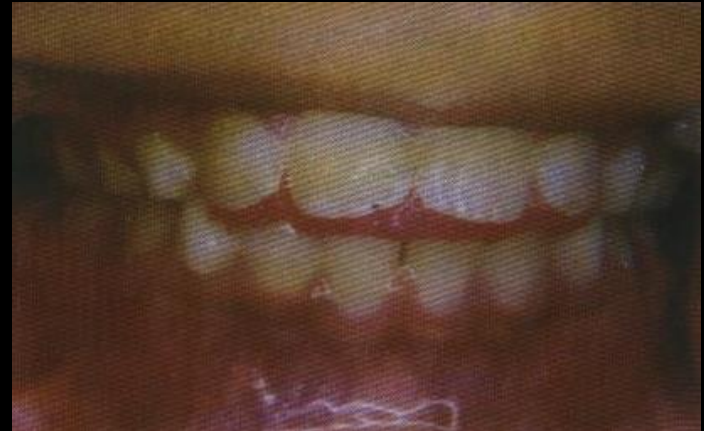- 
- Lateral tongue thrust
 - Posterior open bite
 - Tongue thrusting laterally
- 

CLINICAL FEATURES

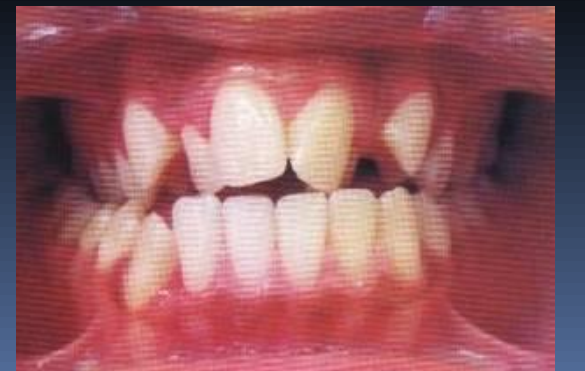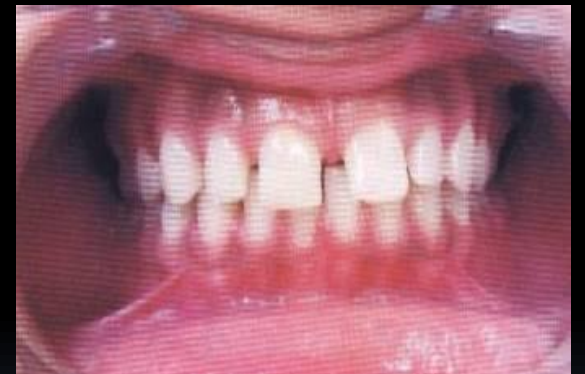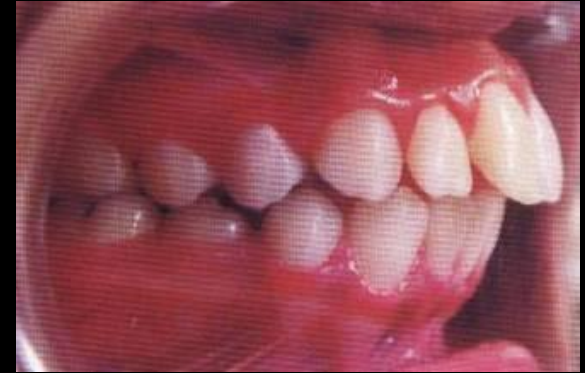- **Extra oral**
 - Lip posture
 - Lip separation
 - Mandibular movement
 - Upward and backward with tongue moving forward
 - Speech
 - Speech disorder
 - Facial form
 - Increased Anterior face height

- **Intraoral**

- **Tongue posture**
 - Downward and forward

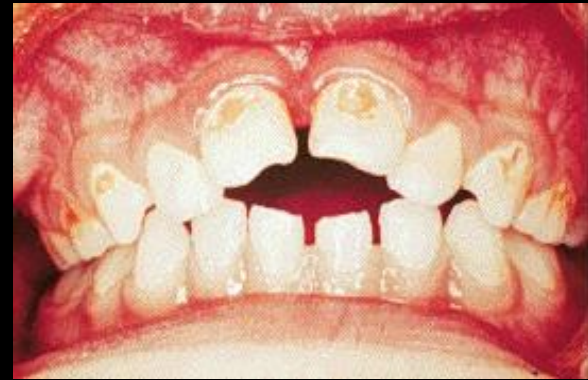

- **Malocclusion**
 - In relation to maxilla
 - Increased overjet
 - Generalized spacing
 - Maxillary constriction



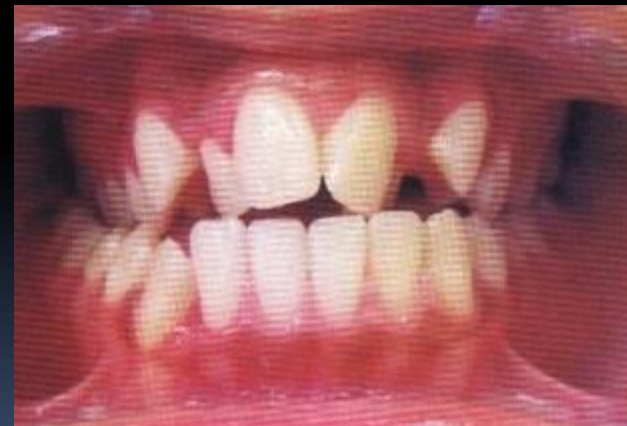□ In relation to mandible

- Retroclination or proclination of mandibular teeth




□ In relation to Intermaxillary relationship

- Ant. Or post. Openbite
- Posterior crossbite





Treatment

- Myofunctional therapy
 - Speech therapy
 - Mechano therapy
 - Correction of malocclusion
 - Surgical treatment
- 



- **Speech therapy**

- Training of correct position of tongue
- Articulation of speech
- Repetition of words with 'S' sound


Not indicated before 8 yrs





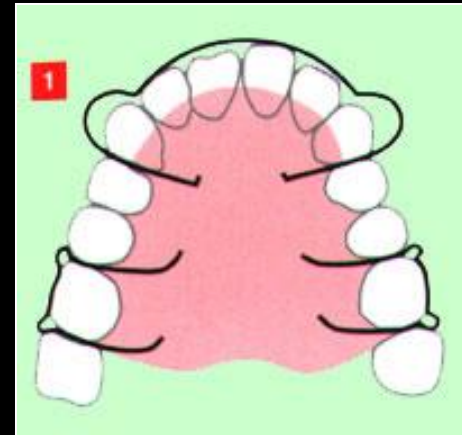- **Mechano therapy**

- Purpose

- Reeducation of tongue position
 - Maintaining tongue in the confines of dentition
 - Maintaining the interocclusal distance
 - Prevention of over eruption and narrowing of maxillary buccal segment
- 

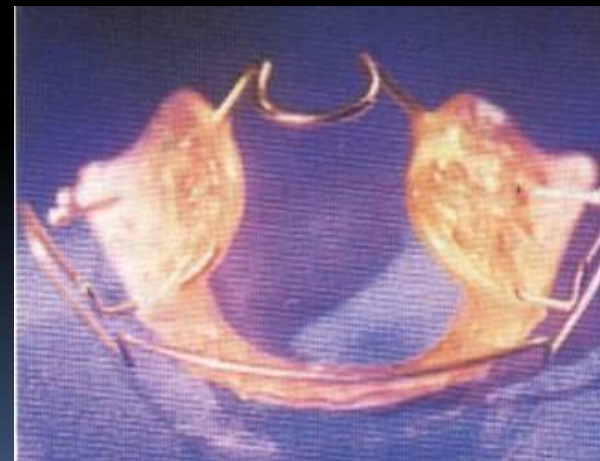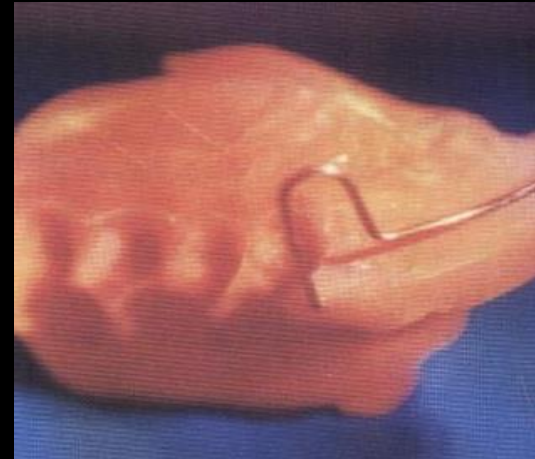
Appliance therapy

- Removable appliance
 - Hawley's appliance
 - Modifications
 - Active labial bow
 - Addition of palatal crib
 - Oral screen and vestibular screen



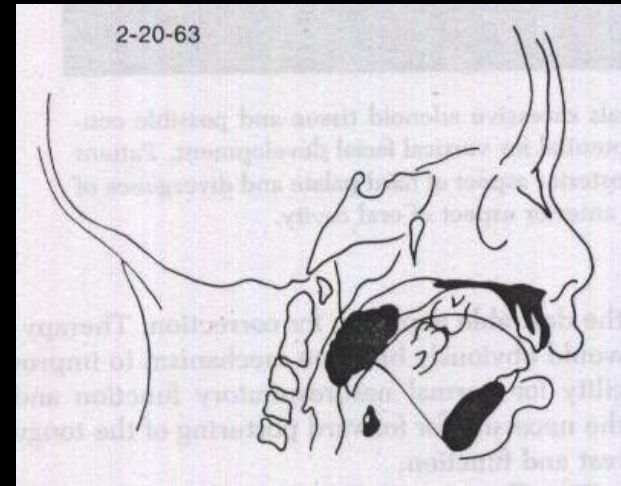
- Treatment with myofunctional appliance

- Promote lip closure
- Enlarge oral cavity
- Move incisors
- Improve relation among jaws, tongue, Dentition and soft tissue
- E. g
 - Activator
 - Bionator

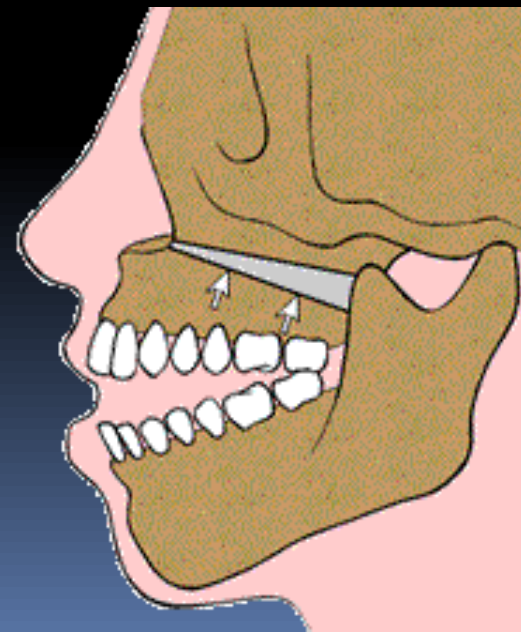


- **Surgical treatment**

- Removal of tonsils



- Correction of skeletal malformation






Mouth breathing



- Definition:



- **Sassouni (1971)** - Habitual respiration through the mouth instead of the nose
 - **Merle (1980)** - Suggested the term oro - nasal breathing instead of mouth breathing
- 

Classification

- Finn (1987)
 - Anatomical
 - Short upper lip
 - Obstructive
 - Obstruction in nasal passage
 - Habitual

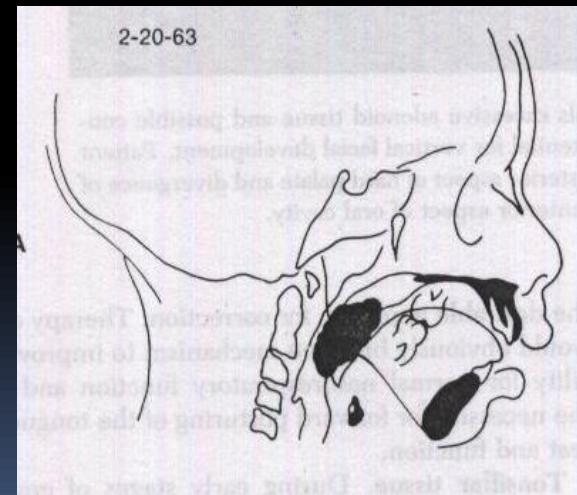
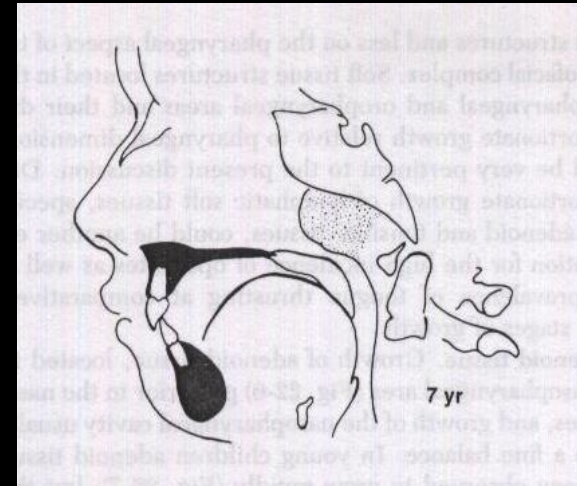
Etiology

- **Developmental and morphologic anomalies interfering nasal breathing**
 - Asymmetry of face
 - Hereditary
 - **Size of nasal passage**
 - **Position of nasal septum**
 - Abnormal development of nasal cavity, Nasal turbinates
 - Abnormally short upper lip
 - Under developed or abnormal facial musculature

- 
- Partial obstruction due to:
 - Deviated nasal septum – Birth injury
 - Localized benign tumor
 - Narrow maxilla
 - Traumatic injuries to nasal cavity
- 

■ Infection and inflammation

- Ch. Inflammation of nasal mucosa
- Ch. Allergic stomatitis
- Ch. Atrophic rhinitis
- Enlarged adenoids, tonsils
- Nasal polyps

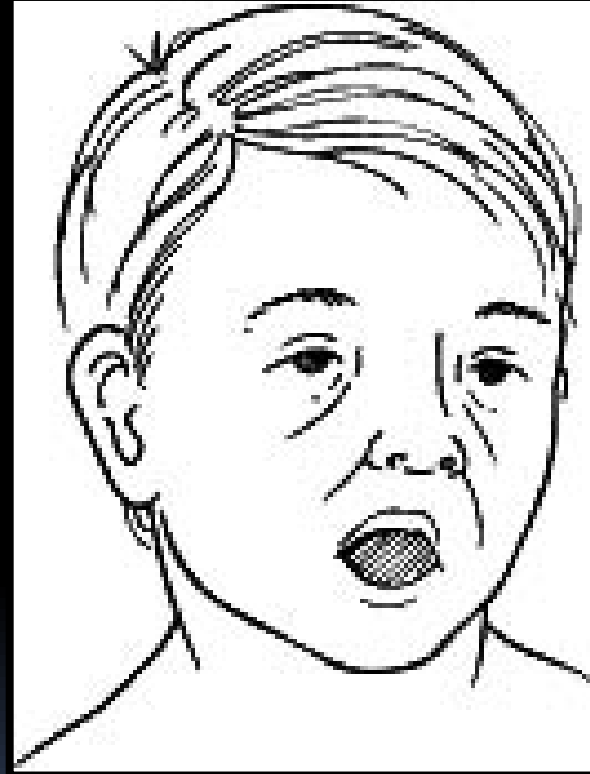

Clinical features

- **General features**
 - Pulmonary development
 - Pigeon chest
 - Lubrication of esophagus
 - No mucous gland
 - Dry - Esophagitis
 - Blood gas constituent
 - 20 % more CO₂

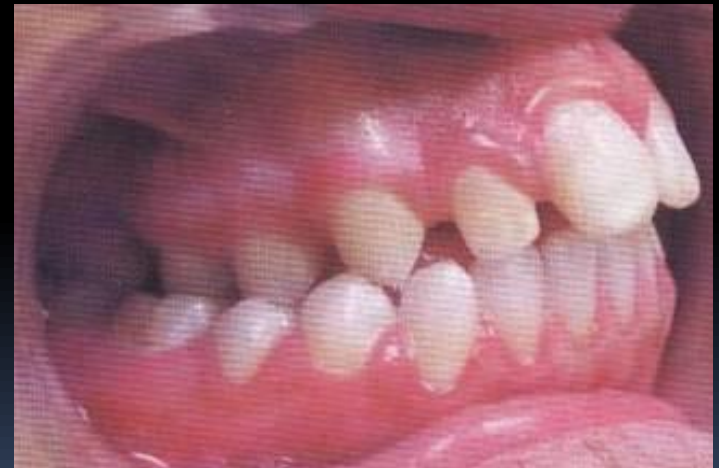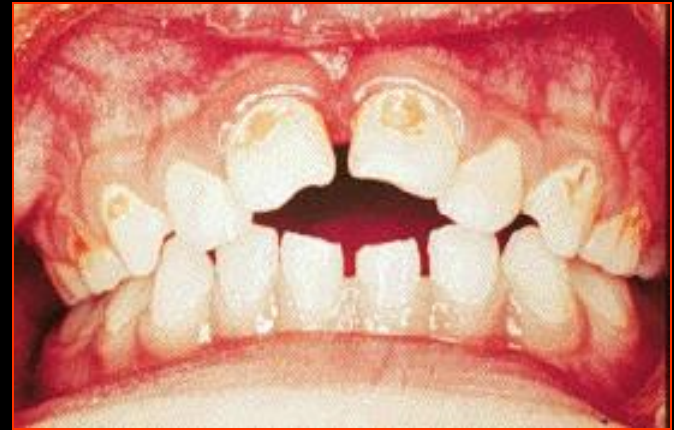
■ Adenoid facies

- Long narrow face
- Narrow nose and nasal passage
- Nose tipped superiorly
- Flat nasal bridge
- Flaccid lips
- Short upper lip
- Collapsed buccal segment of maxilla
- High palatal vault
- Dolichofacial pattern
- Expressionless face

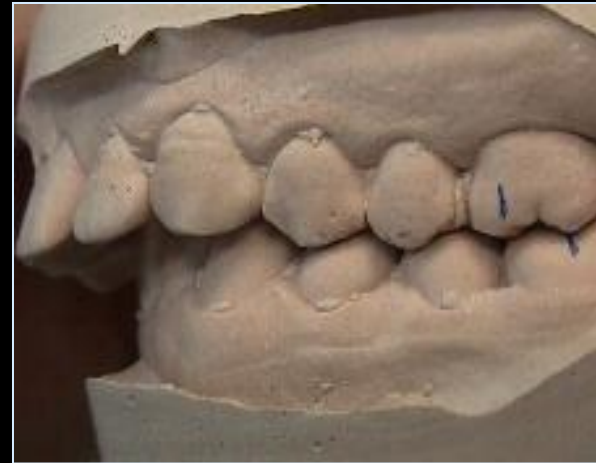

- Dental effect:

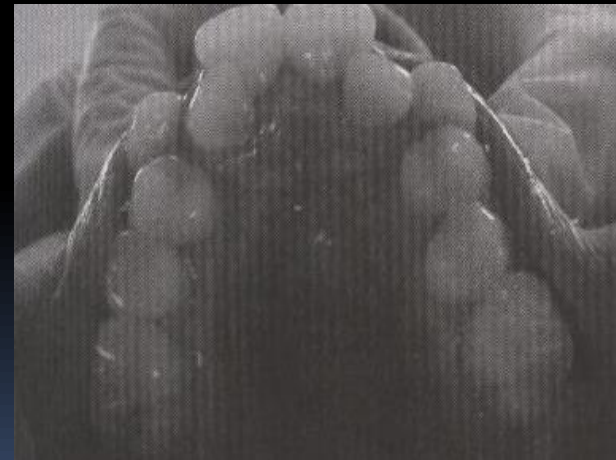
- Protrusion with spacing of upper incisors
- Decreased overbite
- Openbite
- Lower tongue position
- Posterior cross bite



- Increased overjet

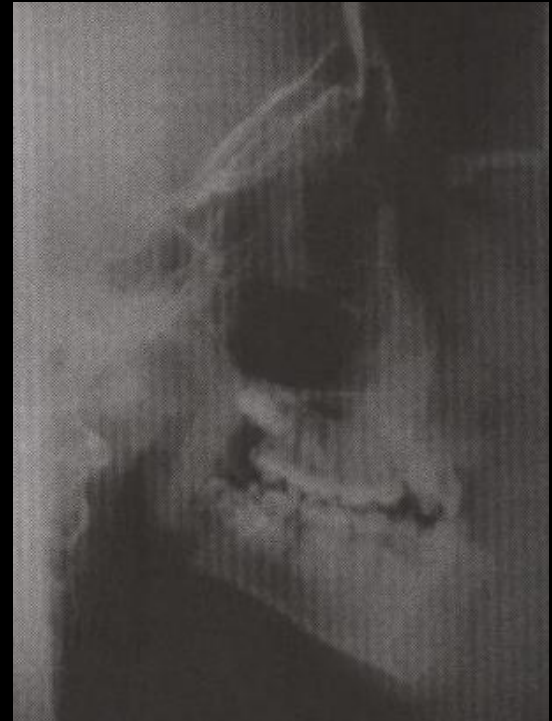
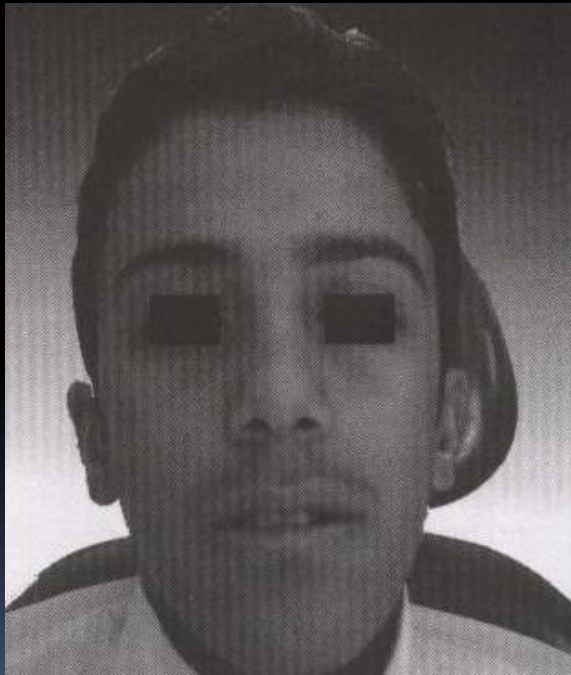
- Constricted maxillary arch



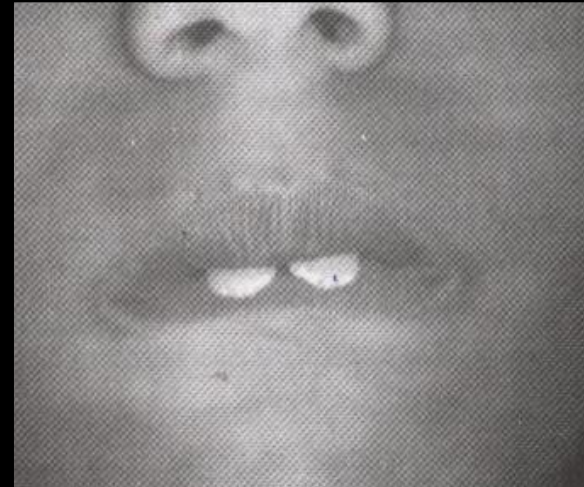- Narrow palate and cranial vault

- Narrow long face



■ Lips

- Incompetent upper lip
- Everted, heavy lower lips
- Voluminous curled lower lips
- Gummy smile



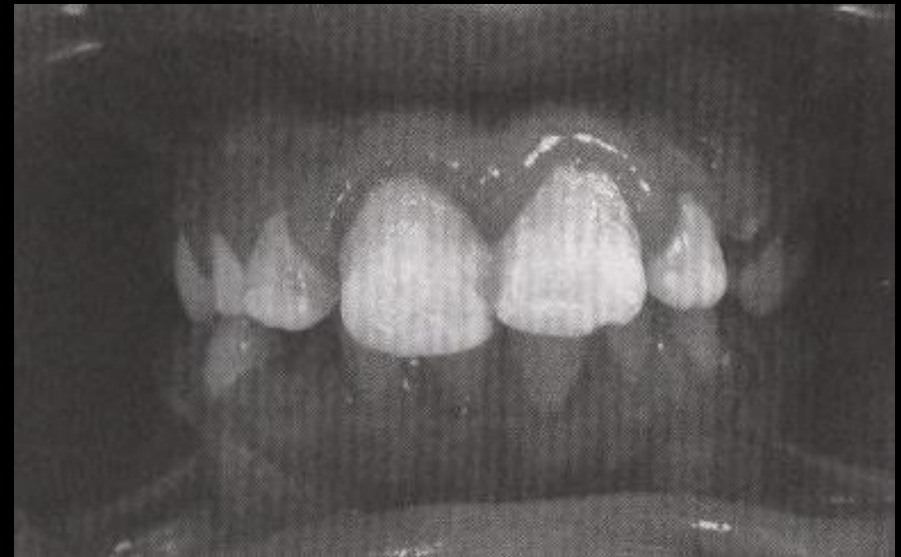■ External nares

- Slit like external nares with narrow nose
- Atrophied nasal mucosa

■ Gingiva


- Ch. Keratinized marginal gingivitis
- Classic rolled margin and enlarged interdental papilla
- Heavy plaque deposition
- Salivary flow and bacterial overgrowth

- Periodontal disease
 - Pocket formation and interproximal bone loss





- **Other effects**

- Narrow maxillary sinus and nasal cavity
 - Turbinates- Swollen and engorged
 - Atrophic nasal mucosa
 - Speech- Nasal tone
 - Infection of Lymphoid tissue
 - Otitis media
 - Dull sense of smell
 - Loss of taste
- 



Diagnosis

- History
 - Lip apart posture
 - Tonsillitis, allergic rhinitis, otitis media



- Examination

- Observation of breathing
- Lip posture
- Nasal orifices


- Clinical test

- Mirror test
- Butterfly test
- Water holding test
- Inductive plethysmography
 - Airflow through nose and mouth
- cephalometrics






- **Treatment consideration:**

- Age ; maturity of the child
 - E.N.T. examination; determine whether conditions requiring treatment are present in tonsils adenoids or nasal septum.
 - Correction time
 - Mix dentition
- 



Treatment

- Symptomatic relief
 - Gingival coating
 - Periodontal consideration
 - Prophylaxis
- 




- **Elimination of cause**

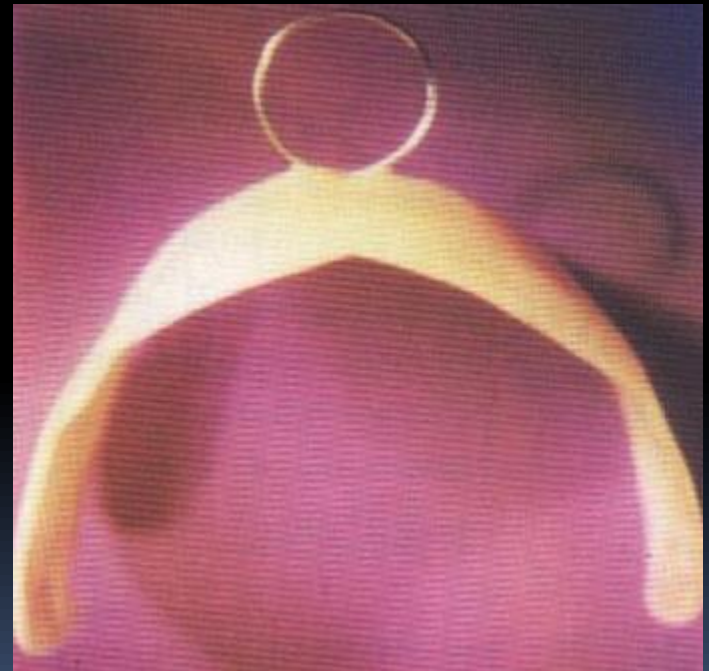
- Removal of nasal or pharyngeal obstruction

- **Interception of habit**

- Exercises

- Physical – deep inhalation exercise
 - Lip
 - Upper lip extension exercise
 - Upper, lower lip combined exercise
 - Playing wind pipe
 - Disc holding exercise
- 

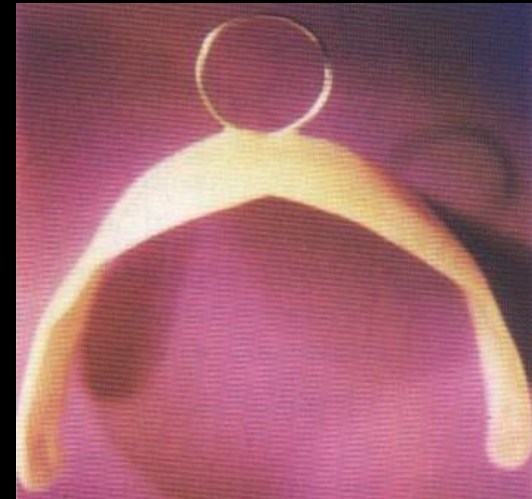- Maxillothorax myotherapy
 - Macaray activator
 - Oral screen



- Correction of malocclusion

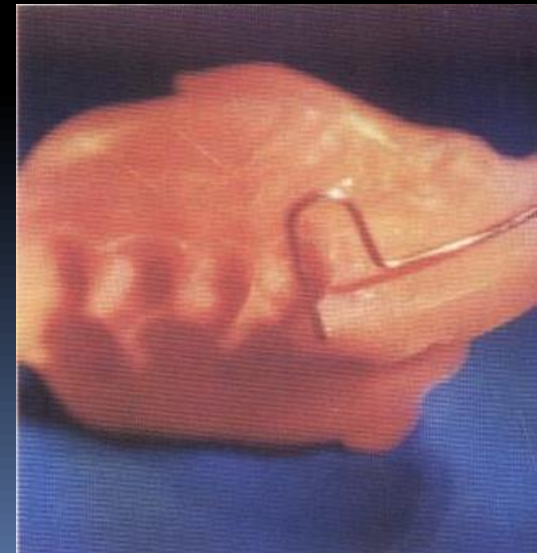
- CI I

- Oral screen



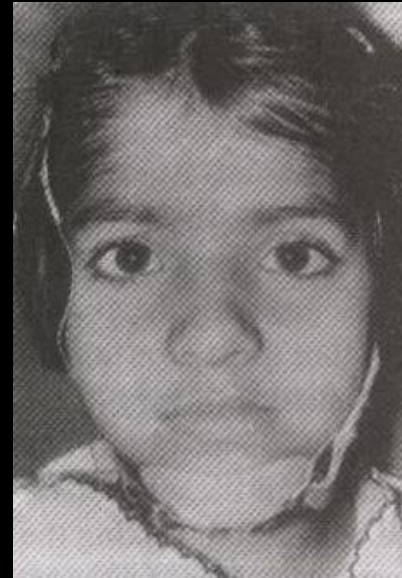- CI II Div-1

- Noncrowded dentition (5-9 yr) – Monobloc



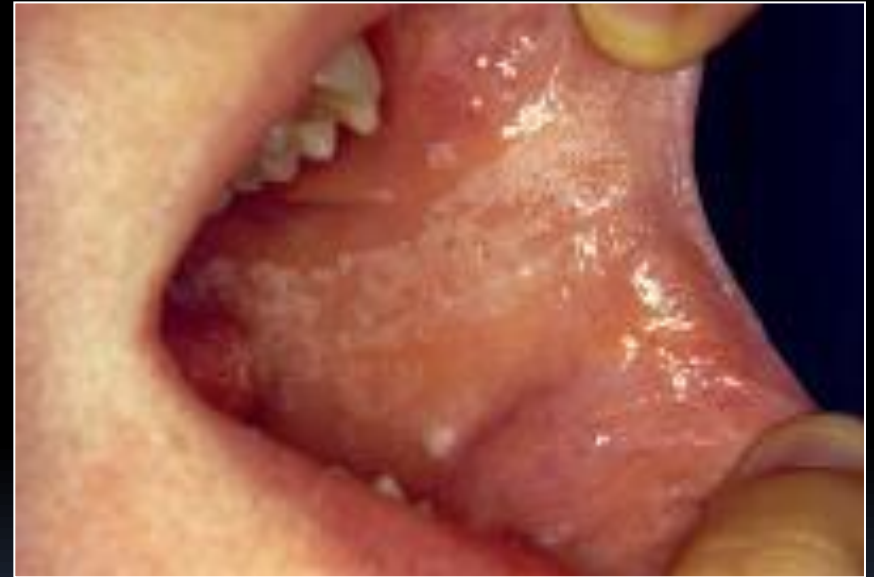□ CI III

- Interceptive chin cap



Cheek biting

- **Definition-**
 - keeping or biting the cheek muscles in between the upper and lower posterior teeth
- **Clinical features**
 - Ulcers at the level of occlusal line
 - Open bite
 - Tooth malposition in buccal segment



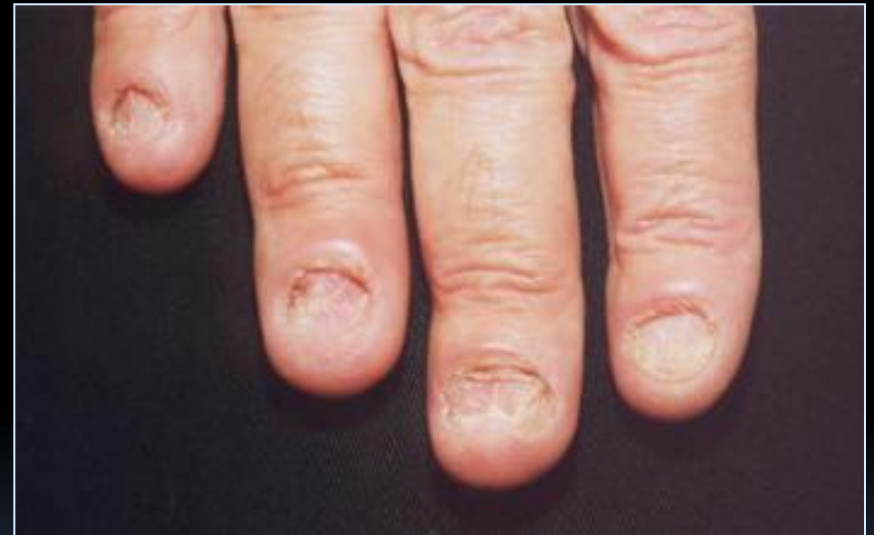Treatment

- Vestibular screen
- Reminders



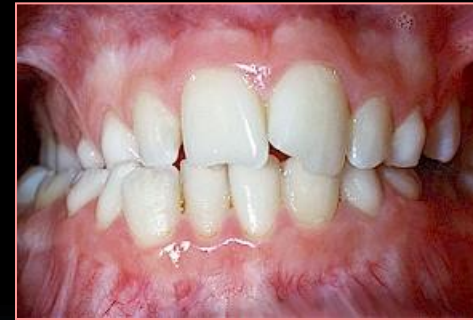Nail biting

- Sign of stressful condition
- Age of occurrence
 - Before 3 yr- absent
 - 4-6 yr- sharp rise in incidence
 - 7-10 yr- constant level
 - Adolescence- sharp rise
- Etiology
 - Emotional problem
 - Stressful condition



CLINICAL FEATURES

- **Nail**
 - Inflammation of nail beds and nail
 - Irregular nail margins
- **Dental effect**
 - Crowding
 - Rotation
 - Attrition of incisal edges of incisors



Management

- Avoidance of punitive methods
- Mild case- No treatment
- Care for emotional condition
- Encouragement of stress relieving activities
- Nail polish, light cotton mittens as reminder
- Bitter or sour chemical over the finger
 - E.g. : Foul smelling Quinine, Asofoctine, Pepper , Femite etc

Bruxism

- **Definitions**

- Habitual grinding of teeth when the individual is not chewing or swallowing- Ramfjord
- Nonfunctional contact of teeth which may include clenching, gnashing and tapping of teeth
- Nonfunctional movement of mandible with or without an audible sound occurring during the day or night



- **Classification**

- Bruxism associated with stressful event
- No such association (Hereditary)

- **Types**

- **Day time bruxism / Diurnal**

- Conscious or subconscious grinding
- Along with parafunctional habits
- Silent


- **Night time / Nocturnal**

- Subconscious grinding in rhythmic pattern of masseter
- 



Etiology

- Local theory
 - Reaction to an occlusal interference
 - High restoration, irritating dental condition
 - Disturbed afferent impulses from PD


 - CNS
 - Cortical lesions, cerebral palsy, mental retardation
- 



- Systemic

- Intestinal parasites – GI disturbance

Ch. Abd


- Nutritional deficiencies - Mg deficiency distress
 - Enzymatic distress
 - Allergies - Food
 - Endocrine disorder
- 



- **Psychological theory**

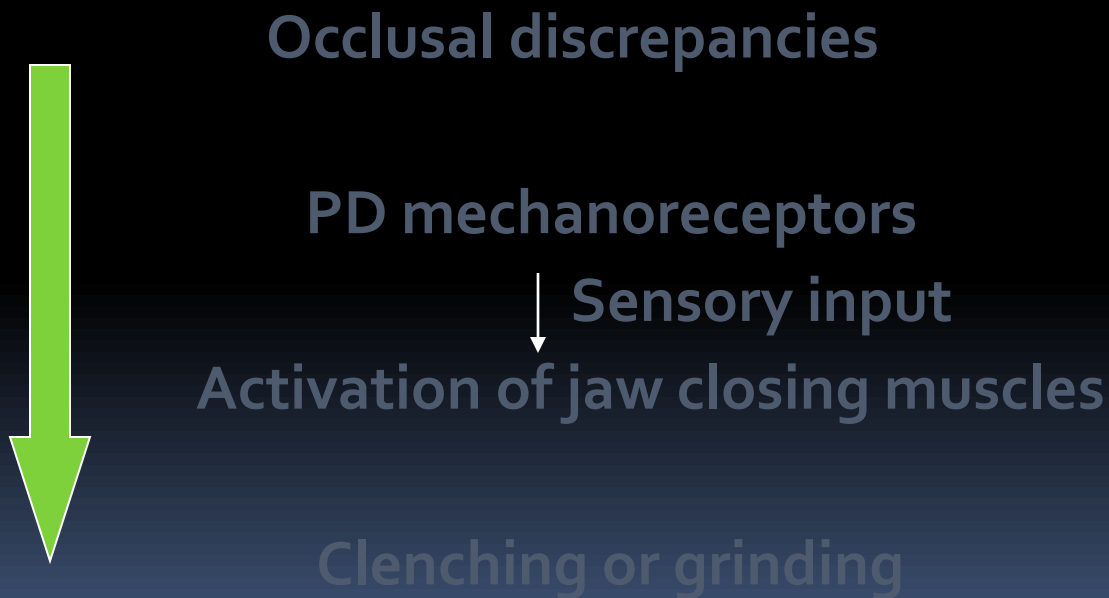
- Associated with feeling of anger, aggregation
- Stress
- Emotional status – inability to express the emotion

- **Other causes**

- Genetics
 - Occupational factors
 - Enthusiastic student , compulsive overachiever
 - Competition sports
- 

Causal hypothesis

- Malocclusion can initiate and maintain forceful grinding or clenching
 - Mechanism





- **Counterview (Christensen)**

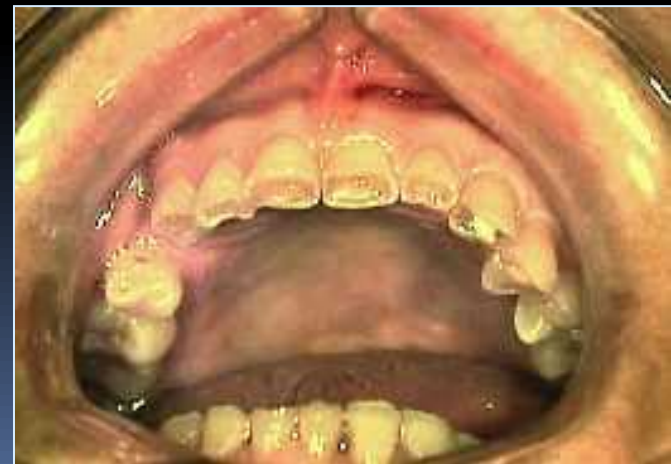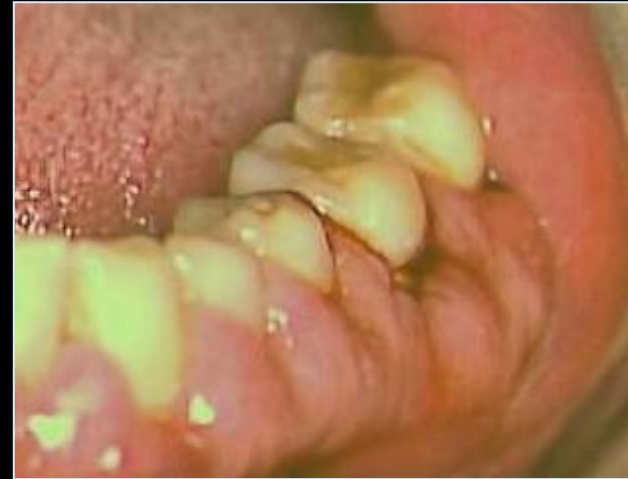- Removal of occlusal interference
 - Continued bruxism
- Nocturnal bruxism
 - Protective mechanoreceptor function cancelled
 - Continuation of clenching

Correlation between malocclusion and bruxism is not consistent



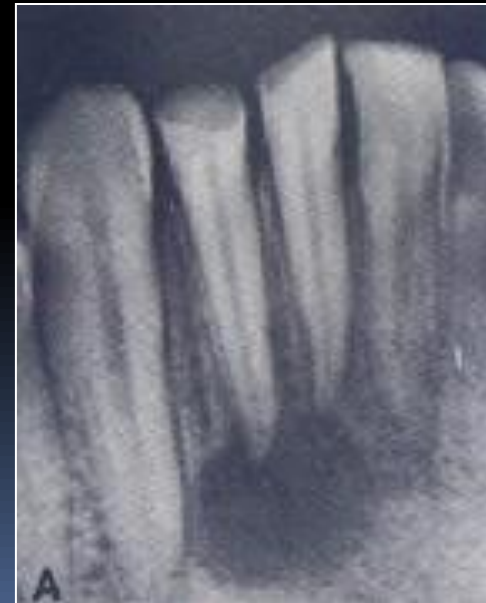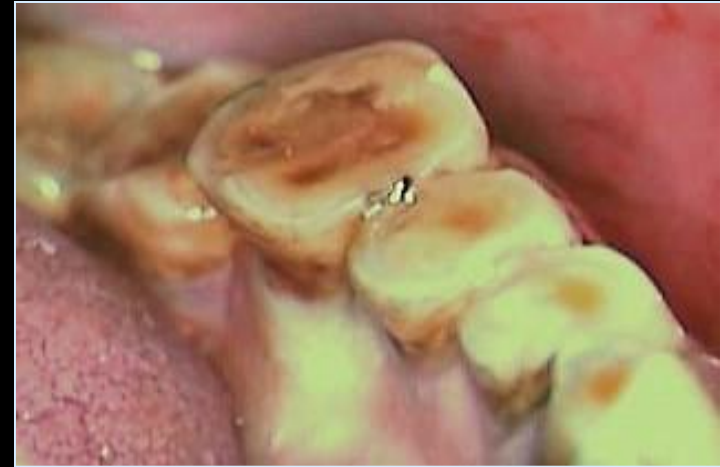Bruxism

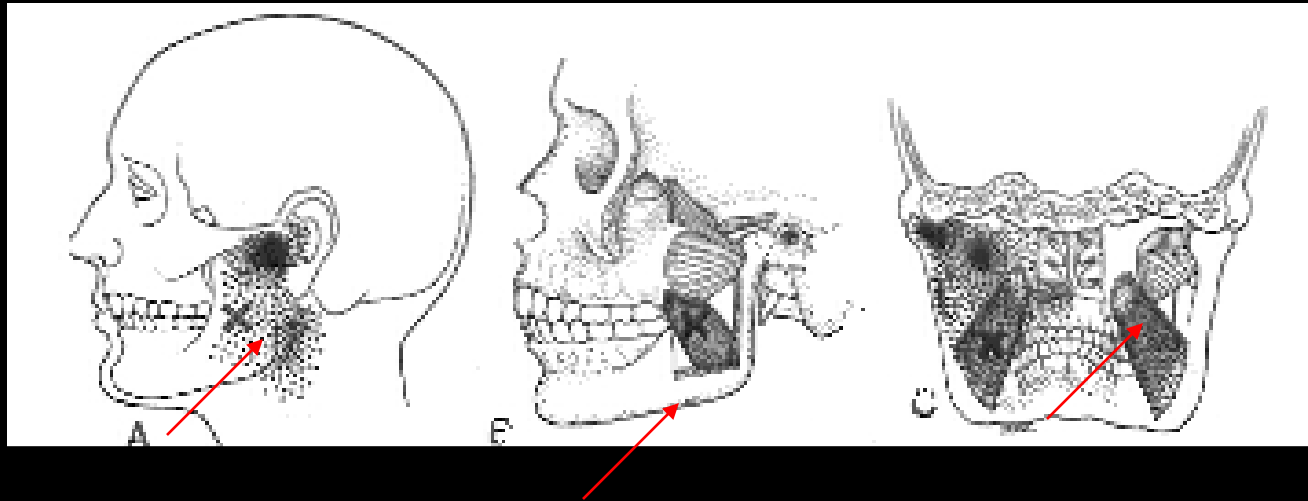
- Indicators
 - Presence of dental wear / Attrition
 - Bruxofacet
 - Grinding or clenching



Clinical manifestation

- Occlusal trauma
 - mobility
 - Morning time
- Tooth structure
 - Nonfunctional occlusal wear
 - Sensitivity
 - Atypical shiny wear facet with sharp edges
 - Pulpal exposure
 - # crown, restoration





- Muscular tenderness
 - Lateral pterygoid, masseter on palpation
 - Fatigue on waking
 - Hypertrophy of masseter
- TMJ disturbances
 - Crepitation , clicking ,
 - Restriction of mand. Movement
 - Deviation of chin
 - Pain – Dull , unilateral



- **Headache**

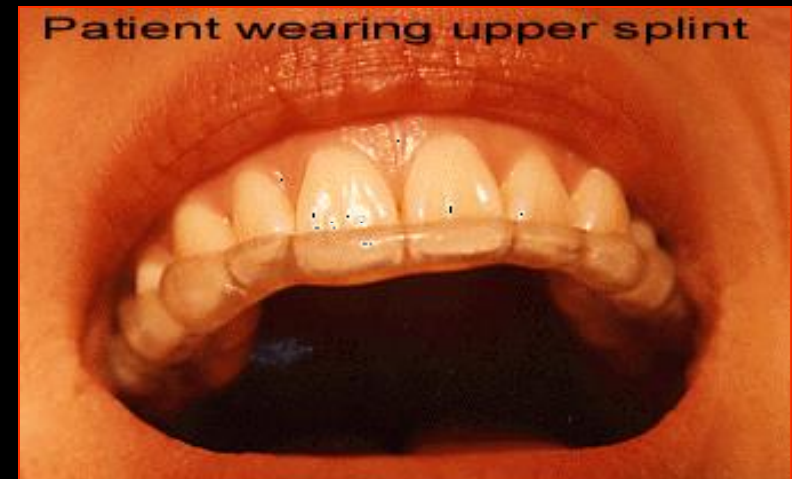
- Muscular contraction type

- **Other signs and symptoms**

- Sounds- Grinding and tapping
 - Soft tissue trauma
 - Small ulceration or ridging on buccal mucosa opposite the molar teeth
- 

Treatment

- **Occlusal adjustment**
 - Disappearance of habitual grinding
 - Coronoplasty
 - High point correction
- **Occlusal splints (Night guard)**
 - Vulcanite splint to cover occlusal surfaces
 - Reduction of increased muscle tone
 - TMJ appliance
 - Prefabricated intra oral appliance for TMJ disorder

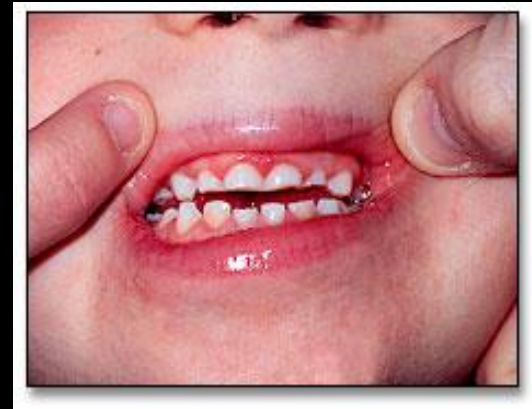

- Restorative

- Severe abrasion
 - Pulp therapy
 - Stainless steel crown

- Psychotherapy

- Counseling
 - Tension relief
 - Habit awareness -
Increase voluntary control






- **Relaxing training**

- Tensing and relaxing exercise
 - Voluntary relaxation
- Hypnosis
- Behavior Conditioning
- Physical therapy
 - Musculoskeletal pain and stiffness

- **Drugs**

- Placebo
 - Vapocoolant – Ethyl chloride for pain -TMJ
 - Local anesthetics - TMJ
 - Tranquilizers, sedatives, muscle relaxants
 - Diazepam – Anxiety and alteration of sleep arousal
 - Tricyclic antidepressants- Reduce REM
- 



- **Biofeedback**

- Positive feedback for Learning of tension reduction

- **Electrical method**

- Electro galvanic stimulation
 - Muscle relaxation

- **Acupuncture**



- **Orthodontic correction**

- Cl II,III, Ant. Openbite, Crossbite



THANK YOU

