

ENAMEL

DEPARTMENT OF ORAL AND
MAXILLOFACIAL PATHOLOGY &
ORAL MICROBIOLOGY

Study of enamel includes...

Physical characteristics

Chemical properties

Structure

Rods

Submicroscopic structure

Striations

\directions of rods

Hunter-schreger bands

Incremental lines of Retzius

Surface structures

Enamel cuticle

Enamel lamellae

Enamel tufts

Dentino-enamel junction

Odontoblast processes and enamel spindles

Development

Epithelial enamel organ

Outer enamel epithelium

Stellate reticulum

Stratum intermedium

Inner enamel epithelium

Cervical loop

Life cycle of ameloblasts

1. Morphogenic
2. Organizing
3. Formative
4. Maturative
5. Protective
6. Desmolytic

Amelogenesis

Formation of enamel matrix

Development of tomes process

Distal terminal bars

Ameloblasts covering maturing enamel

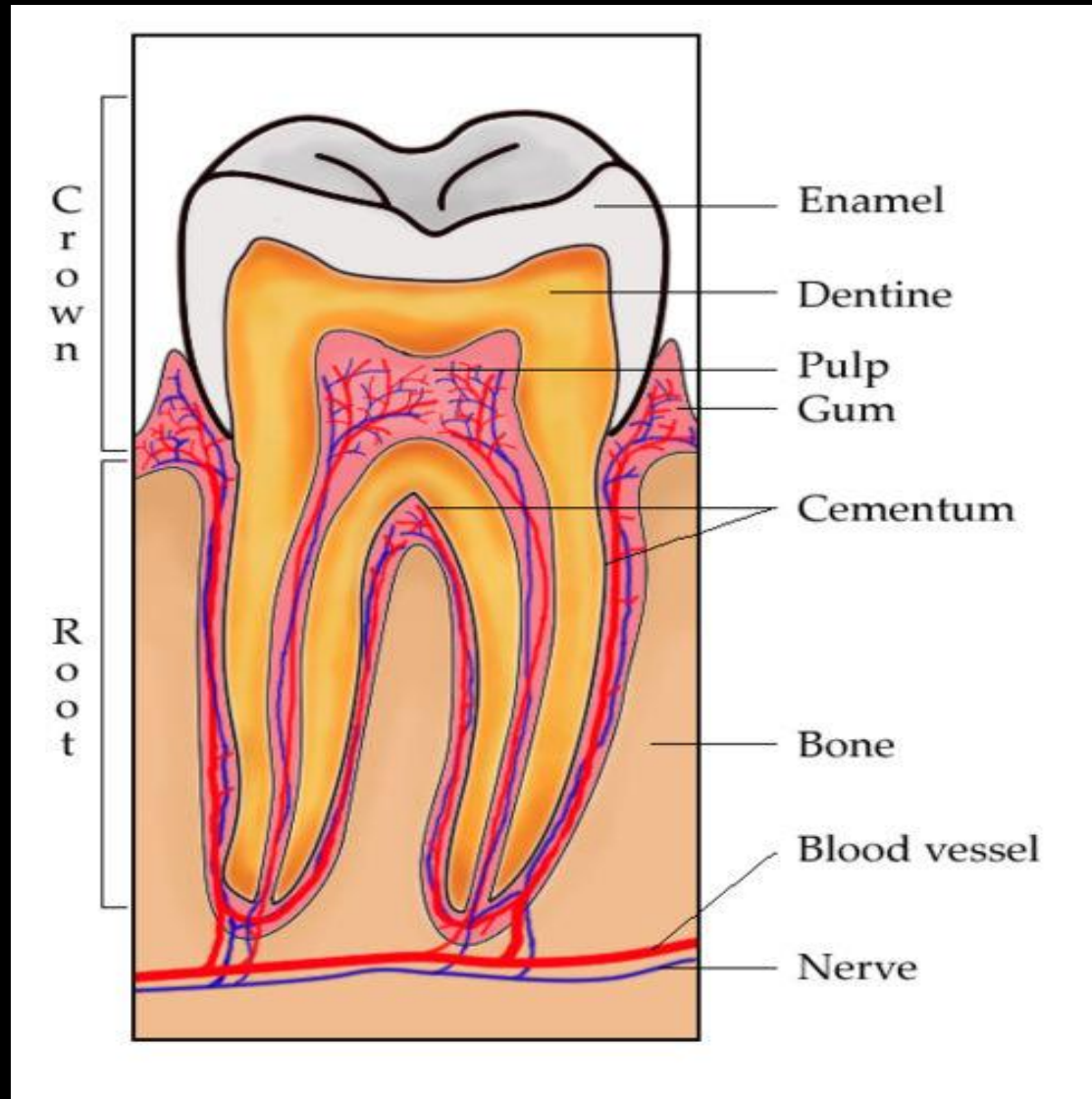
Mineralization and maturation of the enamel matrix

Age changes

Clinical considerations

Enamel is the hardest tissue in the human body. It is the only *ectodermal derivative* (epithelially derived) of the tooth.

It is *highly mineralized* structure covering anatomic crown of the tooth. It forms a protective covering of variable thickness over entire surface of crown.



CHEMICAL PROPERTIES:

Inorganic - 96%

Minerals (inorganic content)

Calcium phosphate

Hydroxyapatite

Ions... strontium, magnesium,
lead, fluoride.

Organic - 4%

TRAP-tyrosine rich amelogenin
polypeptide

Non amelogenin protein
(tuftelin, amelin, enamelin)

PHYSICAL CHARACTERISTICS :

1. Density

3.0 to 2.84gm/ml

2. Thickness

2.5mm (thickest) Over cusp of molar

2.0 mm over incisal edge

Knife edge thickness at cervical region

3. Color

Depends on thickness

Bluish white or grayish and yellowish white at thin areas reflecting the color of underlying dentin.

4. Hardness

5 to 8 Mohs unit

It is the hardest structure in the body.

Peripheral region are more harder.

This variation depends on degree of calcification & prism orientation

Distribution of metallic ions

5. Tensile strength:

11,000 psi
rigid structure

6. Modulus of elasticity:

19 x 10⁶ psi
Brittle structure

7. Solubility:

Dissolves in acidic media.

8. Permeability

Enamel is selective permeable.

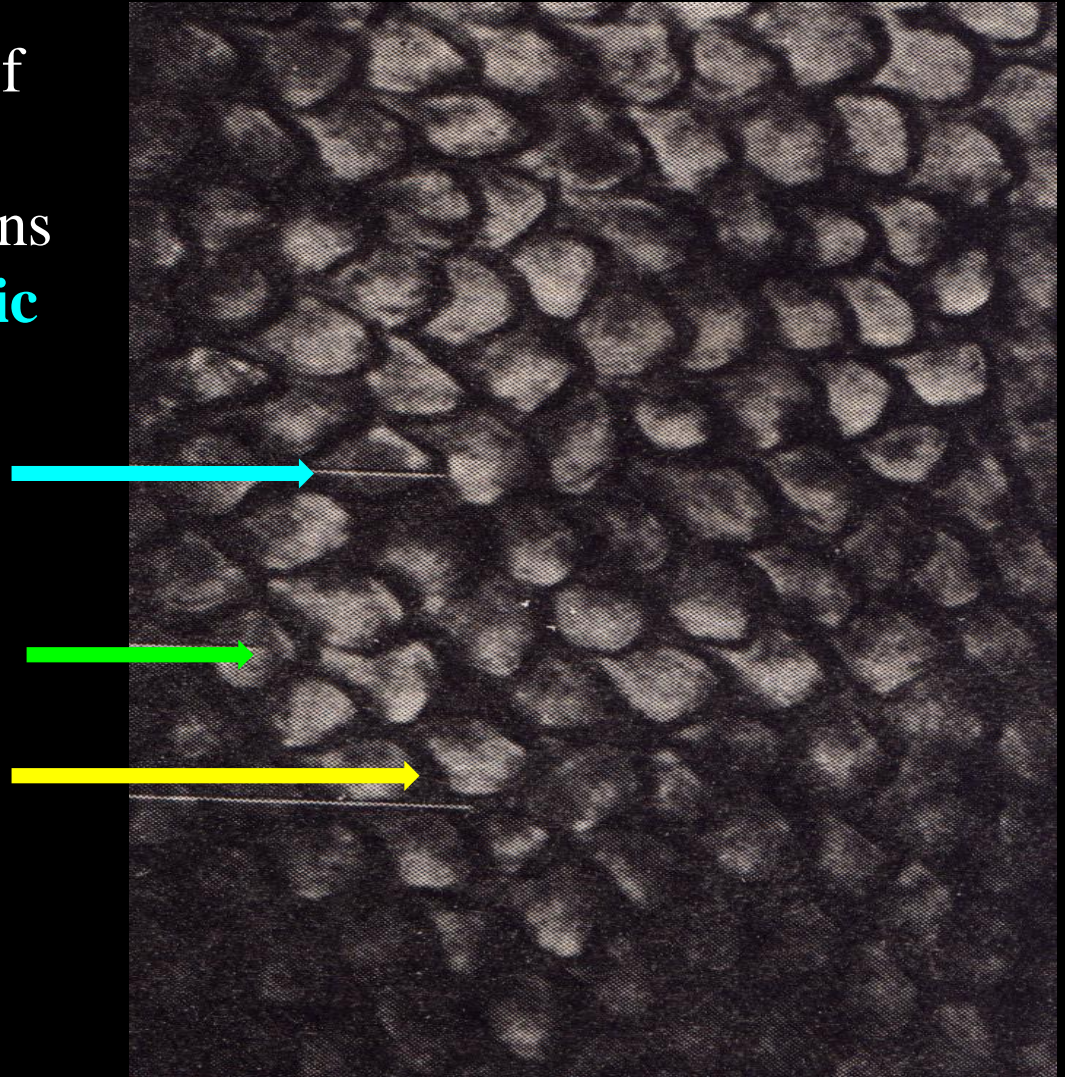
Route of passage occurs via rod sheath, enamel lamellae and enamel tufts which are rich in organic content

9. Specific gravity: 2.8

10. Translucency: semi translucent.

RODS

The enamel is composed of **rods or prisms**, **rod sheaths** and in some regions a cementing **interprismatic or interrod substance**.



The prisms are cylindrical in longitudinal section, therefore the term rods is appropriate.


No.: 5 million in lower lateral incisor to
12 million in upper 1st molar.

Length: They have **tortuous (Wavy)** course from DEJ. Therefore, greater than thickness of enamel. The rods located in the cusps, the thickest part of the enamel, are longer than those at the cervical areas of the teeth.

Diameter: 4 um in light microscopy. It varies since outer surface of enamel is greater than inner surface. It increases from DEJ to outer enamel surface by a ratio of 1:2.

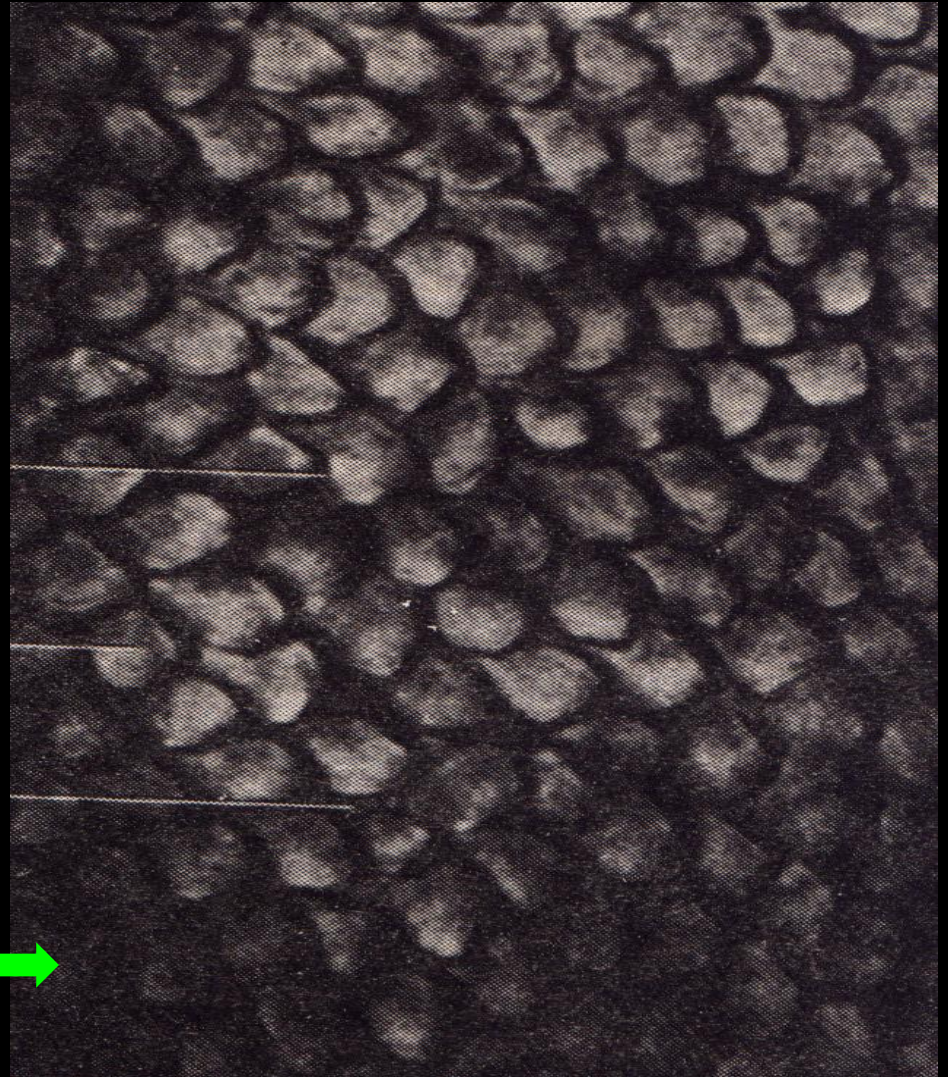
The rods have a clear crystalline appearance, permitting light to pass through them.

In cross section : Fish Scale appearance



Fish Scale

Enamel Rods



SUBMICROSCOPIC STRUCTURE

Shape of rod: key hole/paddle shaped prisms

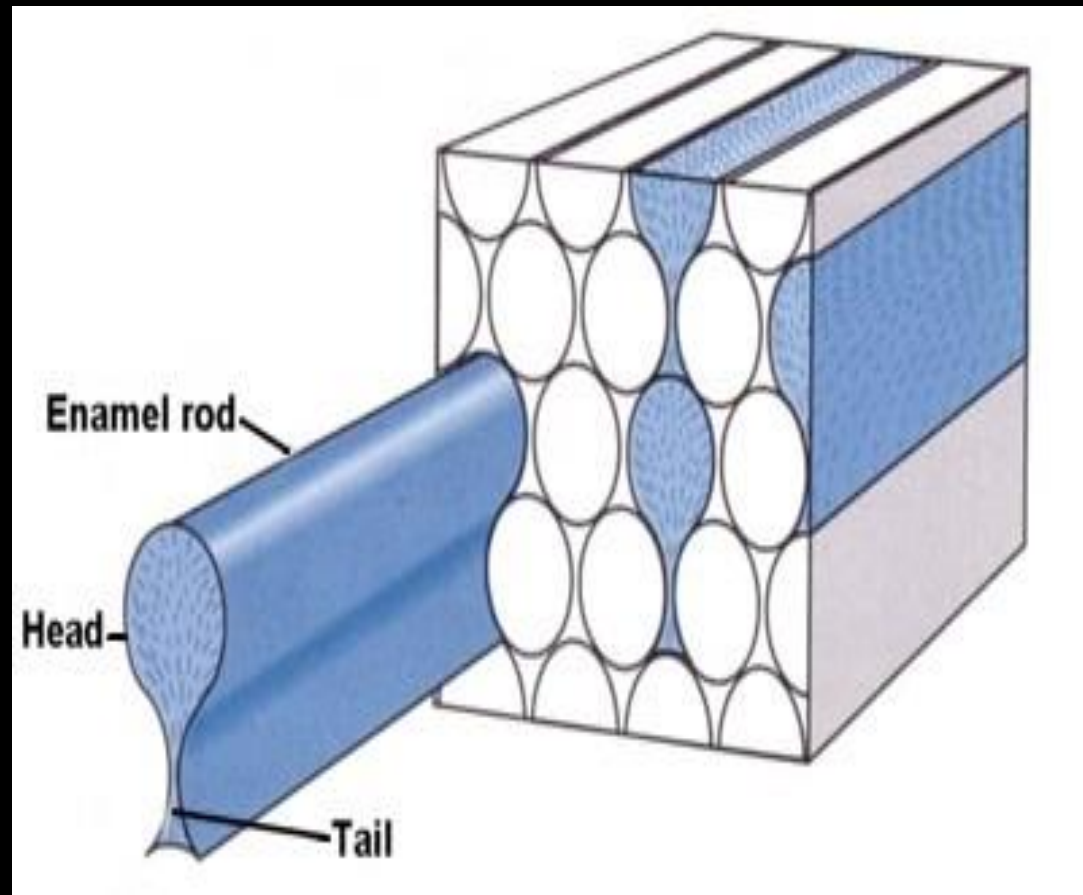
When cut longitudinally, sections pass through heads of one row of rods and the tails of an adjacent row. This produces an appearance of rods separated by interrod substance.

Measurement:

5 μm – breadth

9 μm – length

Bodies of rods – near occlusal /incisal surface and tails point cervically.



Hydroxyapatite crystals

Measurements:


Length : 0.5 to 1 μ

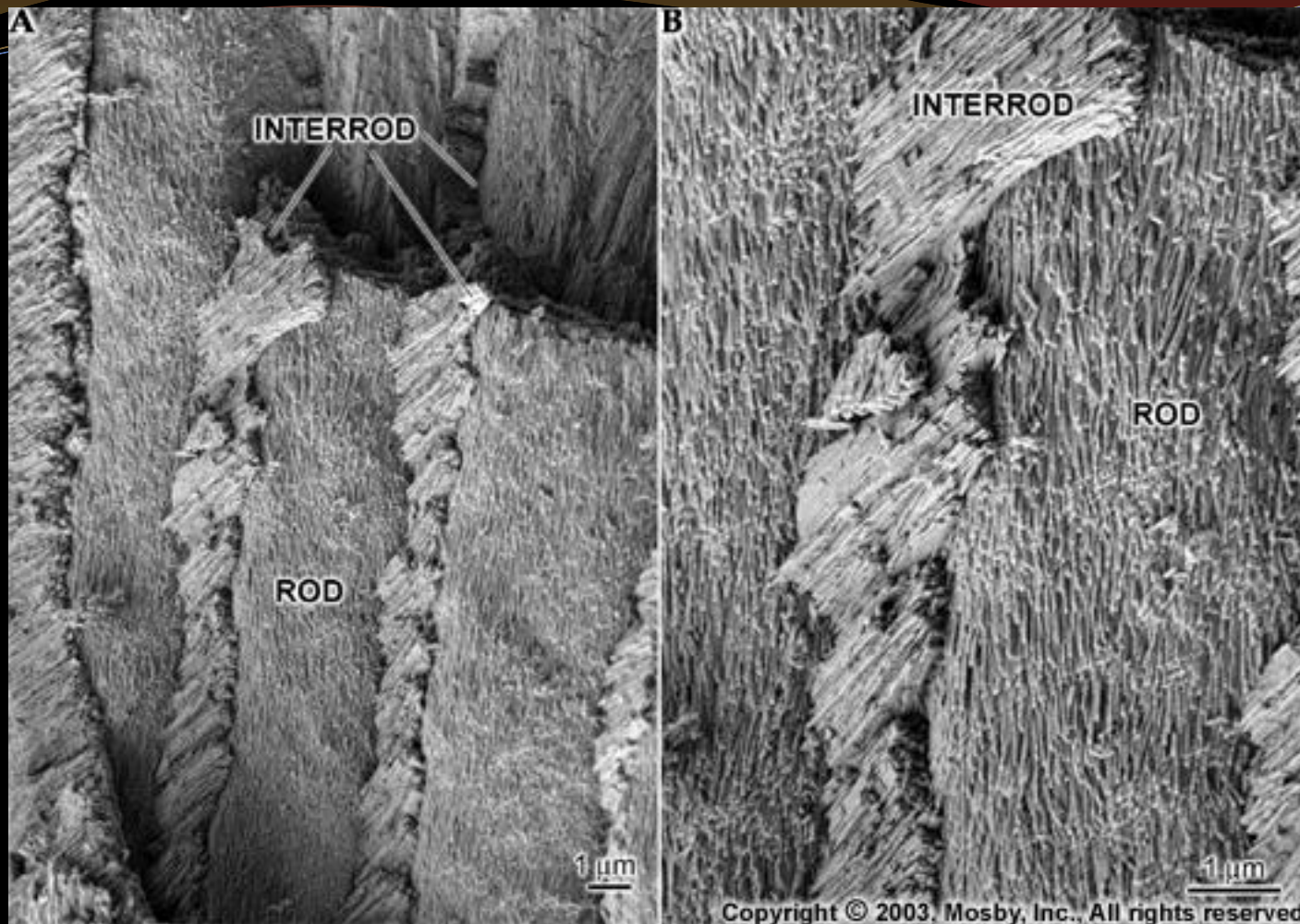
Thickness : 30 nm (300 Å)

Width : 90 nm


Arrangement:

Parallel to long axis of rods in bodies or heads of prisms and deviate about 65 degrees from this axis as they fan out into tails of prisms.



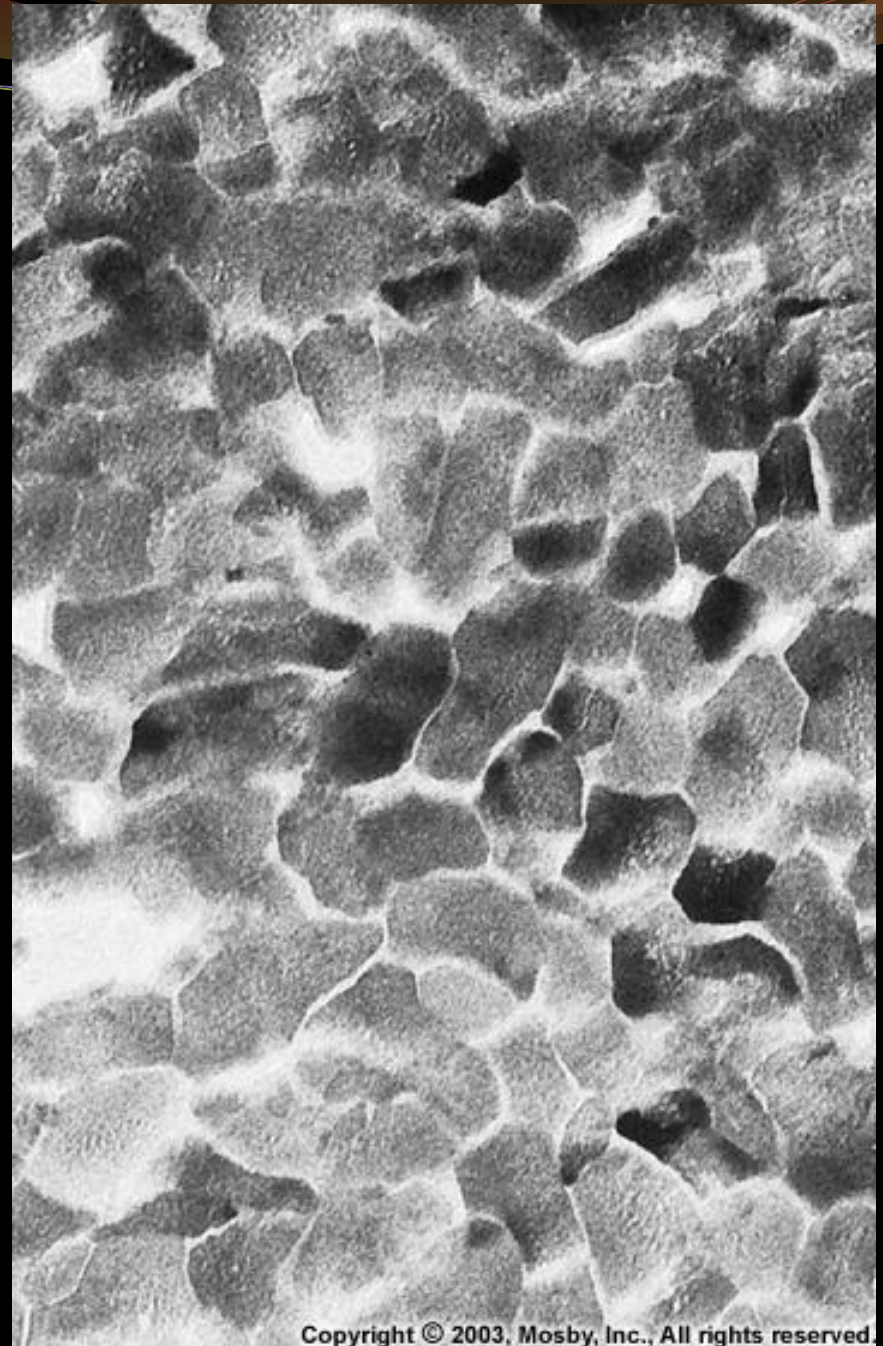


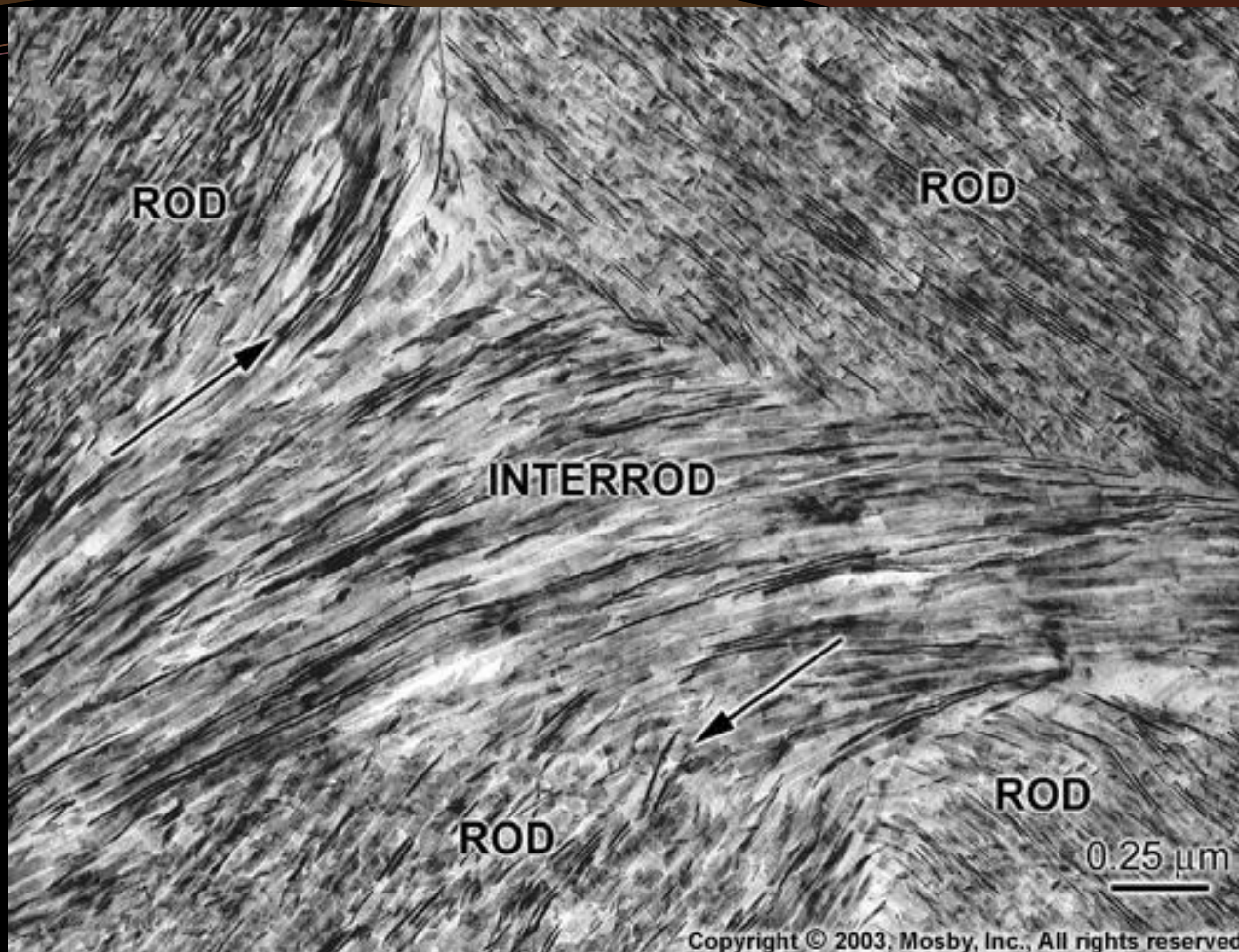
A and B, High-resolution scanning electron microscope images showing that crystals in rod and interrod enamel are similar in structure but diverge in orientation.



Cross-sectional profiles of **(A)** recently formed, secretory stage enamel crystals and **(B)** older ones from the maturation stage. Initially the crystals are thin; as they grow in thickness and width, their hexagonal contour becomes apparent. **B**, The linear patterns seen in older crystals are a reflection of their crystalline lattice.

Electron micrograph of mature enamel crystals. The outline is irregular as they press against each other.





Interrod partition associated with four rod profiles. At certain sites (*arrows, zone of confluence*) crystals from interrod enamel enter the rod.

STRIATIONS

Enamel rod is built up of segments of uniform length of about 4 μm , separated by dark lines that give it a striated appearance


More visible by the action of mild acids.

Appearance is because of formation of enamel matrix in rhythmic manner.

More pronounced in hypo calcified areas.



Incremental
lines



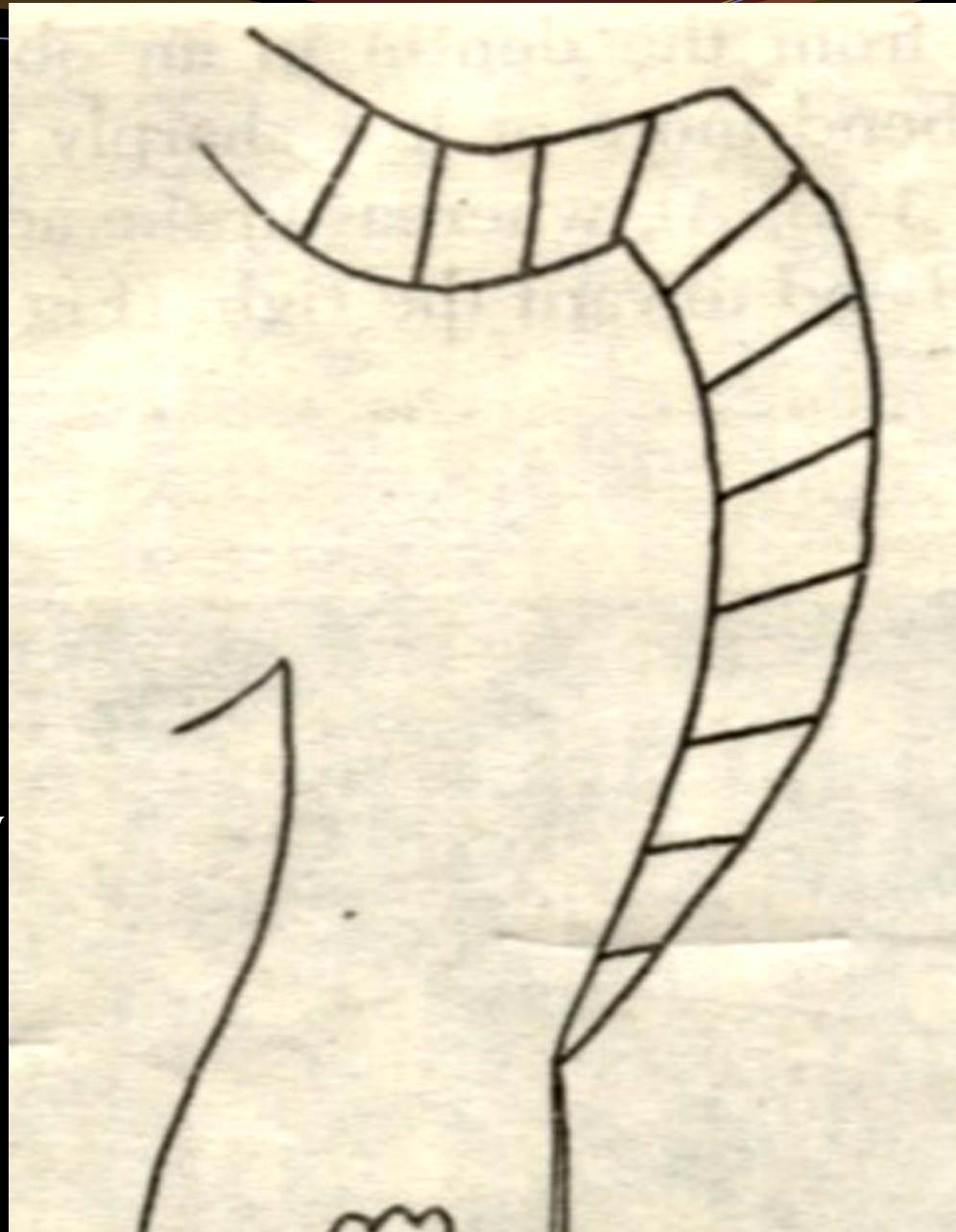Cross
Striation

DIRECTION OF RODS

Rods are oriented at right angles to the dentinal surface.

In the cervical and central parts of crown of the **deciduous teeth**, they are approximately **horizontal**.

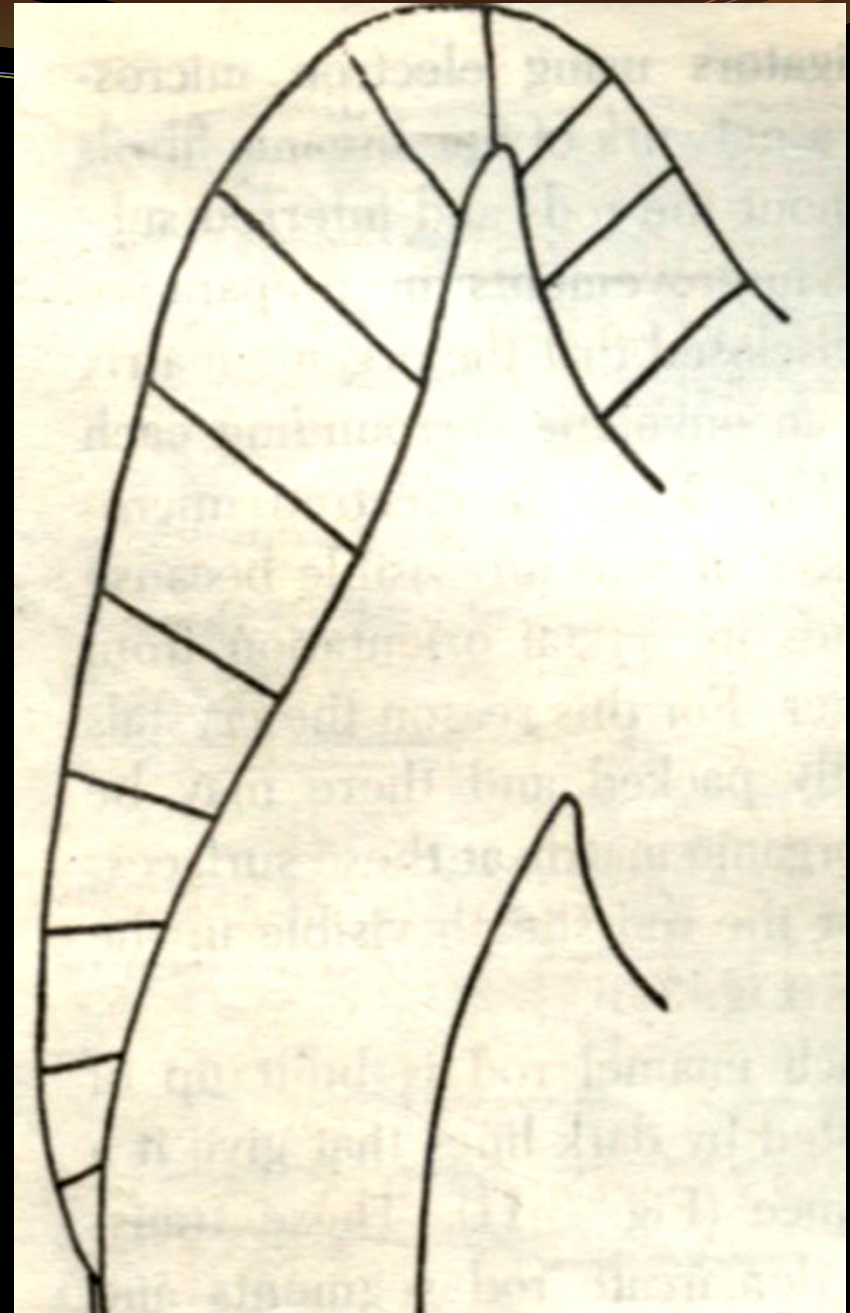
Near **incisal edge and tip** of the cusps they change gradually to an increasingly **oblique direction** until they are **almost vertical** in the region of the edge or tip of cusp.



In the **permanent teeth**, arrangement of rods is similar to deciduous teeth in occlusal 2/3 of crown.

In the **cervical region** rods deviate from the horizontal to **apical direction**.

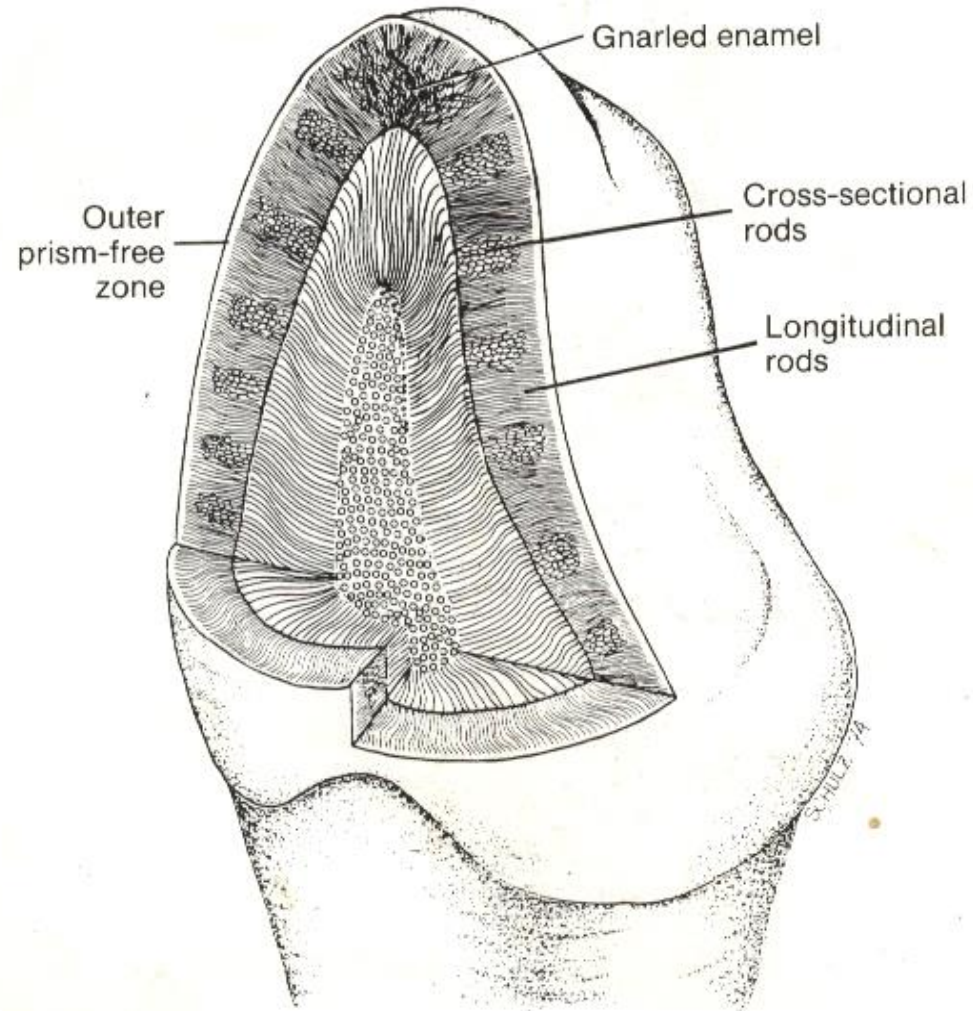
Alternative clockwise and counterclockwise alteration/deviation of the rods from the radial direction can be observed at all levels.



GNARLED ENAMEL

Near the dentin in the region of cusps or incisal edge, **bundles of rods** seem to *intertwine (twisted around each other) more irregularly*, especially in section that is cut obliquely. This *optical appearance* of enamel is called gnarled enamel.

In addition, enamel rods converge in their outward course, in pits and fissures on occlusal surface of molars and premolars.



Dr. Md. Nu

Dr. Md. Nurul Islam

HUNTER-SCHREGER BANDS

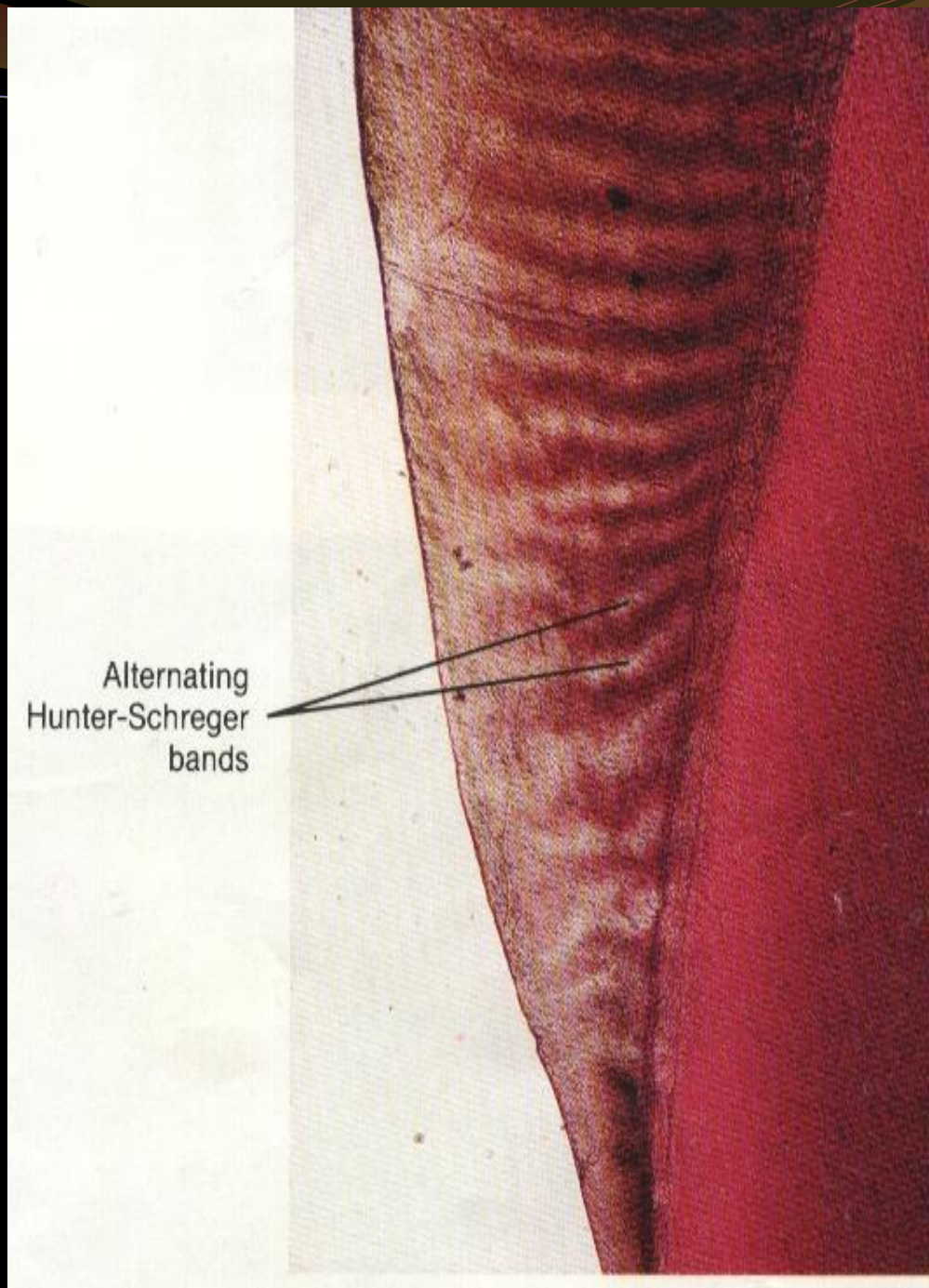
The more or less regular change in the direction of rods may be regarded as a functional adaptation, minimizing the risk of cleavage in the axial direction under the influence of occlusal masticatory forces.

The bands of Hunter Schreger are an *optical phenomenon* .

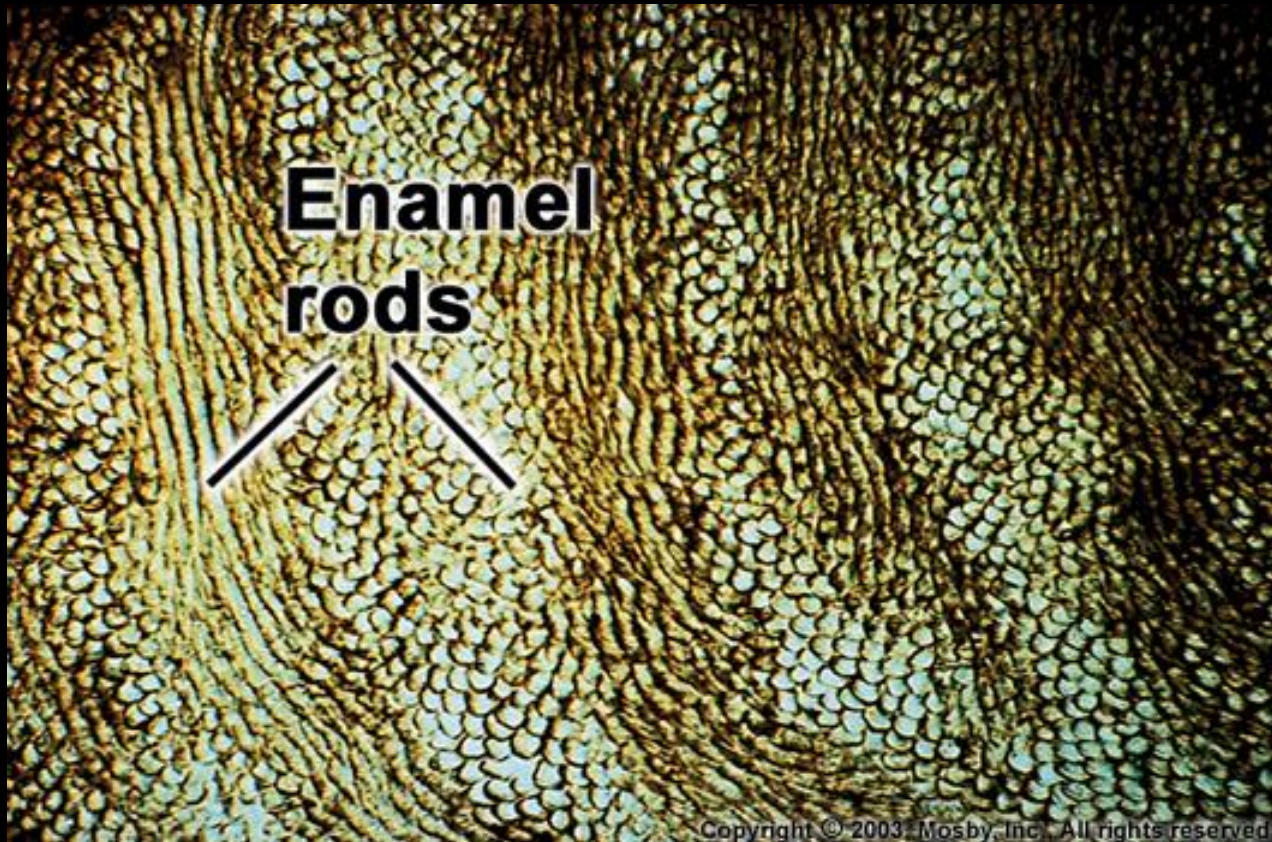
The regular *change in the direction of adjacent group of rods is responsible for the appearance* of alternating dark and light strips of varying width which are called as **Hunter Schreger bands**.

They can be *seen* in longitudinal GS *under oblique reflected light*.

HS bands originate at DEJ & pass outward, ending at some distance from the outer surface of enamel.



Orientation of rods in Hunter-Schreger bands

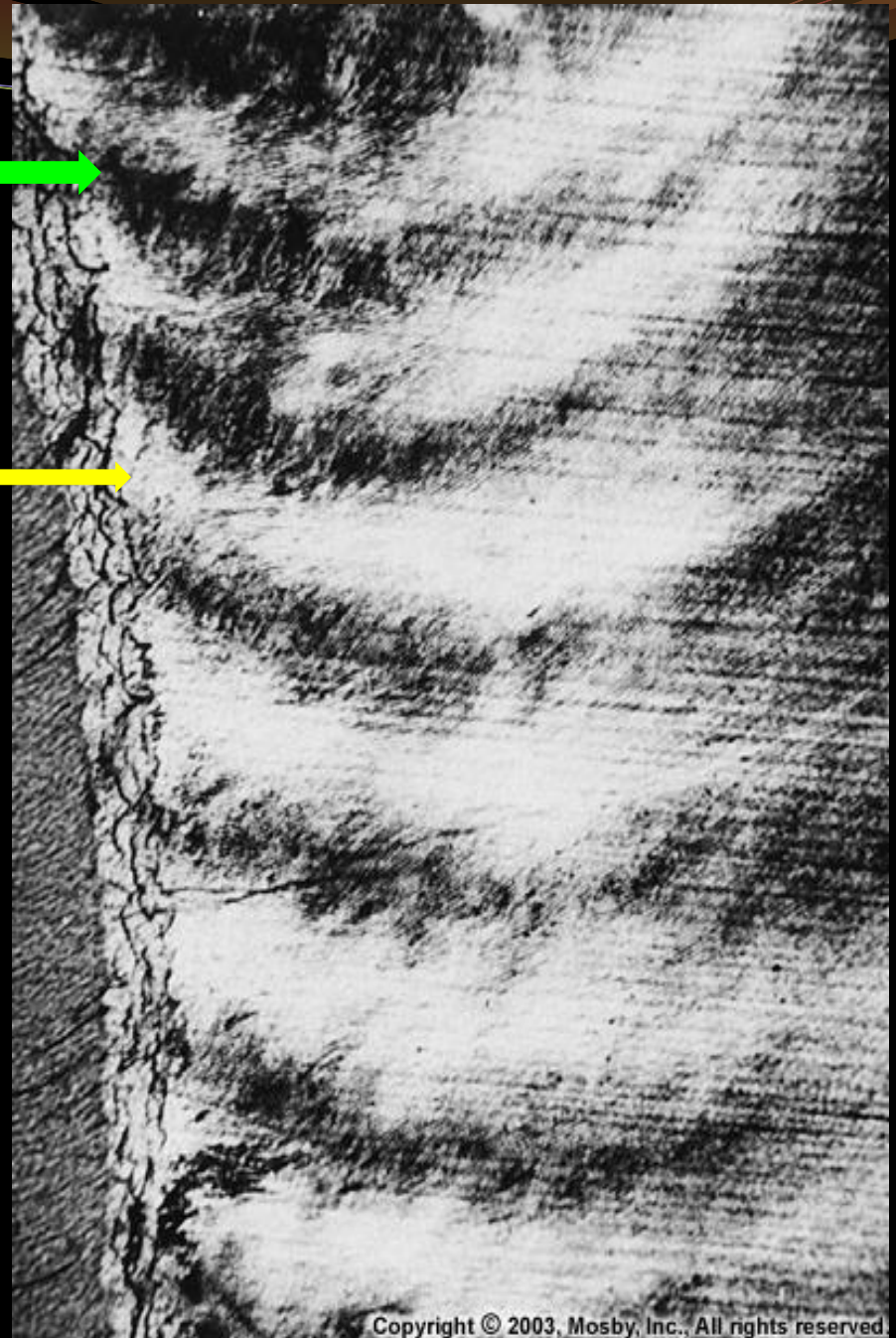


Electron microscopy reveals the difference in orientation of groups of rods within these zones.

The prisms which are cut longitudinally to produce dark bands (because in these regions light is absorbed) are called *parazonies*, while the prisms which are cut transversly to produce light bands are called *diazones*.

Some suggest, possible cause is variation in calcification process.

They may not be an optical phenomena but they are composed of alternate zones having slightly different permeability and different content of organic material.

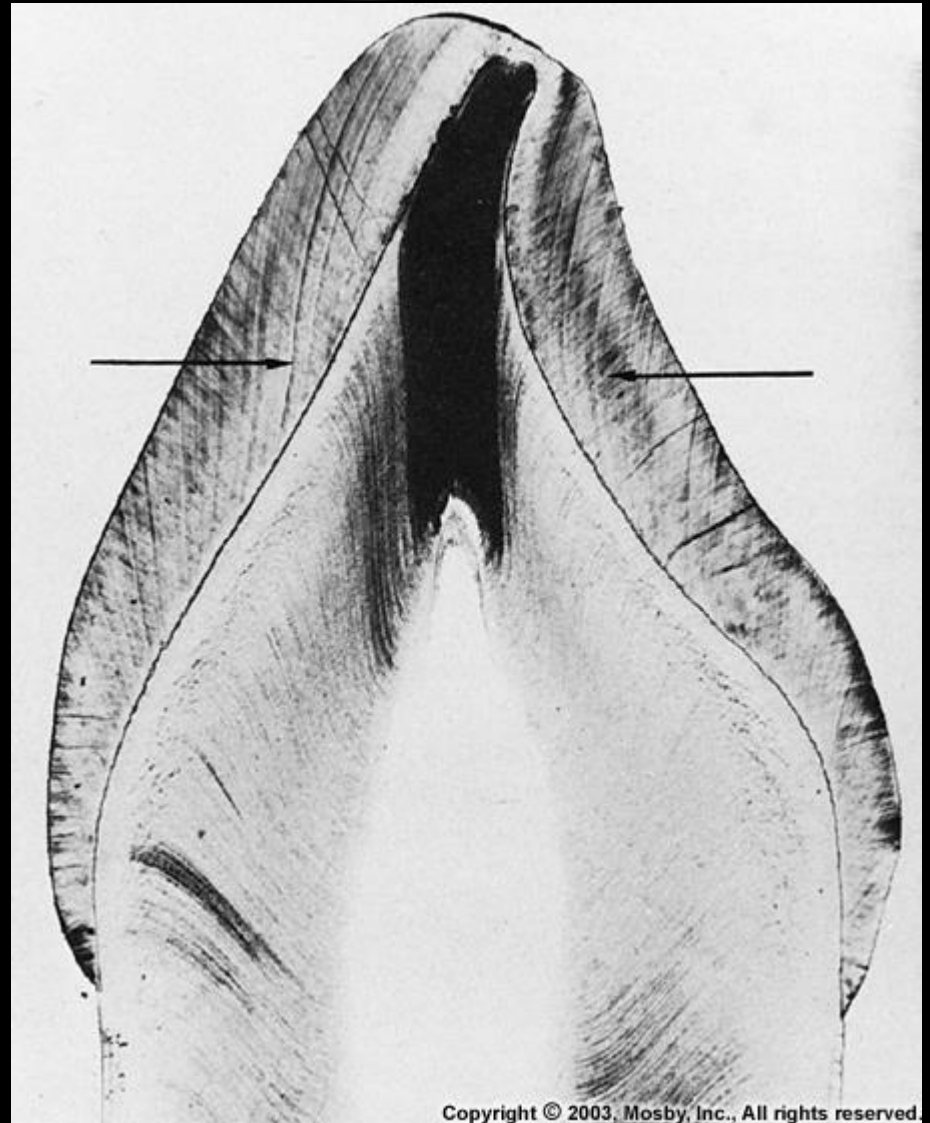


INCREMENTAL LINES OF RETZIUS

Brownish bands seen in ground sections of enamel that *illustrate successive apposition of layers of enamel during formation of the crown* are called Incremental lines of Retzius.

In Longitudinal section, they surround tip of dentin.

From the DEJ to the surface they deviate occlusally.

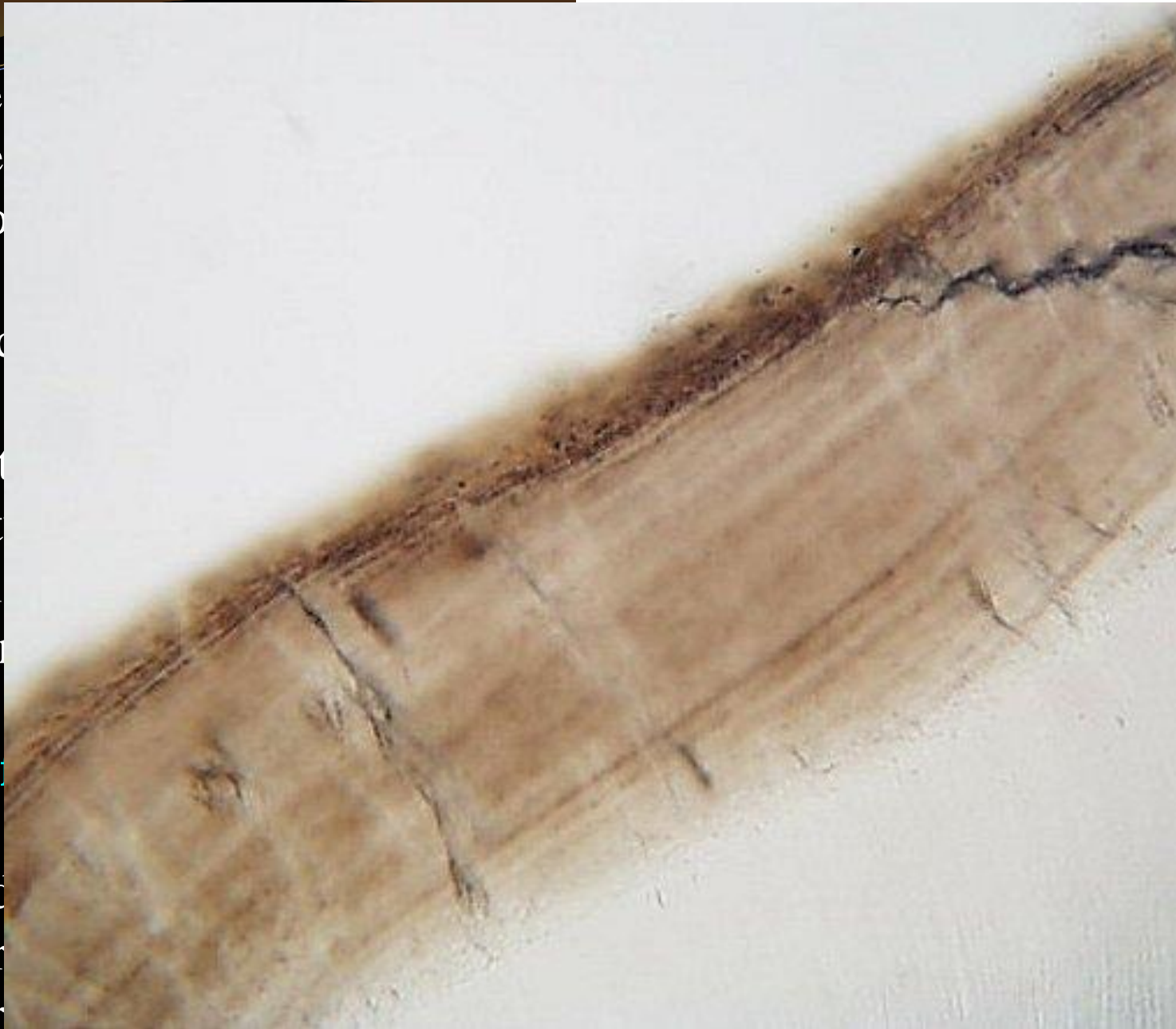


In TS
circle
to the
section
It has
period
rods.
Variat
struct
Physi
rhyth

Signi

Broad
may r
distur

formation



nel

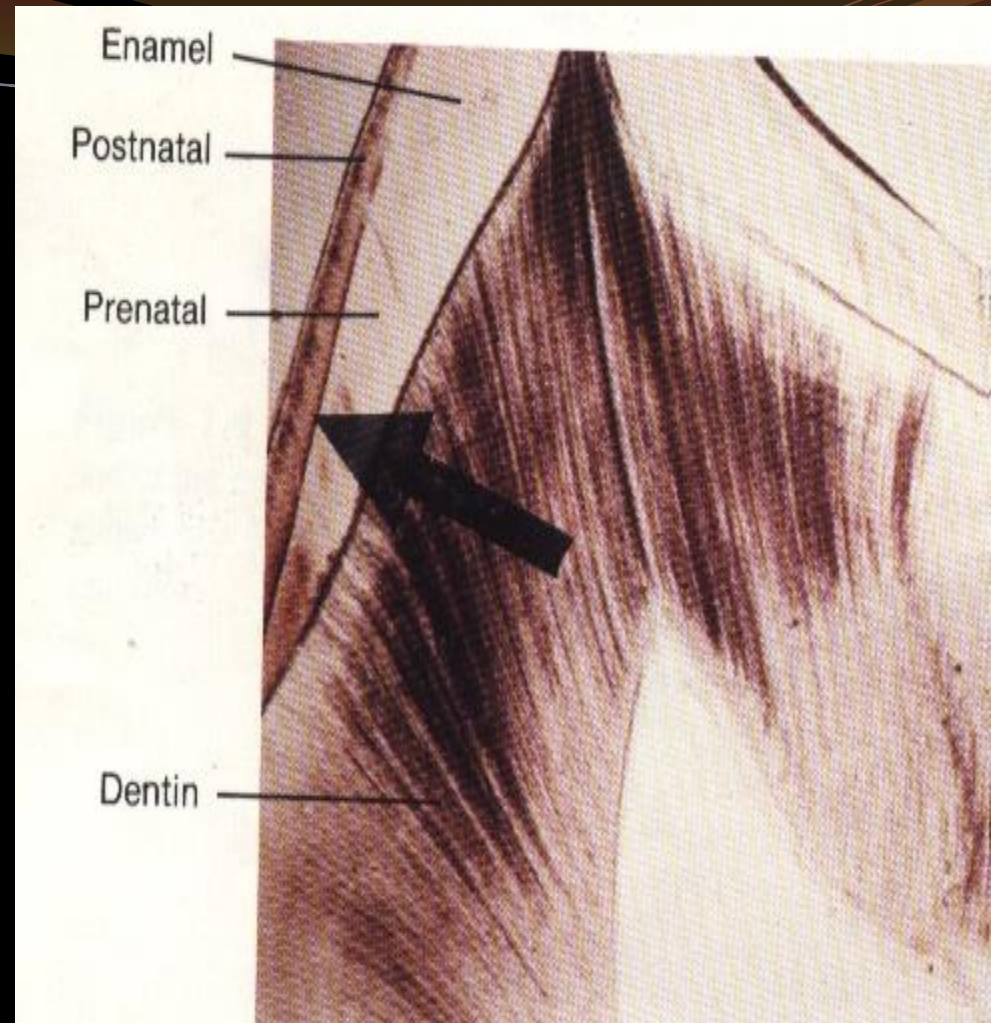
ifts

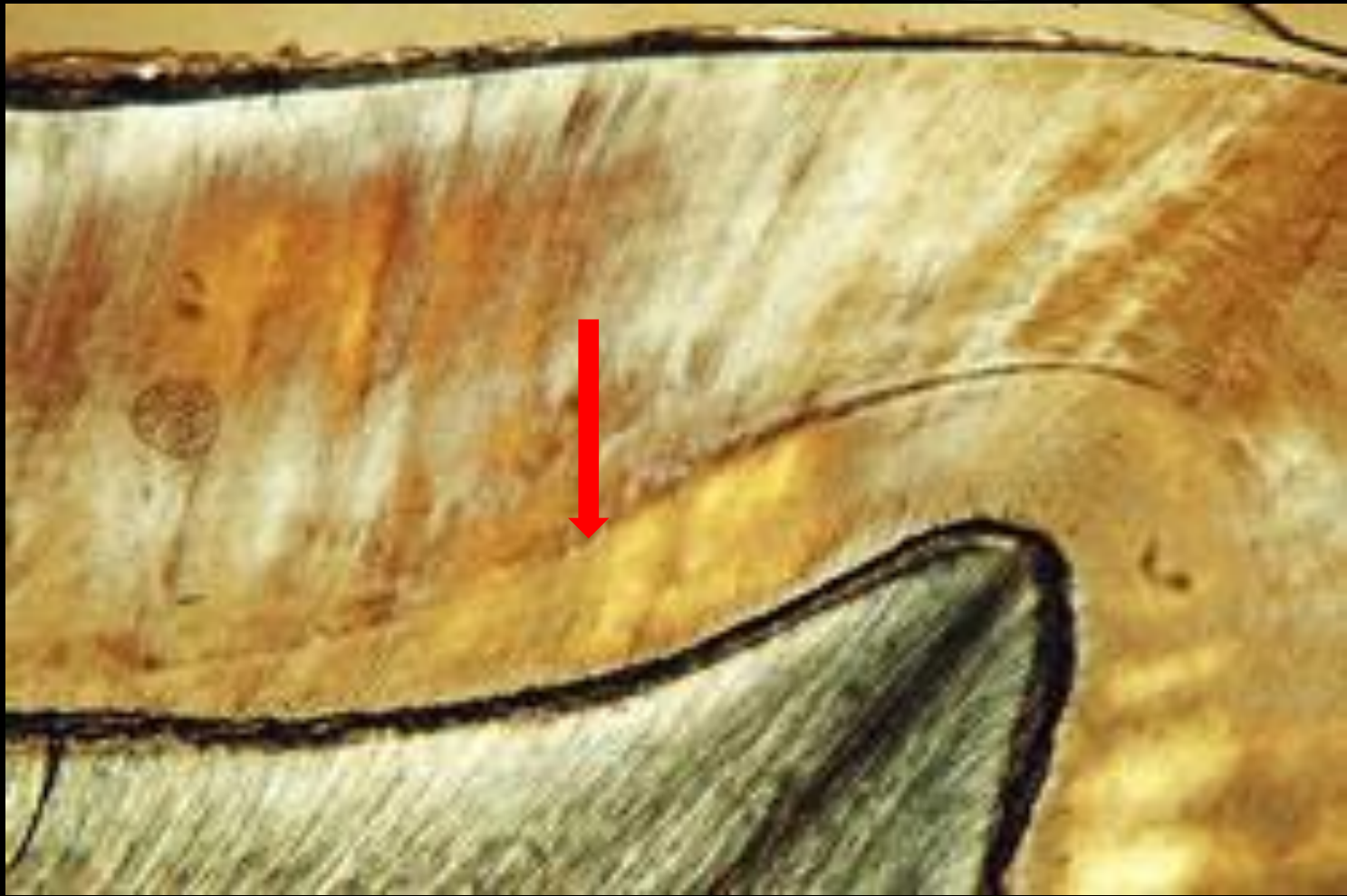NEONATAL LINE:

The enamel of the deciduous teeth develops partly before & partly after birth. The boundary between the 2 portions of enamel in the deciduous teeth is marked by an accentuated incremental line Retzius, the Neonatal line/ring.

Results from abrupt change in the environment & nutrition of newborn infant.

Prenatal enamel is usually better developed than postnatal enamel as fetus develops in well protected environment with an adequate supply of all essential materials.





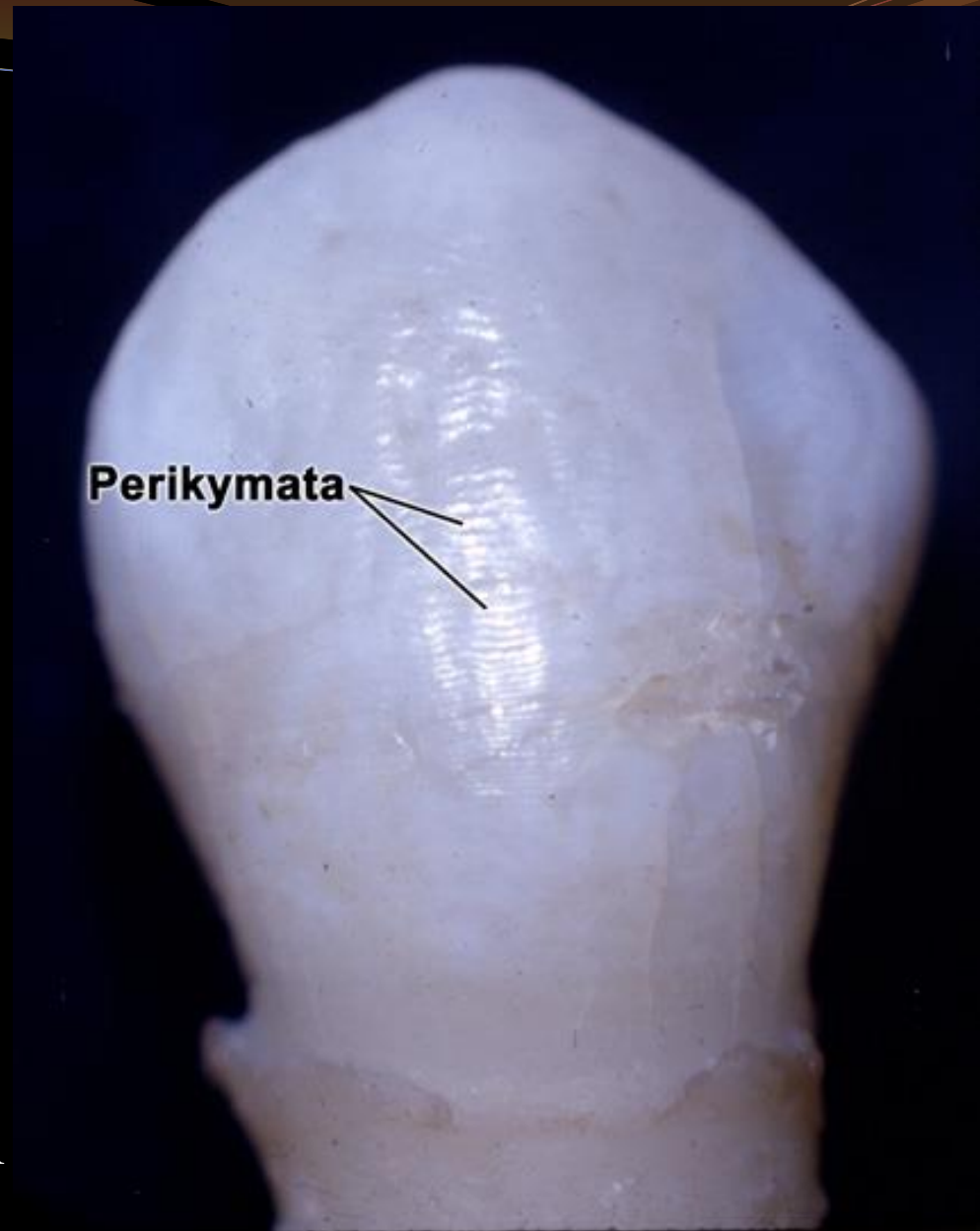SURFACE STRUCTURES

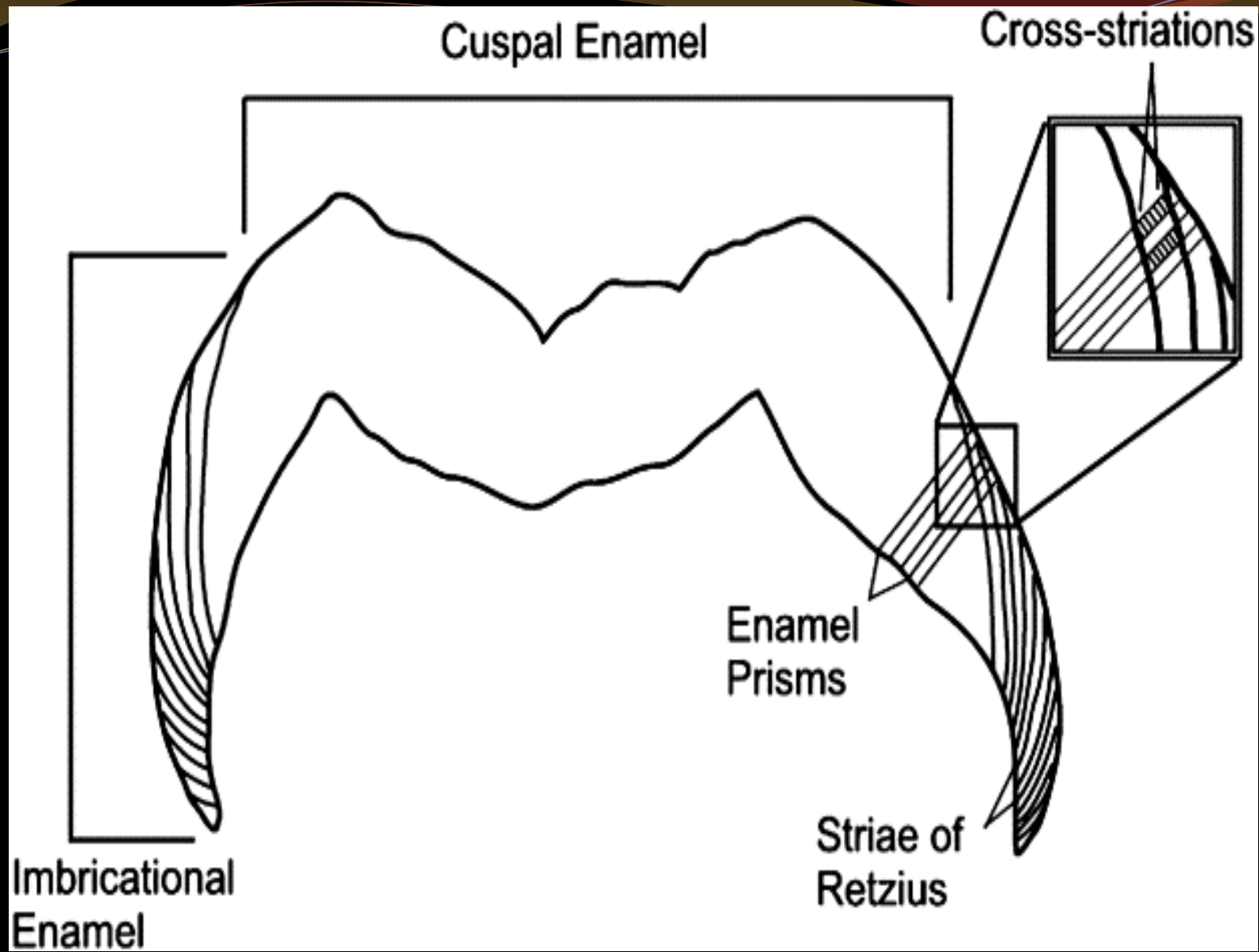
PERIKYMATA or IMBRICATION LINES

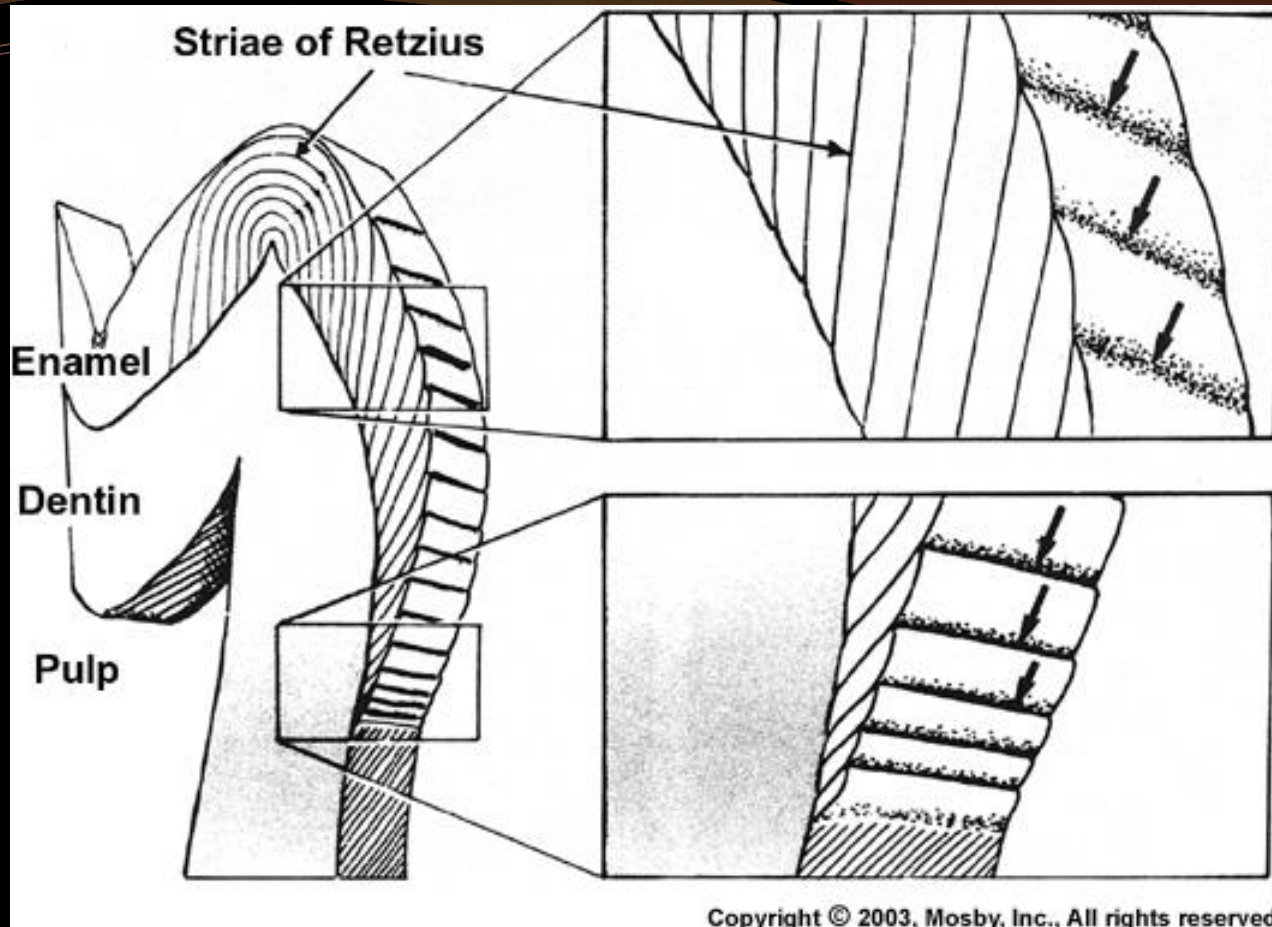
These are transverse wave like grooves, believed to be the external manifestations of striae of Retzius.

No.: 30 perikymata/mm in the region of CEJ.

Their concentration gradually decreases near occlusal or incisal surface to about 10/mm.





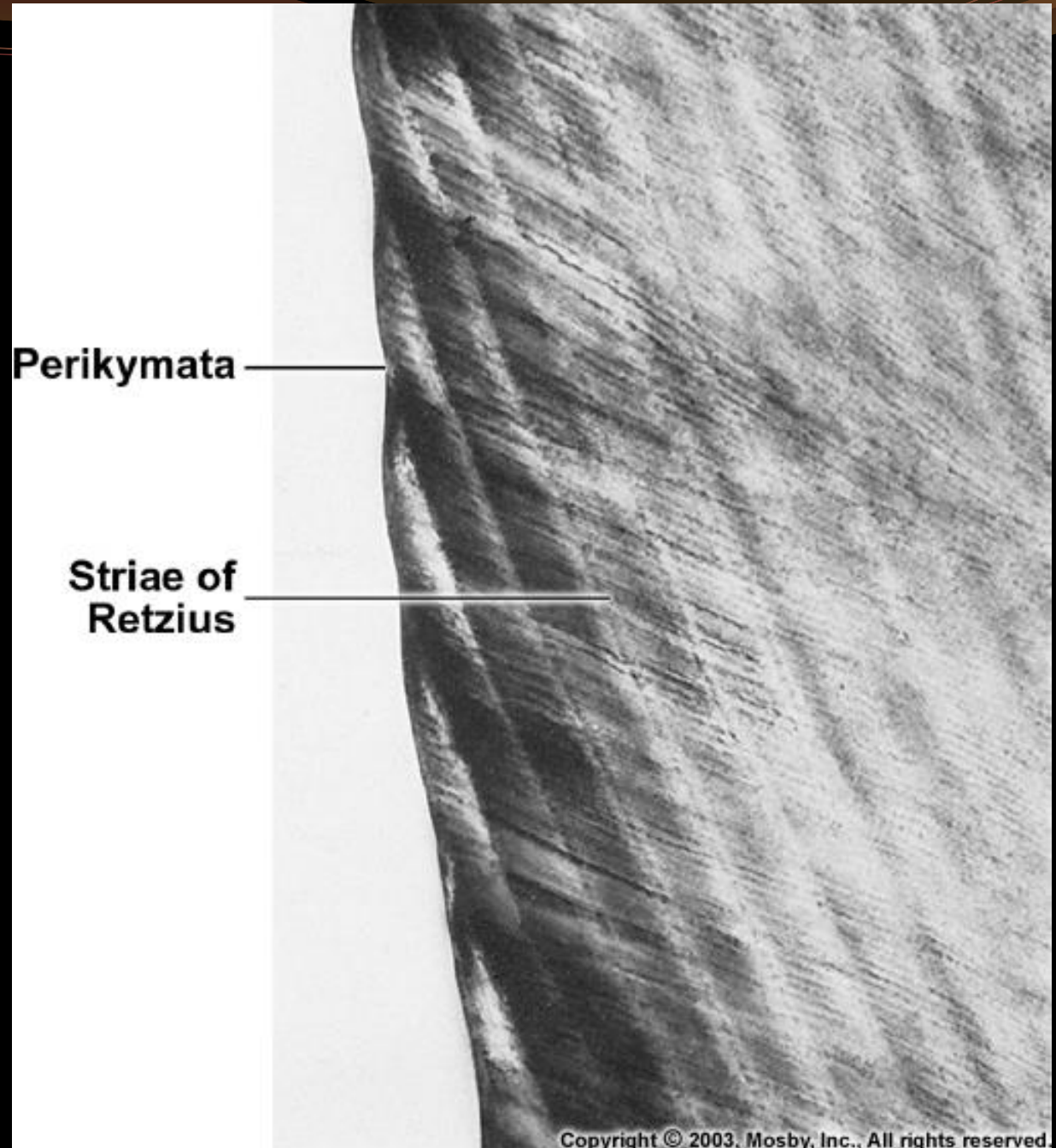


Relationship between incremental lines of Retzius
& Perikymata

Ground section of enamel showing the relationship between the striae of Retzius and surface perikymata .

Perikymata

Striae of Retzius



Scanning
electron
micrograph
of the labial
surface of a
tooth,
showing the
perikymata.



Copyright © 2003, Mosby, Inc., All rights reserved.

STRUCTURELESS LAYER or PRISMLESS ENAMEL

It is structureless and approximately 30µm thick.

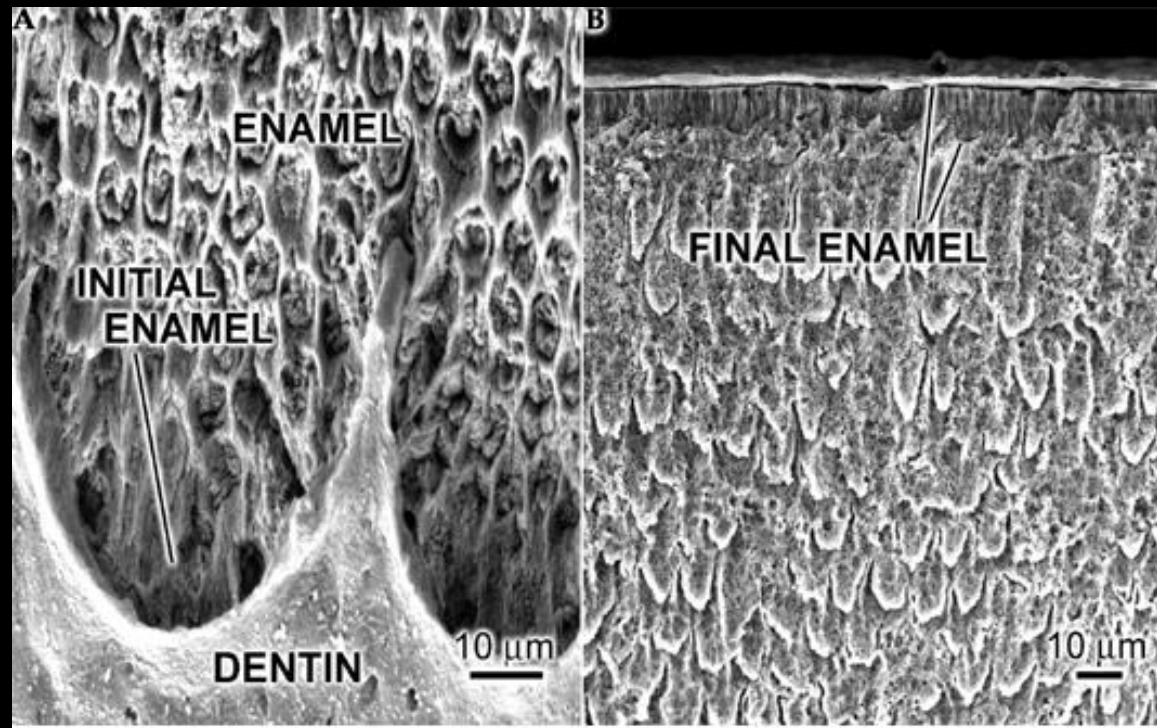
Present in 70 % of all permanent teeth and all deciduous teeth.

Most common in cervical areas of enamel surface.

More mineralized than deeper layer.

No prism outlines are visible and all the enamel crystals are parallel to one another and perpendicular to striae of Retzius.

The (A) first (initial) and (B) last (final) enamel layers are aprismatic, that is, they do not contain rods.



ENAMEL ROD ENDS:

These are concave and vary in depth being deepest at the incisal or Occlusal regions.

The surface of enamel is uneven having *PITS* (small depressions) and *ENAMEL CAPS* (small elevations).

Surface pits represent the ends of ameloblasts and the caps are due To enamel deposition on nonmineralizable debris.

Larger elevations are called *ENAMEL BROCHES*.

CRACK:

They are actually outer edges of lamellae.

Extent:

They originate from DEJ & extend to varying distances in enamel

Length: 1mm mostly

ENAMEL CUTICLE:

A delicate membrane covers the crown of newly erupted tooth called *Nasmyth's membrane or primary enamel cuticle*. This is soon removed by mastication.

Electron microscopic studies have indicated that this membrane is a typical basal lamina found beneath most epithelia.

This basal lamina is secreted by the ameloblasts when enamel formation is completed.

The function of the enamel cuticle is to protect the surface of enamel from resorptive activity of adjacent vascular tissue prior to the eruption of the tooth.

PELLICLE:

Erupted enamel is covered by a precipitate of salivary proteins called pellicle.

It becomes colonized by microorganisms within a day or two after formation and forms bacterial plaque.

ENAMEL LAMELLAE:

Enamel lamellae are thin leaf like structures that extend from enamel surface toward DEJ.

Composition mainly organic, little mineral.

Origin:

Enamel lamellae may develop in planes of tension when rods cross such a plane , they may not fully calcify.

If the disturbance is more severe, a crack may develop that is filled... either by surrounding cells if it has occurred in unerupted tooth Or by organic material if it has occurred after eruption



TYPES:

Type A : EL consists of poorly calcified rod segments
Restricted to enamel.

Restricted to enamel.

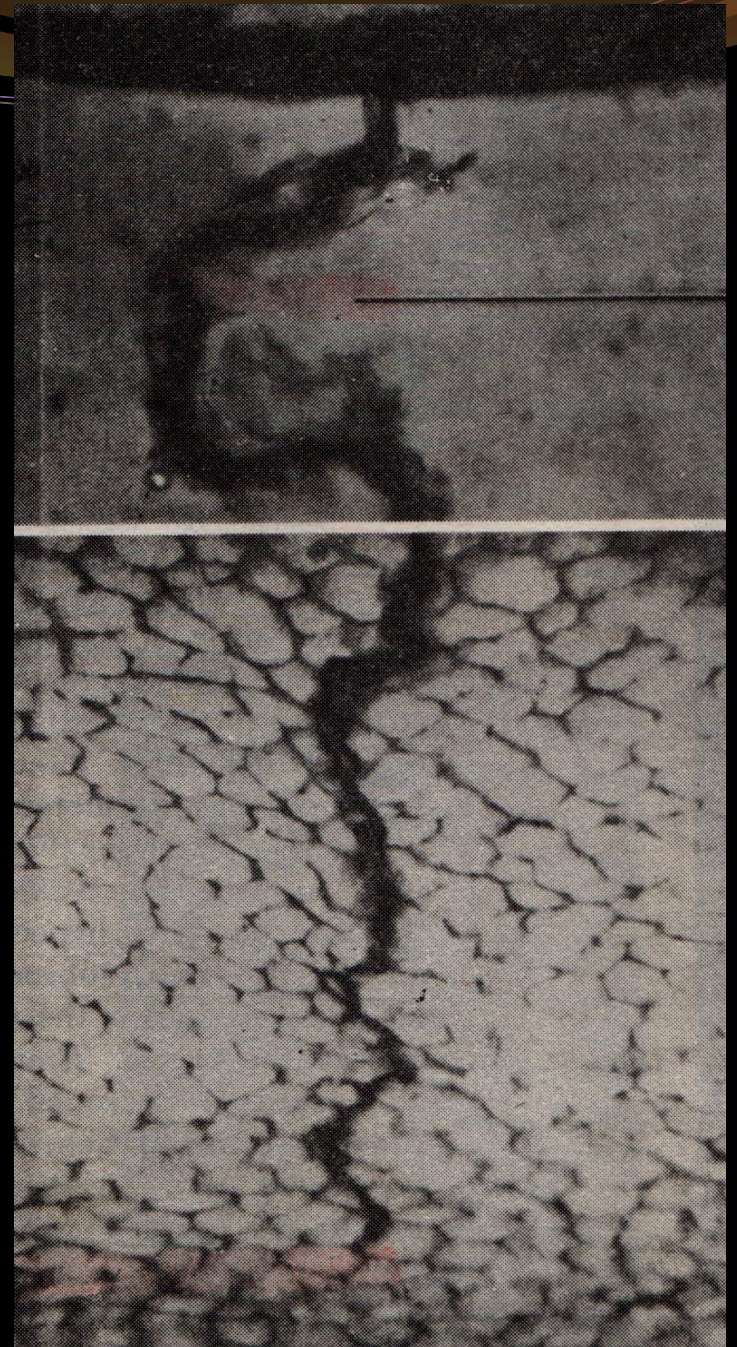
Type B: EL that consists of degenerating cells
May reach in to dentin

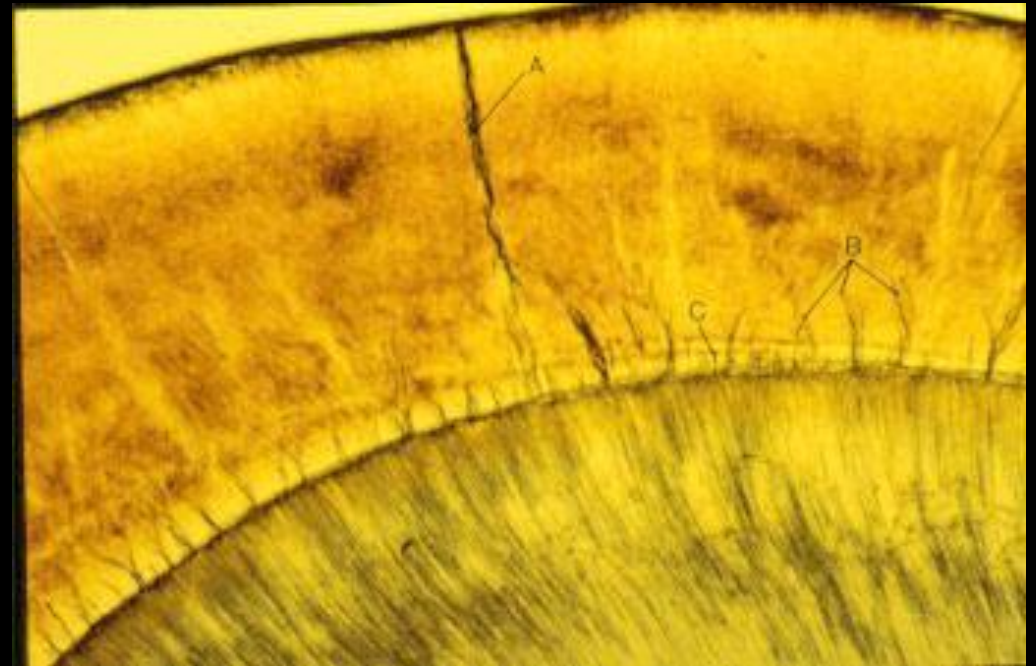
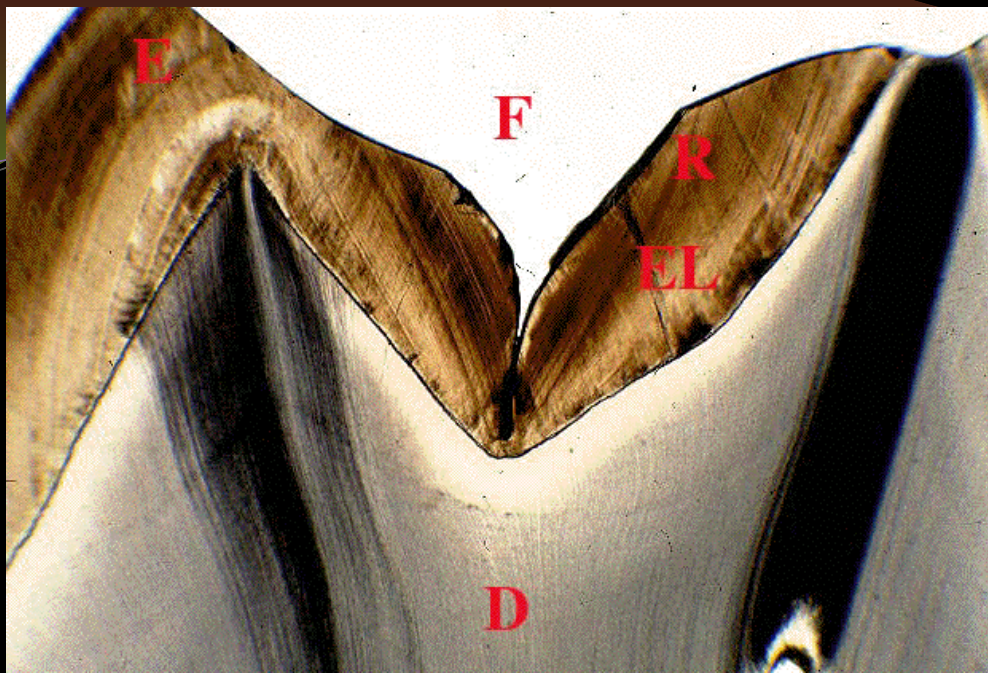
May reach in to dentin

Type C: EL containing organic material, presumably from saliva.

If connective tissue invades the cracks in enamel, cementum may be formed.

Significance: It has been suggested that lamellae may be a site of weakness in a tooth and may form a road of entry for bacteria that initiate caries.



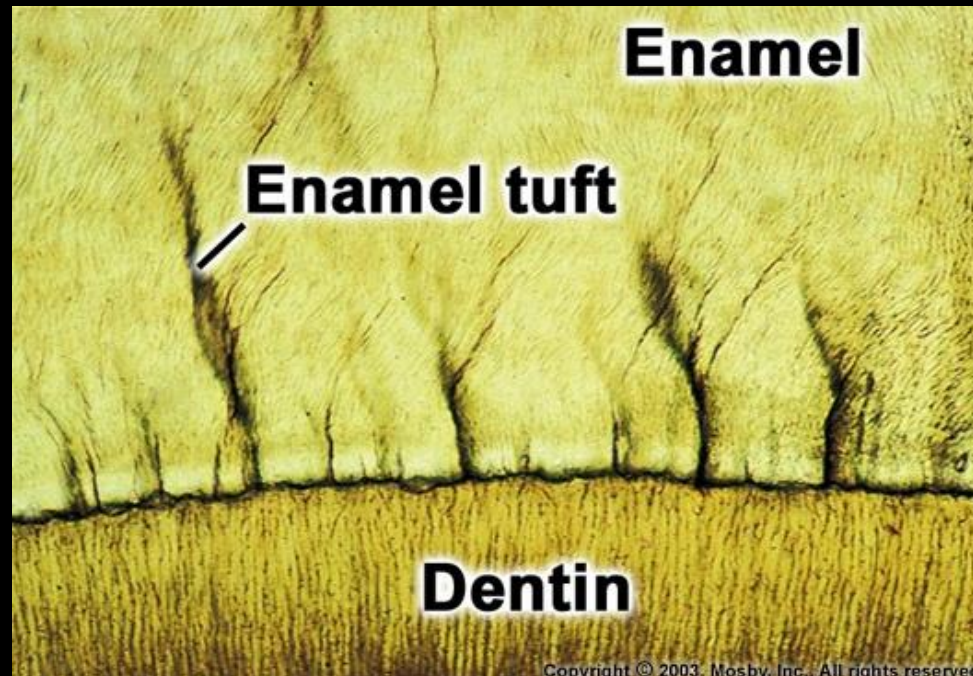


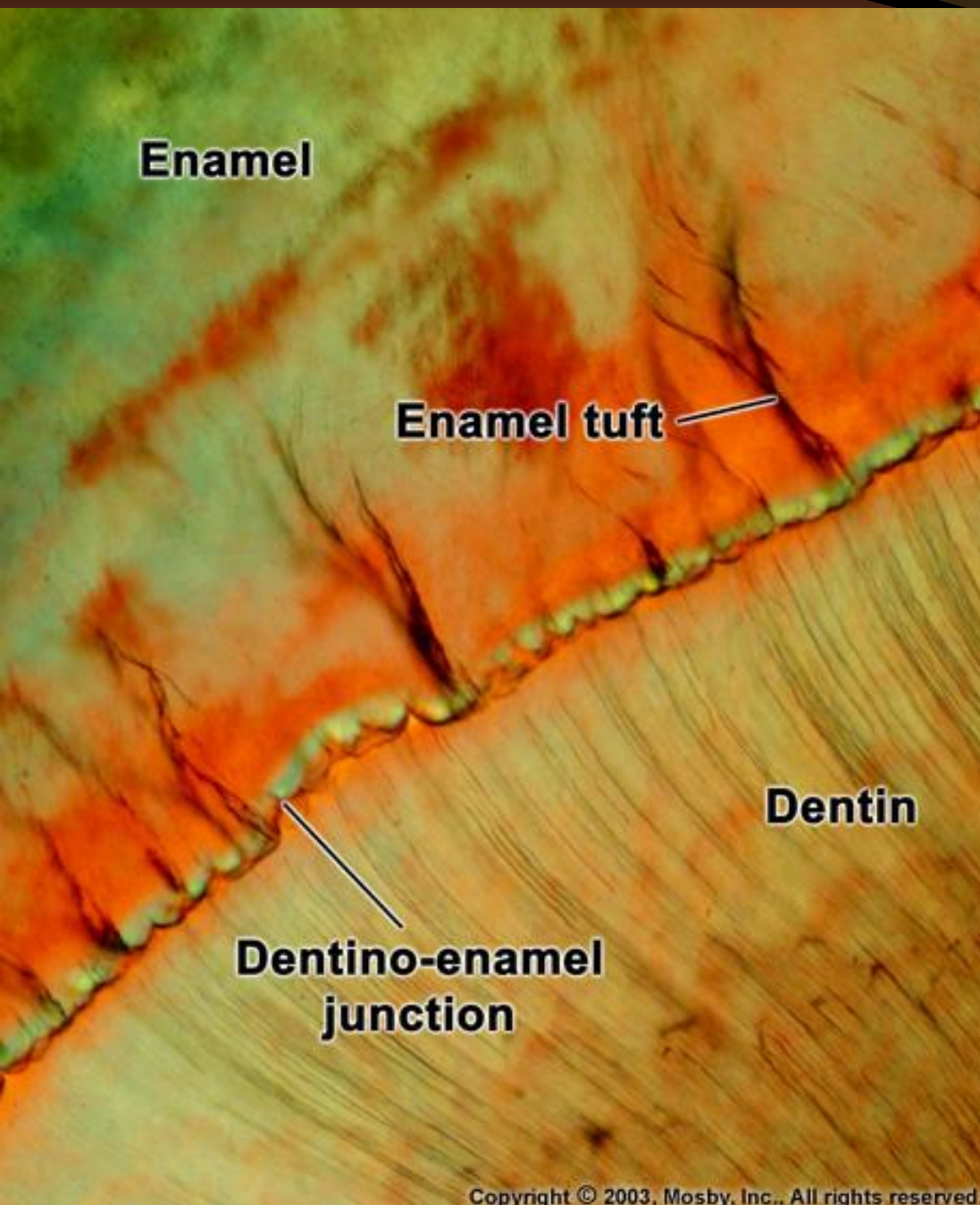
ENAMEL TUFTS:

Thin ribbon like structure, resembling tufts of grass.

Enamel tuft does not spring from a single small area but is a narrow, ribbon like structure, the inner end of which arises at the dentin and when examining such area under low magnification in thick ground section it gives grass like appearance.

Tufts consists of hypo calcified enamel rods & interprismatic substance.





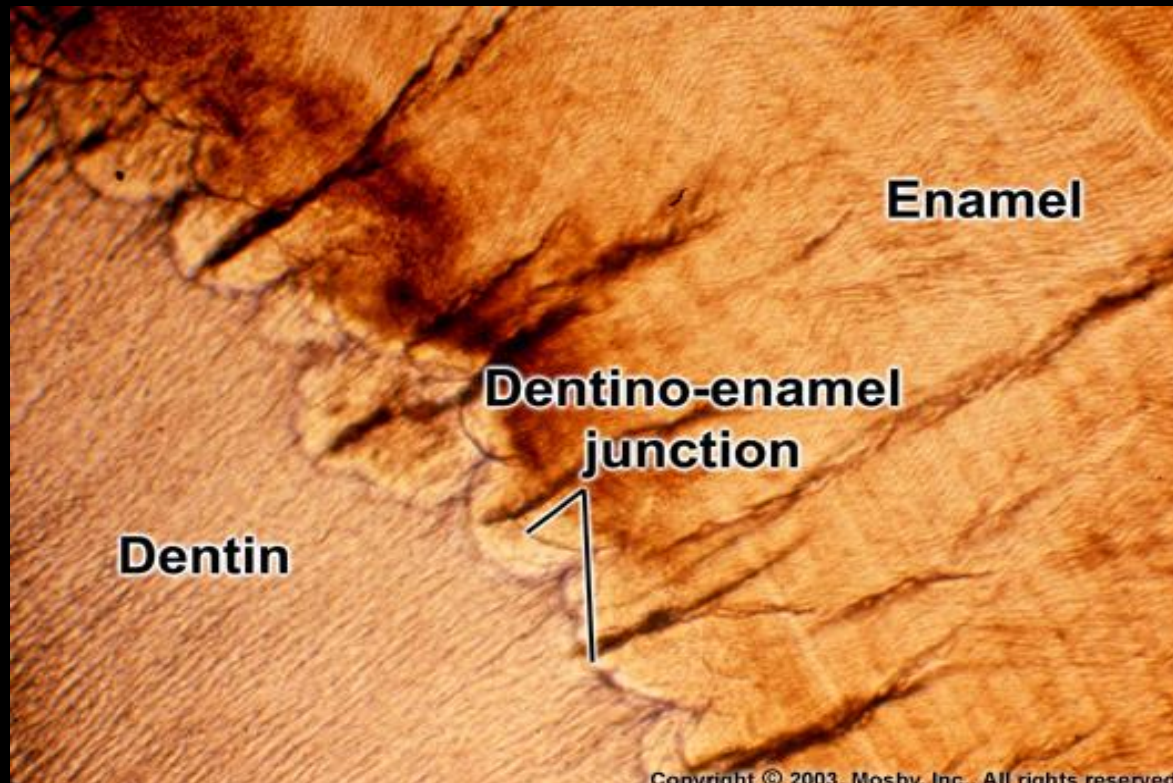
They arise at DEJ & reach in to enamel to about 1/5 to 1/3 of its thickness.

Their presence & their development are consequence of an adaptation to spatial condition of enamel.

DEJ:

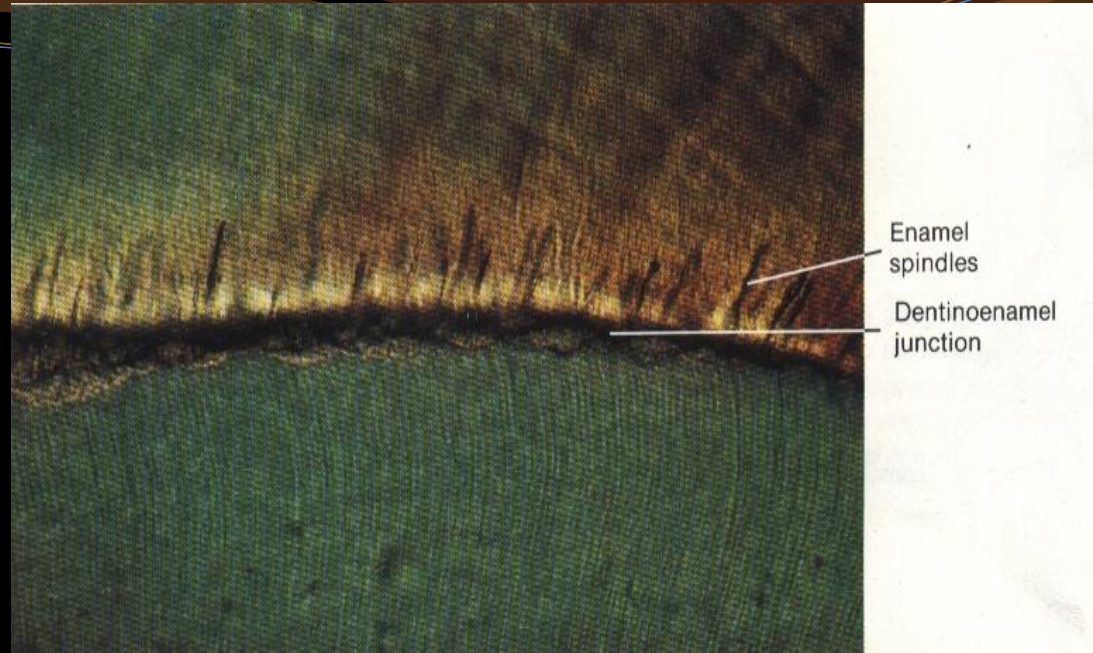
Scalloped... the surface of the dentin at DEJ is pitted, in shallow depression of dentin, fit rounded projection of enamel.

Scalloping ensures firm hold of the enamel cap to dentin.

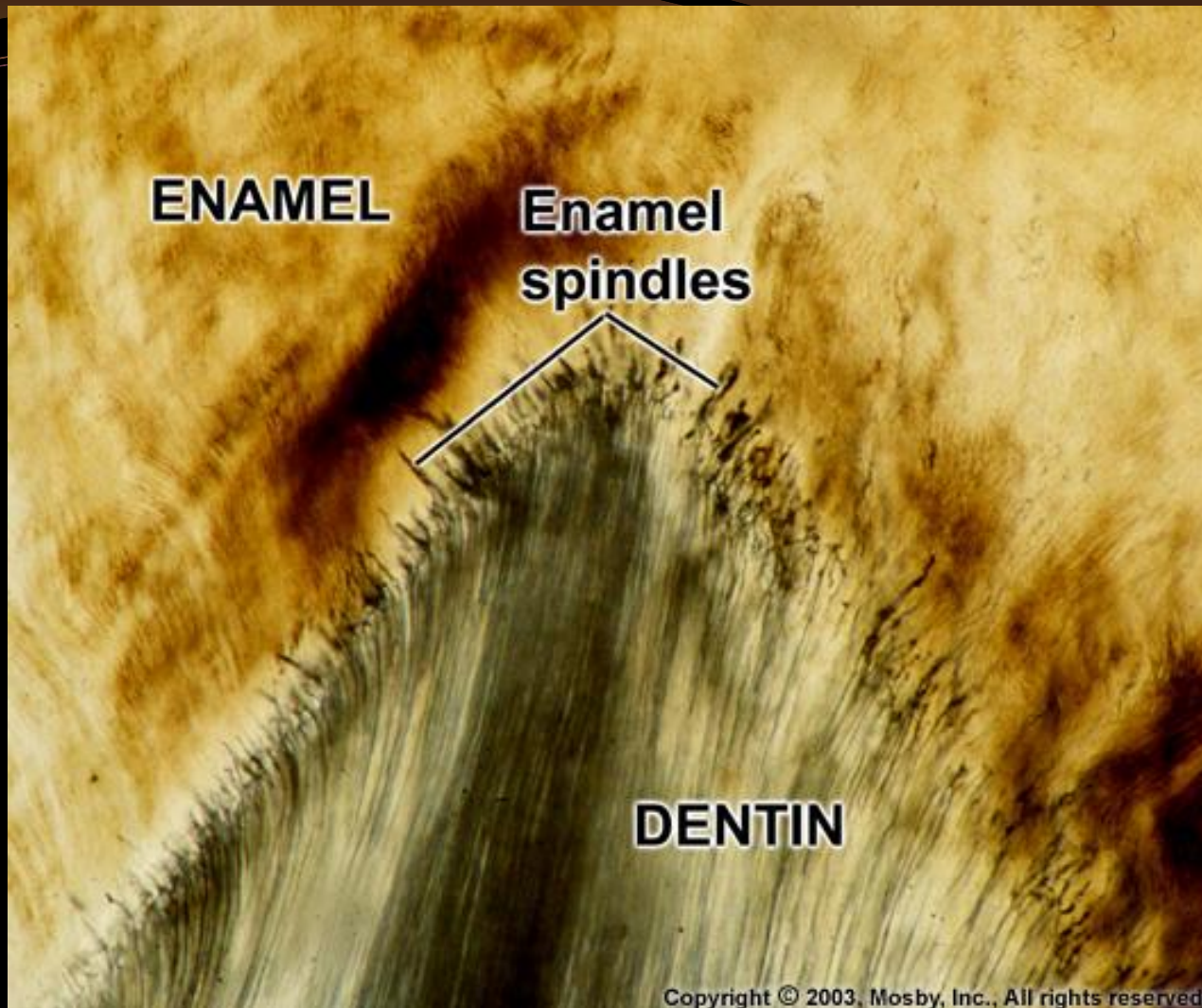


ENAMEL SPINDLES

Occasionally Odontoblast processes pass across DEJ into enamel, since many are thickened at their end, they have been termed enamel spindles.



Directions of spindles and rods are divergent as rods are formed at an angle to ameloblast and spindles are parallel to ameloblasts.



Enamel spindles at tip of the cusps

HYPOCALCIFIED AREAS OF ENAMEL

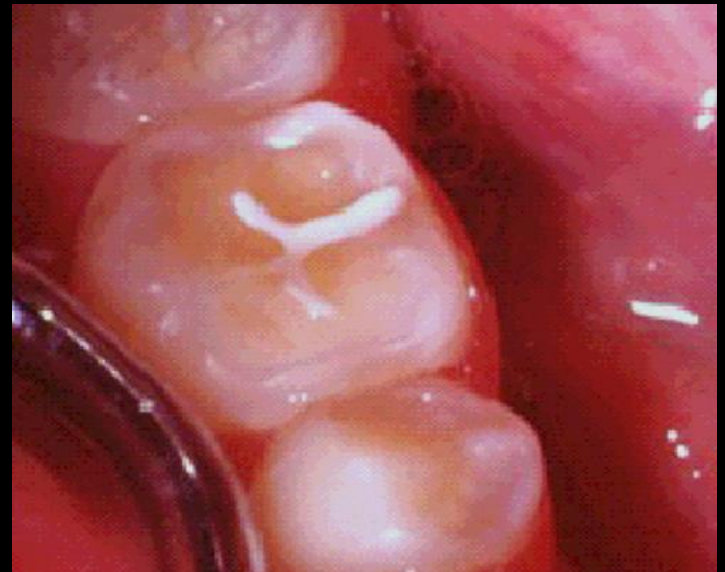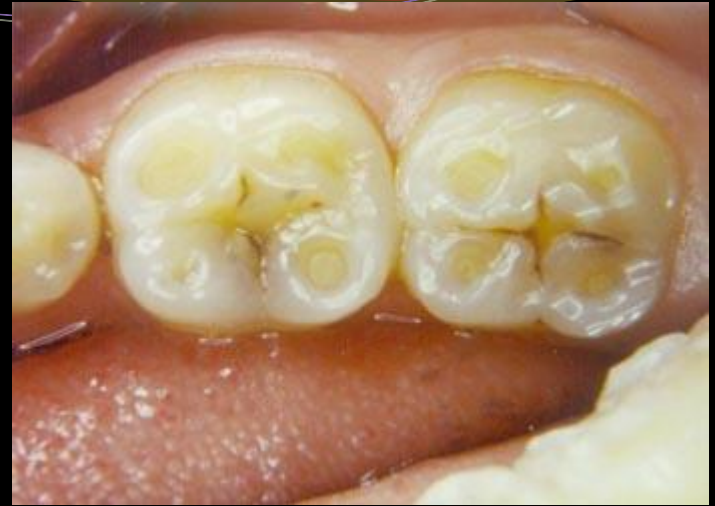1. Rod sheath
2. Transverse striations
3. Incremental lines of Retzius
4. Neonatal line
5. Enamel lamellae
6. Enamel tufts
7. Enamel cracks
8. Enamel spindles

AGE CHANGES

ATTRITION

Most common age change is Attrition or wear of occlusal and proximal surfaces

Evidenced by loss of vertical dimension of crown and by flattening of proximal contour.



LOSS OF SURFACE CHARACTERISTICS

Generalized loss of rod ends.
Flattening of perikymata.

The rate at which structures are lost depends upon..

Location of surface of tooth

Location of tooth in mouth

Localised increase of certain element such as Nitrogen & Fluorine has been found in superficial layers of enamel.

Teeth may become darker & their resistant to decay may be increased as a result of age change.

Reduced permeability of older teeth to fluid is suggestive of an age change.

Enamel may become harder with age.

CLINICAL CONSIDERATION :

Direction of rods is important in cavity preparation – unsupported enamel rods should not be left at the cavity margins because they would break and produce leakage.

Deep enamel fissures and enamel lamellae – predispose to dental caries

Cervical enamel should be kept smooth to prevent periodontal problems

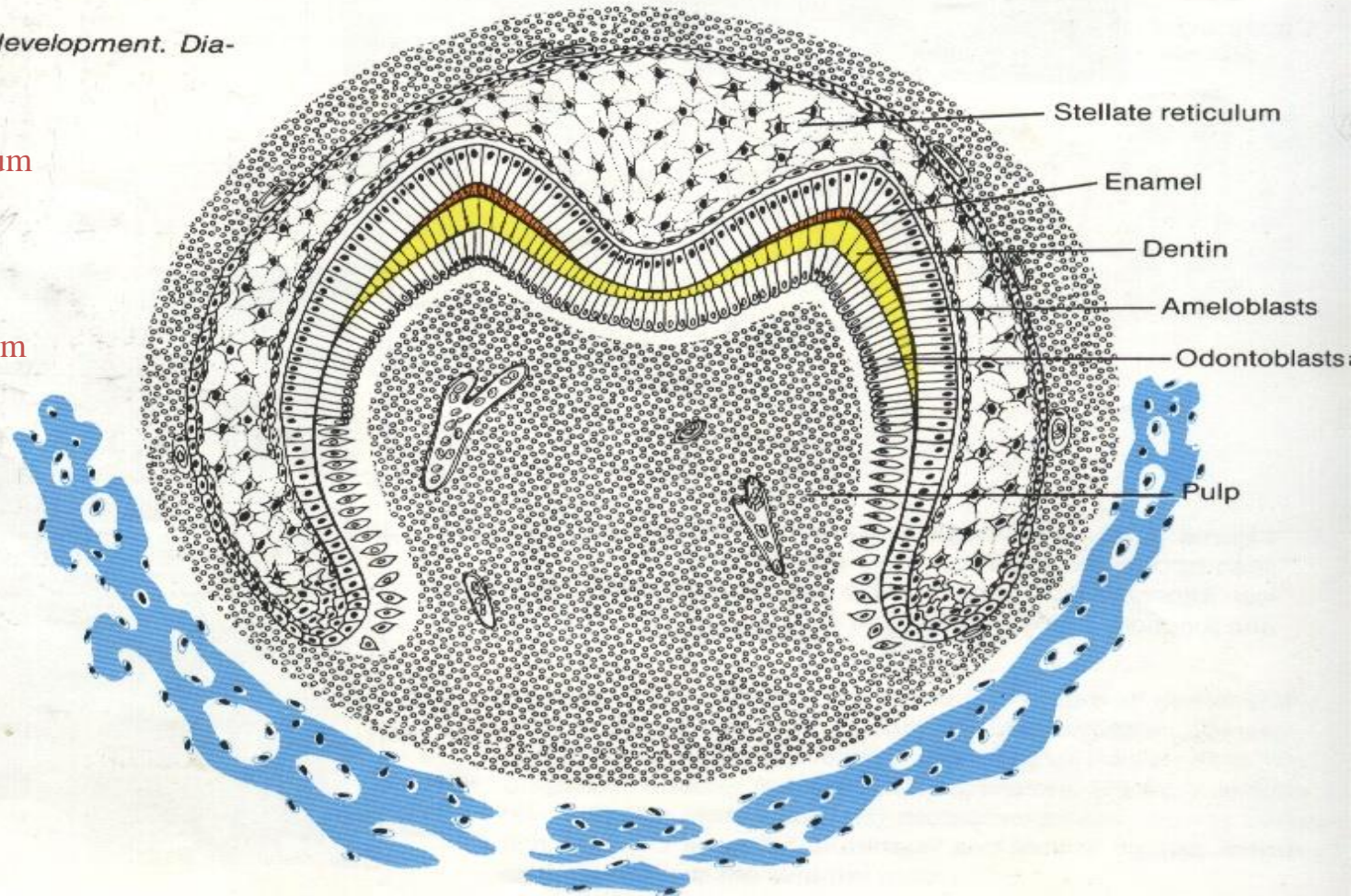
Composite resins – bond directly to the enamel

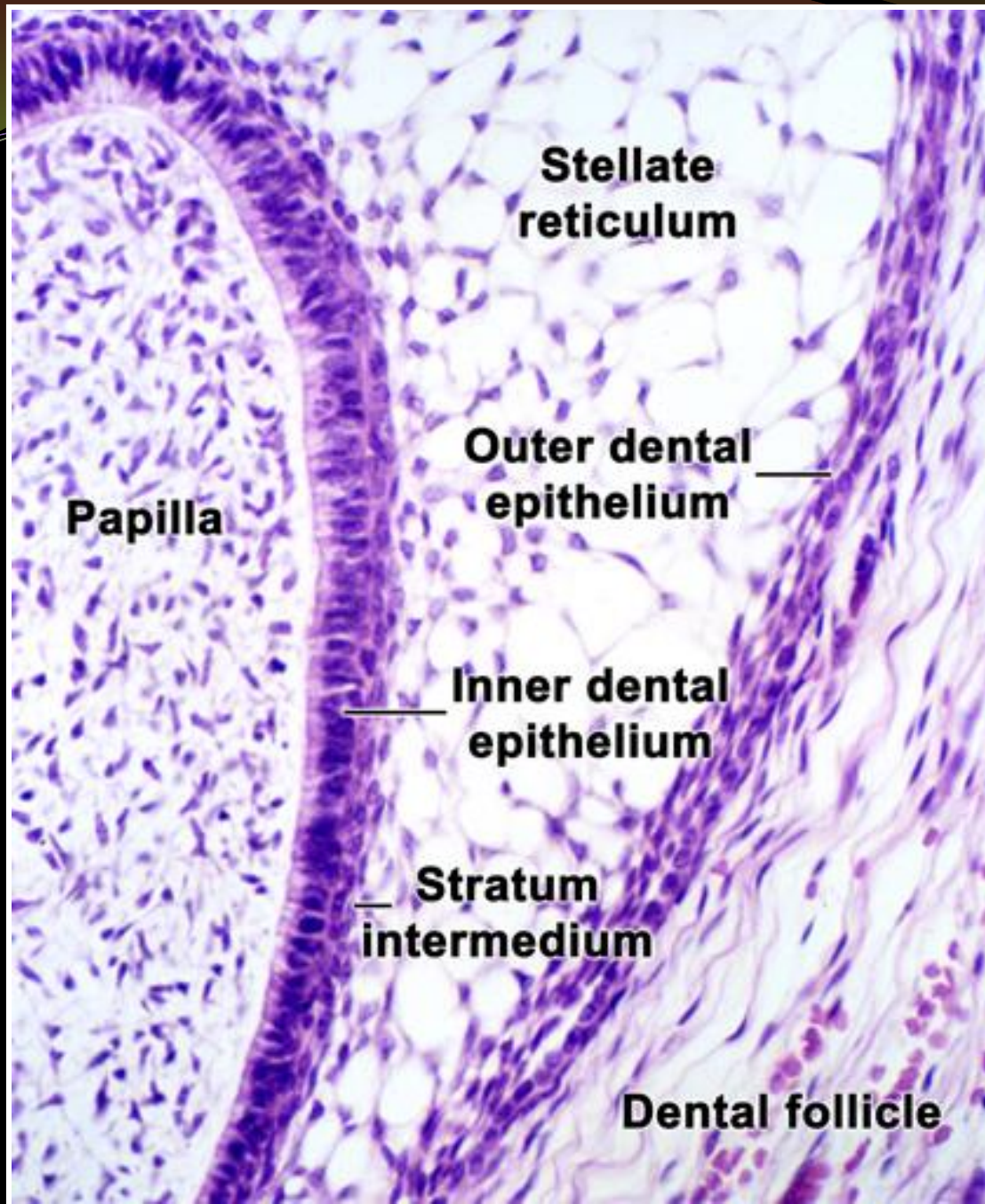
DEVELOPMENT OF ENAMEL:

At the stage preceding the formation of hard structure (dentin and enamel), the enamel organ consists of 4 distinct layers.

Figure 5.13 Tooth development. Diagram of amelogenesis.

1. Outer enamel epithelium
2. Stellate reticulum
3. Stratum intermedium
4. Inner enamel epithelium



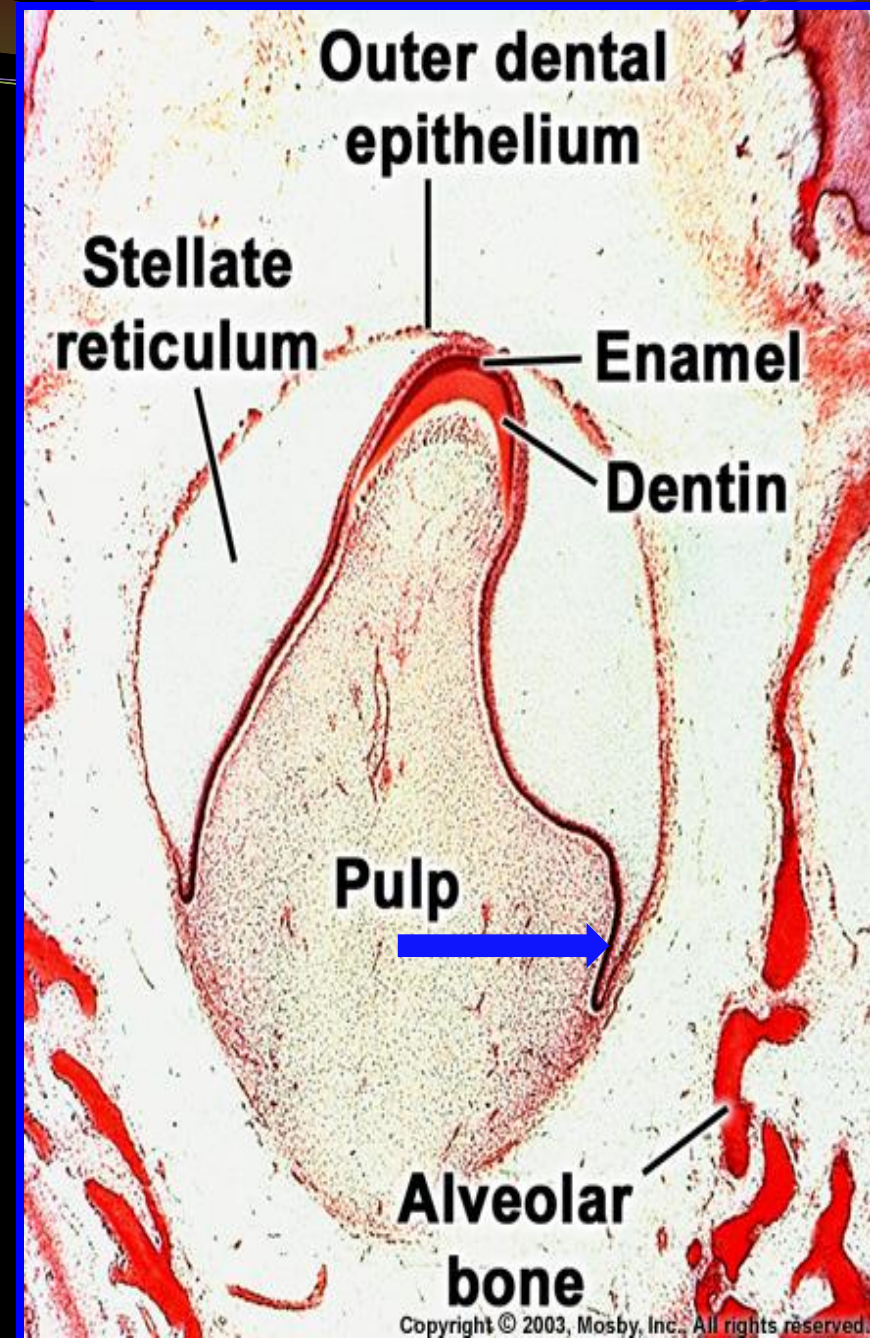


**High-power
view of the four
layers of the
enamel organ
during bell
stage**

At the border of wide basal opening of enamel organ, inner enamel epithelium reflects on outer enamel epithelium. This is called **CERVICAL LOOP**.

The different layers of epithelial cells in enamel organ are named according to their...

1. Morphology(stellate reticulum)
2. Location(OEE, IEE, Stratum intermedium)
3. Function(IEE, Ameloblastic layer)



OUTER ENAMEL EPITHELIUM

It consists of single layer of cuboidal cells.

On highest convexity of organ cells of OEE become irregular in shape.

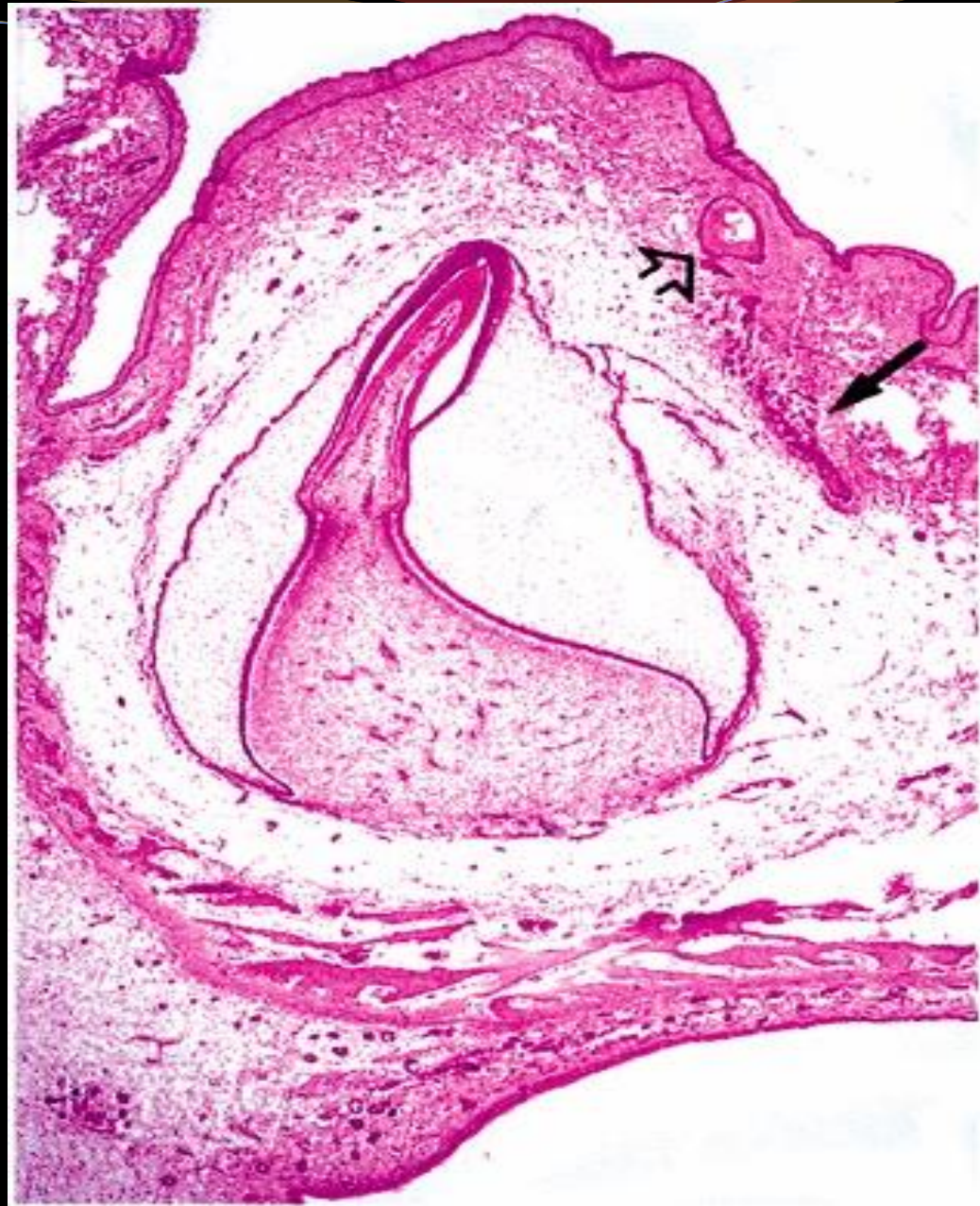
The capillaries in the connective tissue surrounding epithelial enamel organ proliferate and protrude toward it.

Immediately before enamel formation commences capillaries may indent stellate reticulum.

This increased vascularity ensures rich metabolism when a plentiful supply of Bloodstream to the inner enamel epithelium is required.

During enamel formation, the cells of OEE develop villi, cytoplasmic vesicles and large no. of mitochondria... all indicating specialization for active transport of material.

Capillaries adjacent to OEE are thin walled indicating active transport.

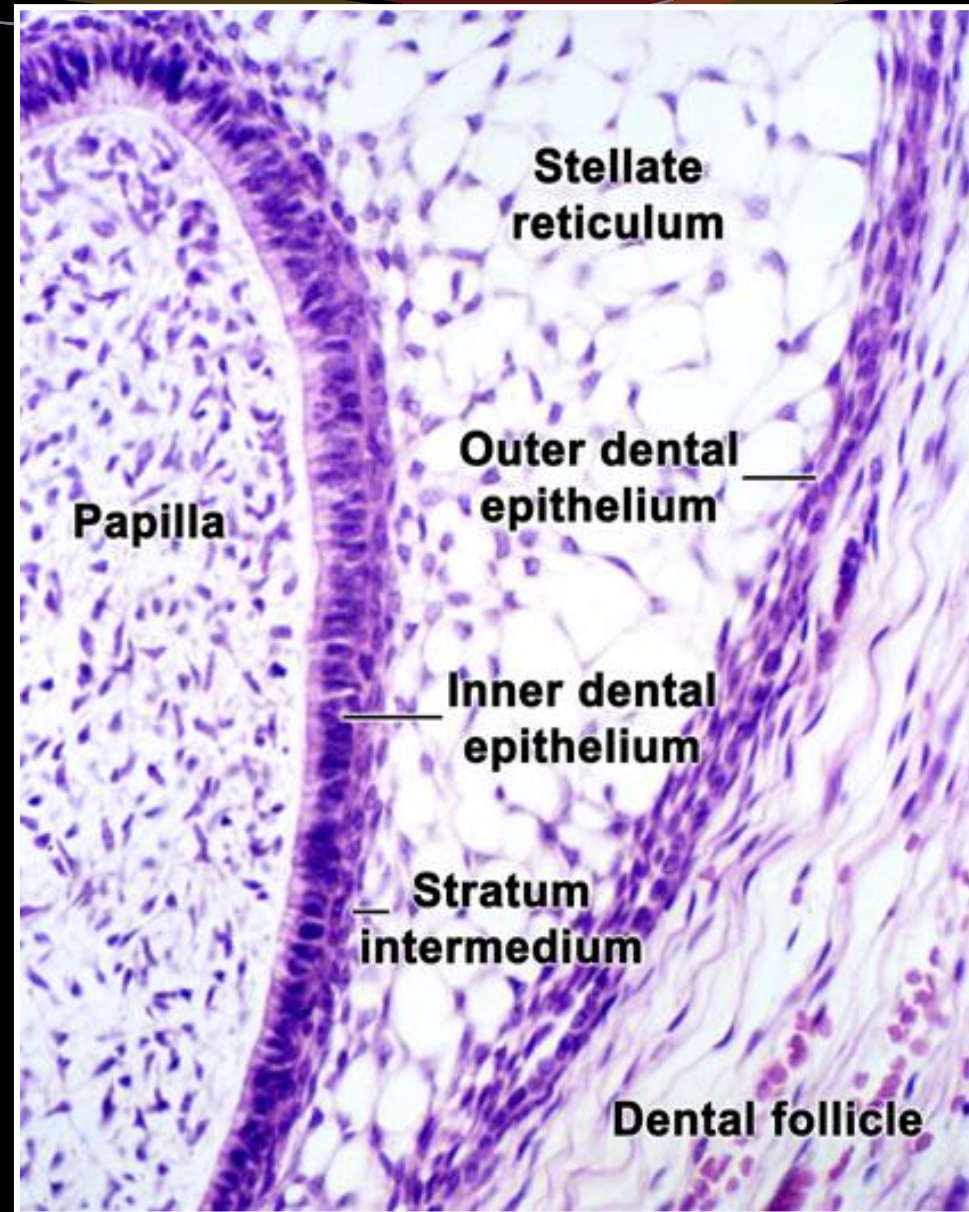


STELLATE RETICULUM:

Middle part of enamel organ.

Consists of cells that are star shaped with long processes reaching in all directions from central body. Neighboring cells are separated by wide intracellular spaces filled by large amount of ICS.

The cells are connected with each other and to the cells of stratum intermedia and OEE by desmosomes.



FUNCTION:

1. Elasticity and resistance: it acts as a buffer against physical forces that might distort developing DEJ, giving rise to gross morphology.
2. It permits only limited flow of nutritional elements from overlying blood vessels to formative cells.(when the first layer of the dentin is laid down, it collapses so bring the blood vessels more nearer.)

Reason for characteristic morphology...

The cells in the center of dental papilla continue to synthesize and secrete glycosaminoglycans into the extra cellular compartment between the epithelial cells which is hydrophilic and pull water in to dental organ which increases the volume of extra cellular compartment, so the cells are forced apart maintaining connections with each other through desmosomal contacts, creating star shape. So it is called stellate reticulum.

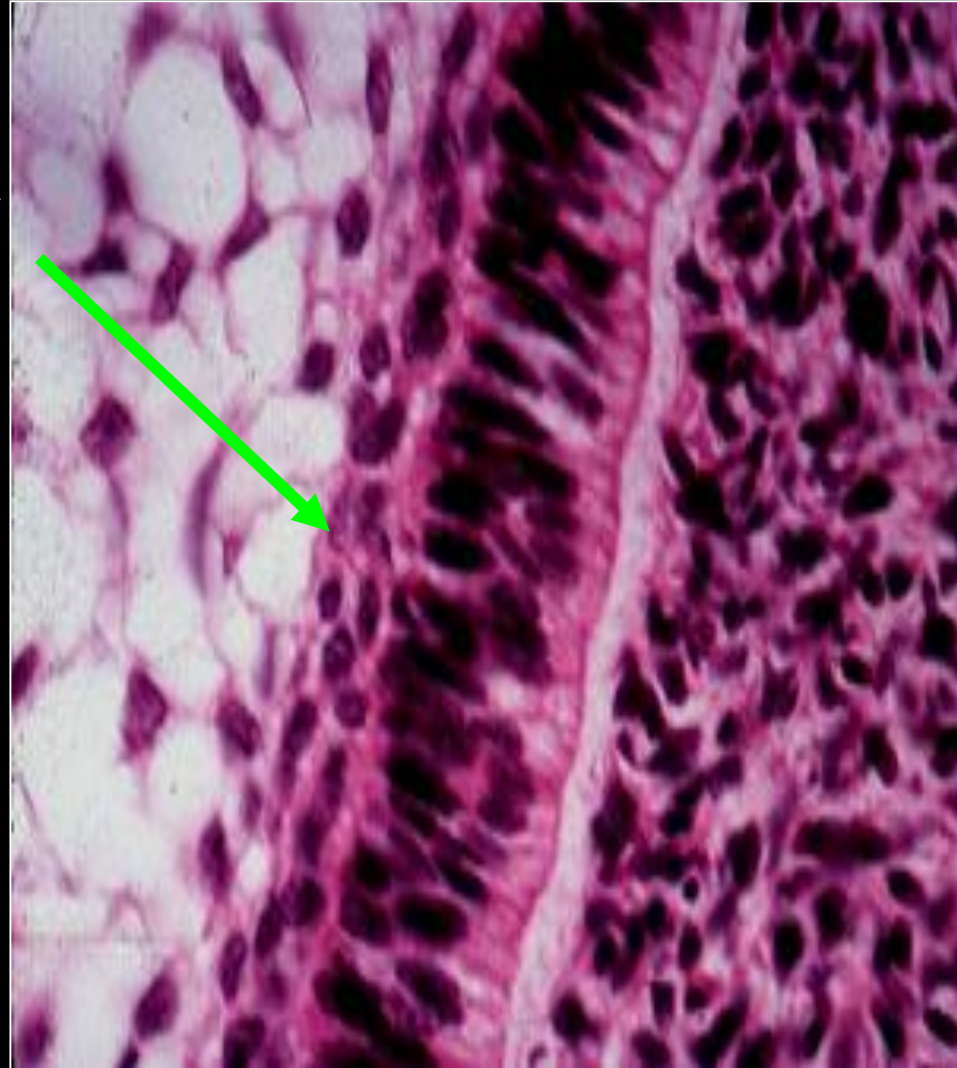
STRATUM INTERMEDIUM:

Flat or cuboidal cells.

Situated between stellate reticulum & OEE.

Function:

It is not fully understood, but it is believed to play role in production of enamel itself, either by control of fluid diffusion into and out of ameloblast or by the actual contribution of necessary formative elements or enzymes.



INNER ENAMEL EPITHELIUM:

Derived from basal cell layer of oral epithelium.

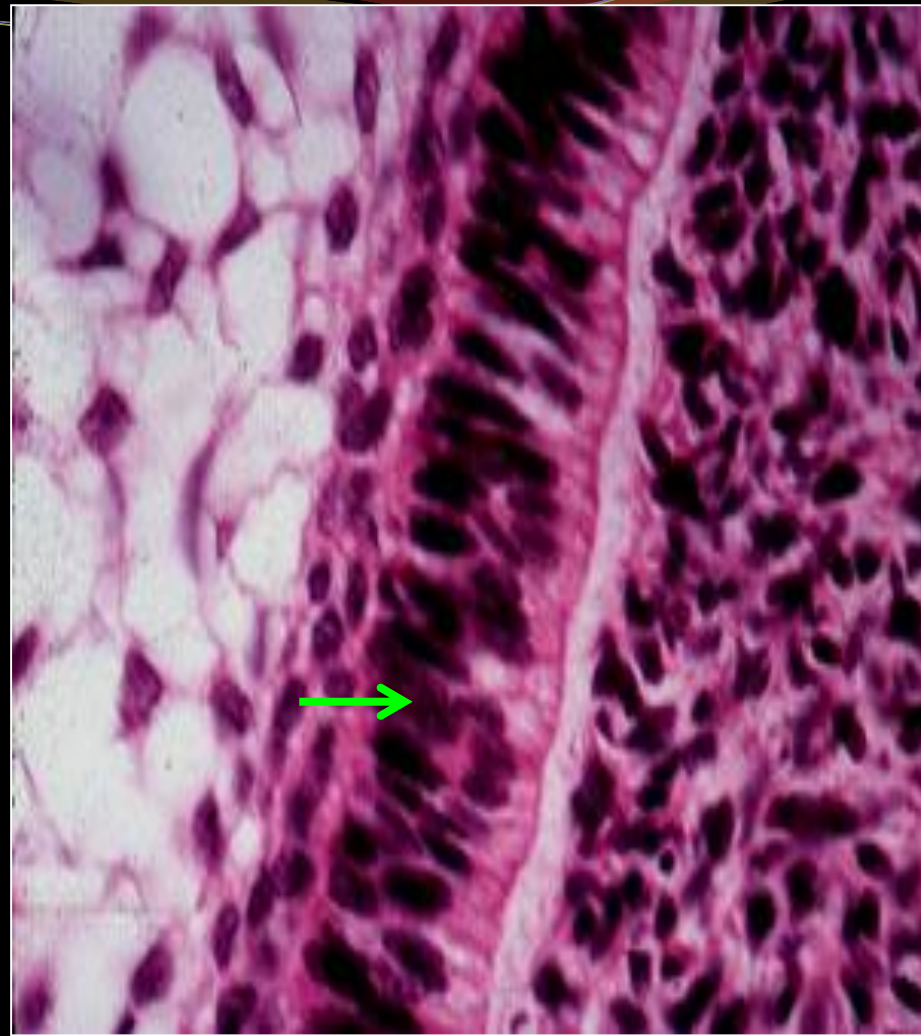
Before enamel formation begins, these cells assume a columnar form and differentiate into ameloblasts that produces enamel matrix.

Functions:

1. Determining crown pattern.
2. Induces differentiation of Odontoblasts from cells of dental papilla.
3. Enamel formation after differentiation into ameloblasts.

CERVICAL LOOP:

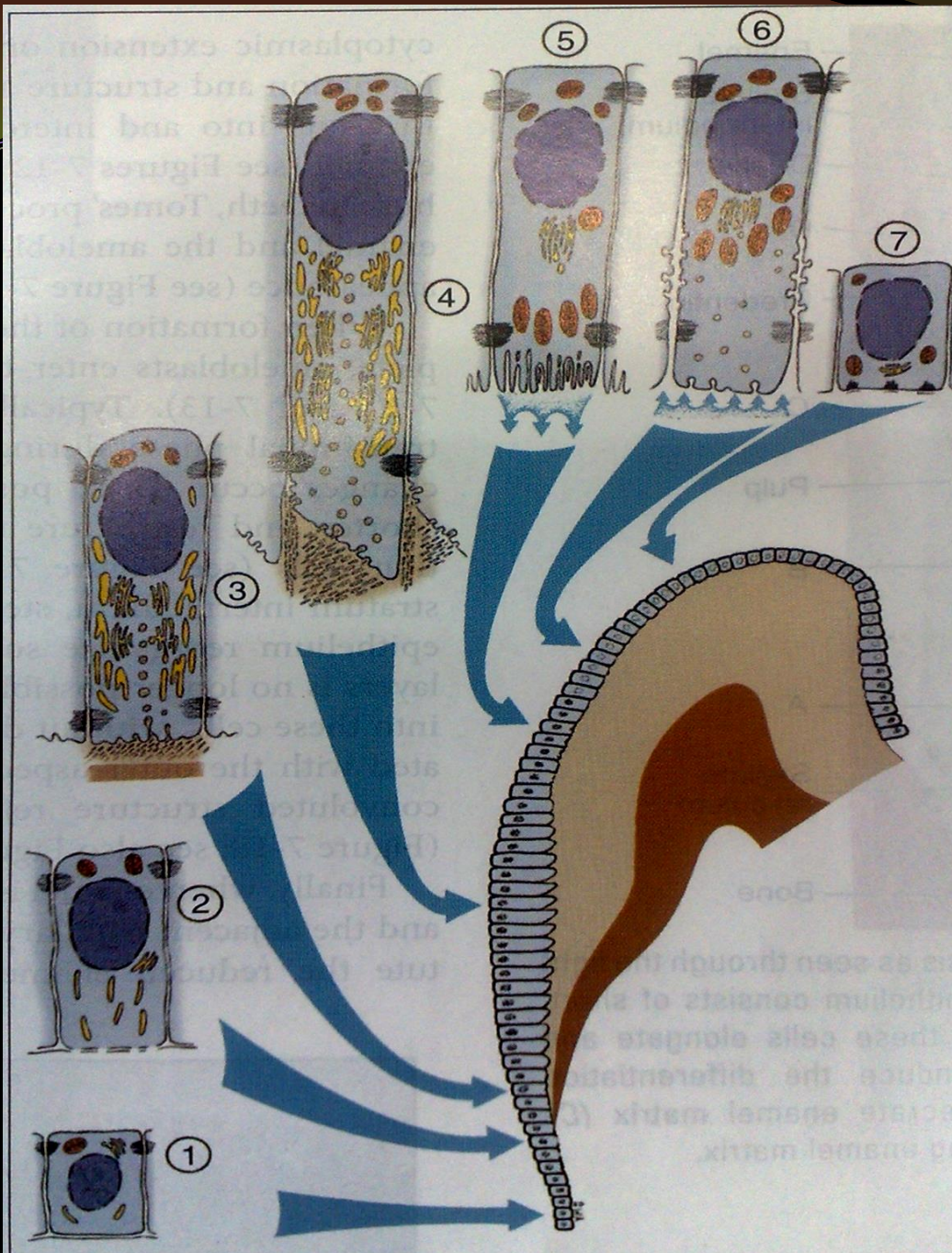
Function: When the crown has been formed, the cells of this portion give rise to Hertwig's epithelial root sheath.



LIFE CYCLE OF AMELOBLASTS:

According to function the life span of the cells of the inner enamel epithelium can be divided into six stages:

- 1. Morphogenic**
- 2. Organizing**
- 3. Formative**
- 4. Maturative**
- 5. Protective**
- 6. Desmolytic**




The various functional stages in the life cycle of the cells of the inner dental epithelium.

- 1, Morphogenetic stage;
- 2, Histodifferentiation stage;
- 3, Initial secretory stage (no Tomes' process);
- 4, Secretory stage (Tomes' process);
- 5, Ruffle-ended ameloblast of the maturative stage;
- 6, Smooth-ended ameloblast of the maturative stage;
- 7, protective stage.

MORPHOGENIC STAGE:

Before ameloblasts are fully differentiated, IEE interacts with adjacent mesenchymal cells determining shape of the DEJ and the crown.

During this stage, cells are short, columnar with large oval nuclei that almost fills the body,



**Morphogenetic
stage**

■ Golgi apparatus and centrioles are located in the proximal end of the cells and mitochondria are evenly dispersed throughout cytoplasm.

■ Terminal bars appear concomitantly with the migration of mitochondria to basal region of cells. Terminal bars represent point of close contact between cells.

■ They are believed to be thickening of apposing cell membrane associated with condensation of underlying cytoplasm.

■ Basal lamina separates IEE from CT.


■ There is presence of cell free zone consisting of argyrophilic fibers and cytoplasmic processes of superficial cells of pulp.

ORGANISING STAGE:

Change in the appearance of cells of IEE. They become longer.

Reversal of functional polarity takes place by migration of Golgi and centrioles to distal ends and mitochondria to proximal ends.

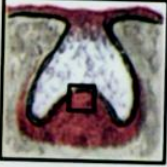Disappearance of cell free zone and so they come in contact with dental papilla cells and induce their differentiation into Odontoblasts.



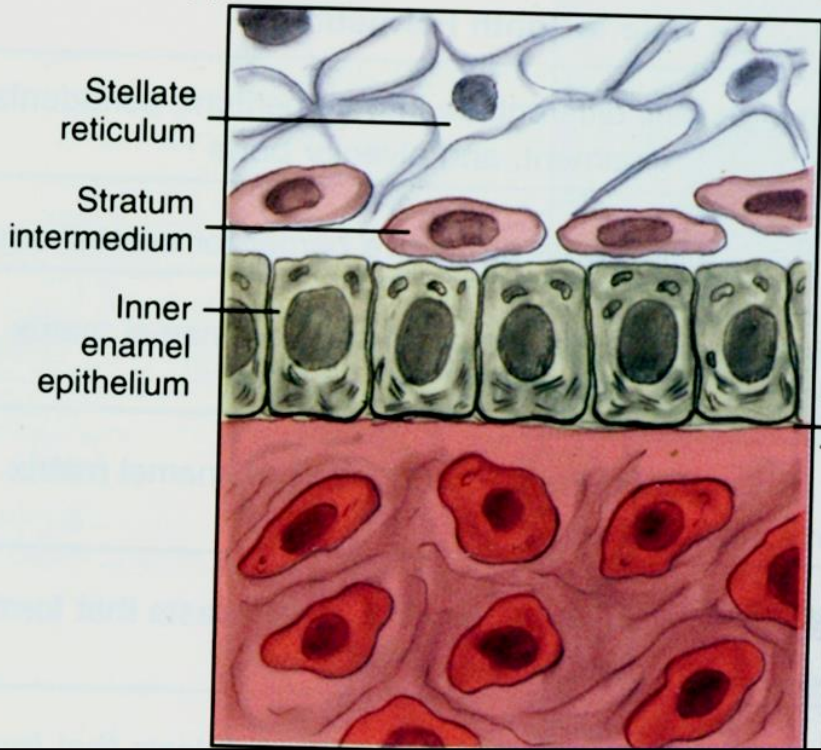
In late or terminal stage they begin to secrete dentin which is a critical phase in life cycle of IEE, it differentiates into ameloblast.

Along with this ameloblasts are cut off from their original source of nutrition that is CT of dental papilla, which is compensated by
Proliferation of capillaries adjacent to OEE.

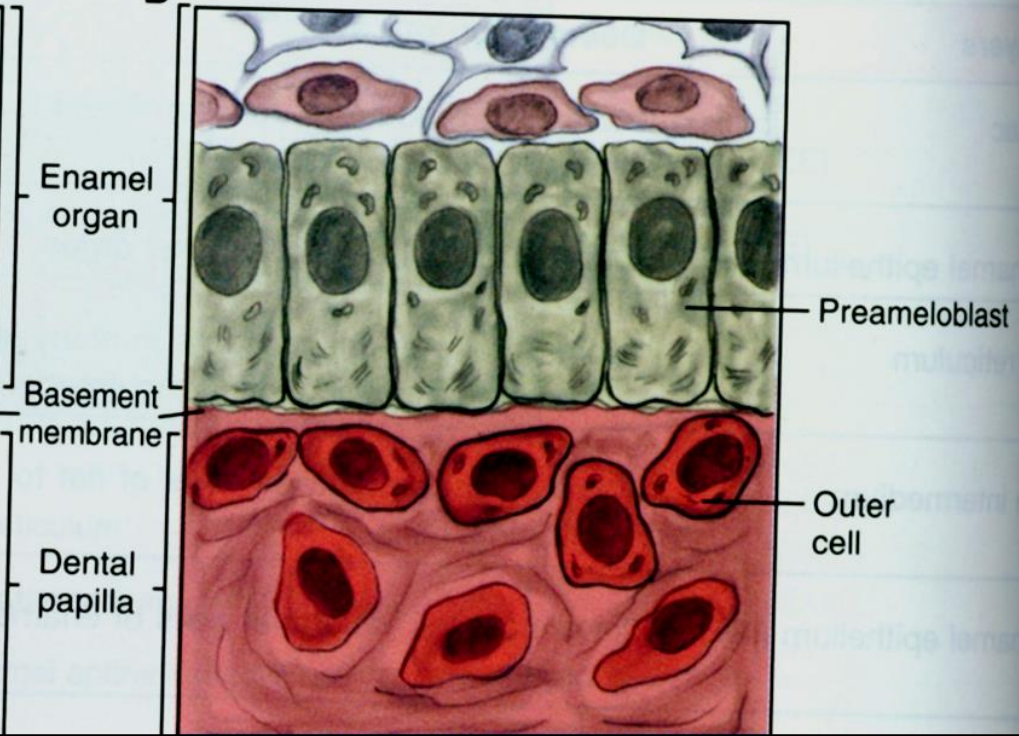
Reduction and gradual disappearance of stellate reticulum, thus minimizing the distance between capillaries.



A



B



Stellate reticulum

Stratum intermedium

Inner enamel epithelium

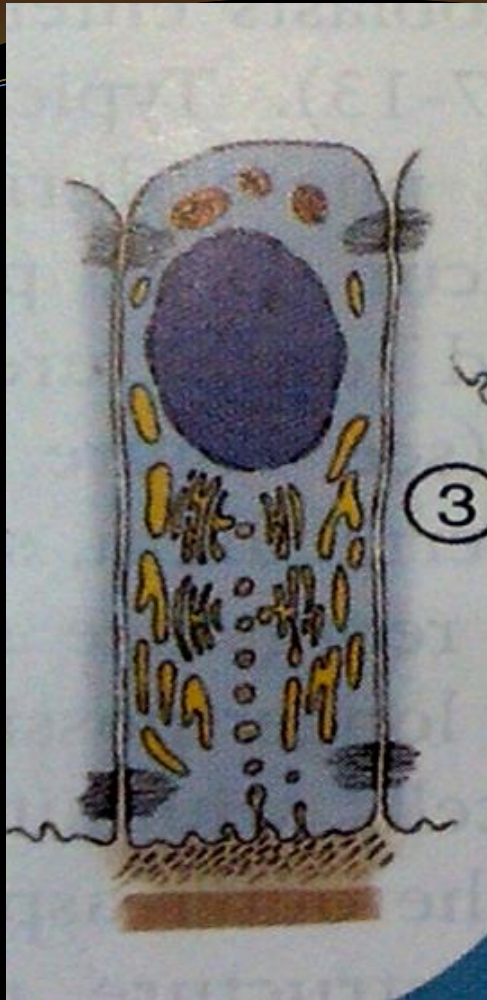
Enamel organ

Basement membrane

Dental papilla

Preameloblast

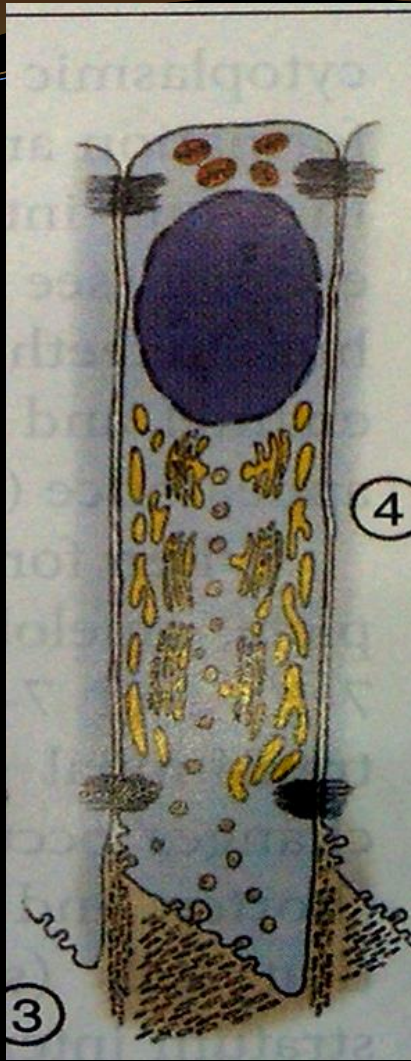
Outer cell



FORMATIVE STAGE:

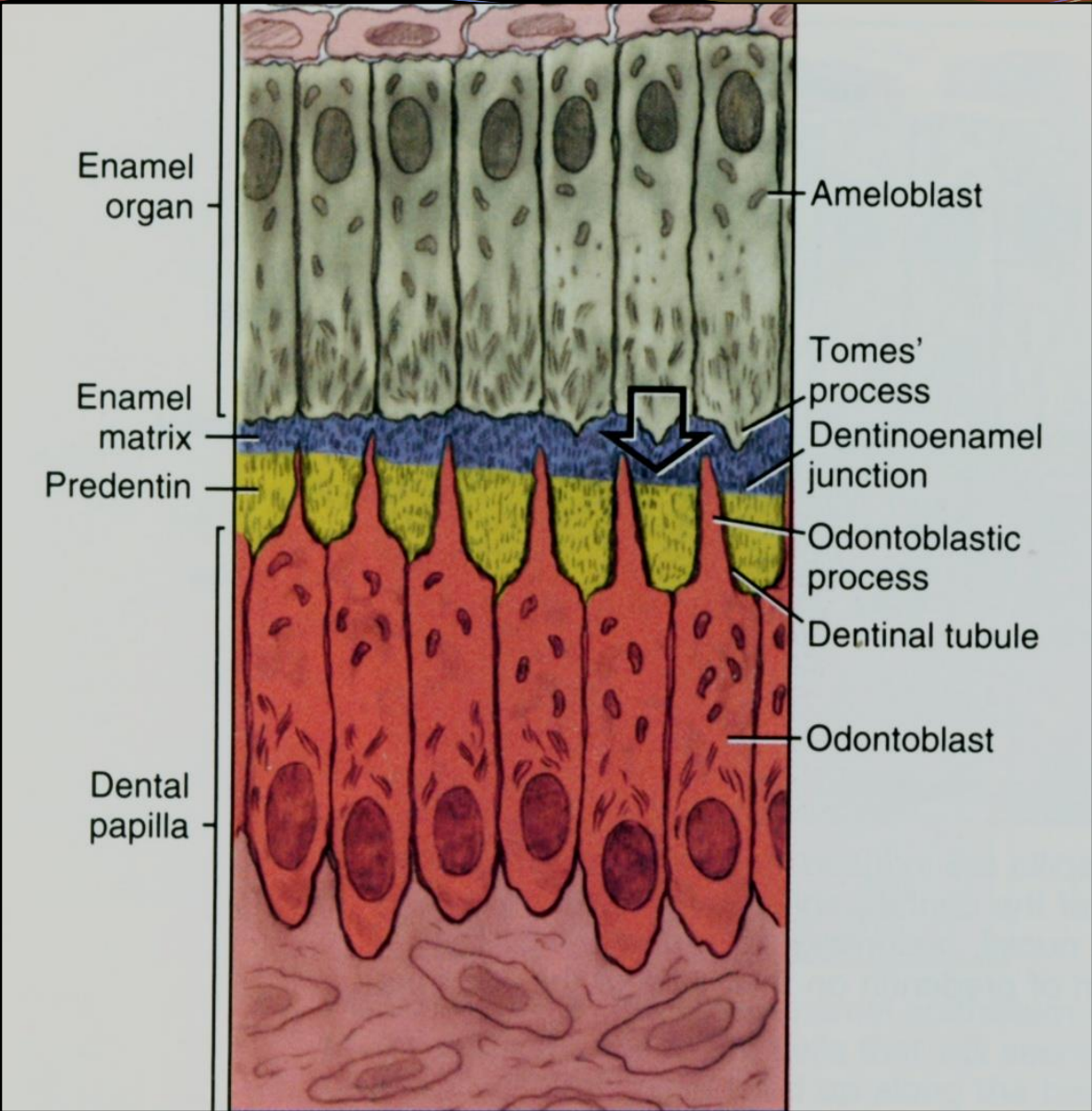
First layer of dentin is necessary for beginning of enamel matrix formation.

**Presecretory stage
(no Tomes process)**



During formation of enamel matrix earliest apparent change is development blunt cell processes on ameloblast surfaces, which penetrate the basal lamina and enter predentin (Tomes process).

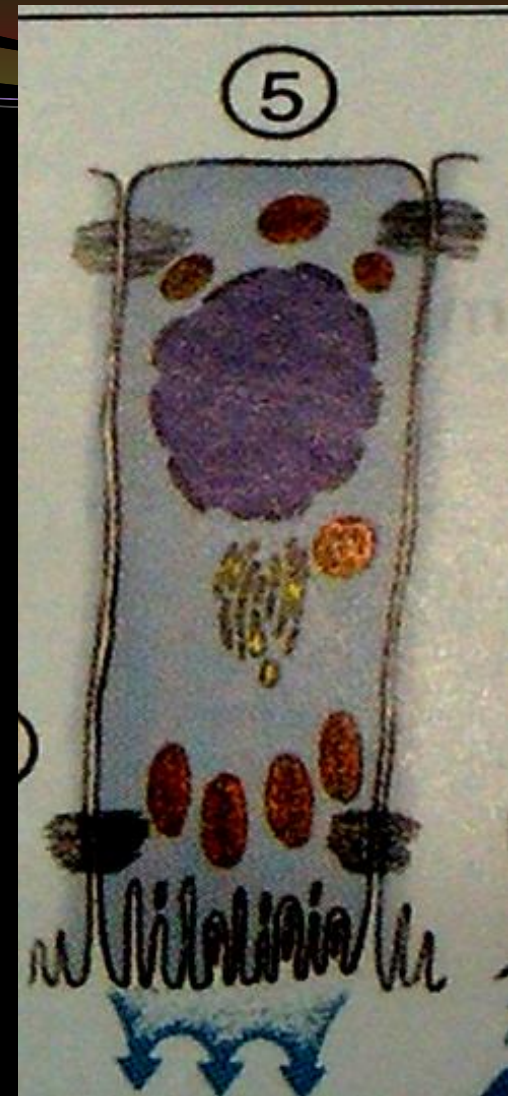**Secretory stage
(Tomes process)**



MATURATIVE STAGE:

Enamel maturation occurs after most of the thickness of enamel has been formed in occlusal or incisal area.

During this phase Ameloblasts are slightly decreased in length and are closely attached to enamel matrix, they display microvilli at distal end.

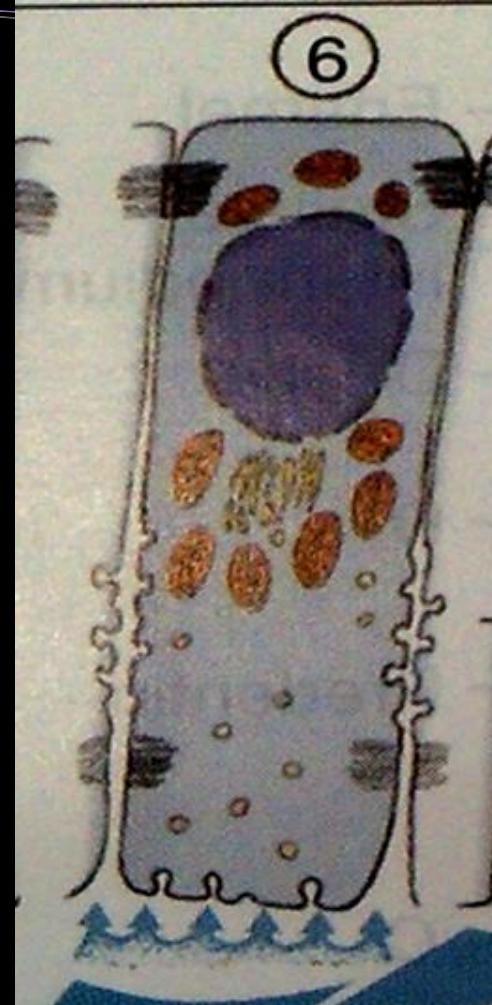


Ruffle ended ameloblasts of maturative stage

Stratum intermedium cells lose their cuboidal shape and regular arrangement and assume spindle shape.

Ameloblasts are involved in the maturation of enamel.

During maturation, ameloblasts display microvilli at their distal end, and cytoplasmic vacuoles containing material resembling enamel matrix are present. These structures indicate an absorptive function of these cells.

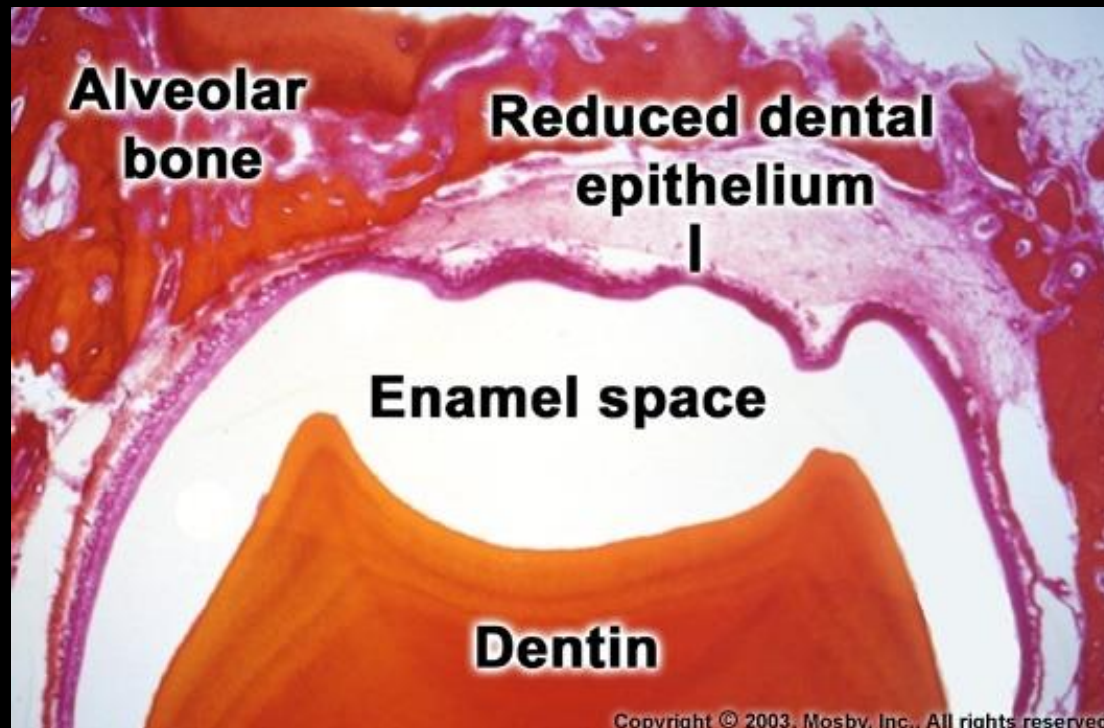


Smooth ended ameloblasts of maturative stage

PROTECTIVE STAGE:

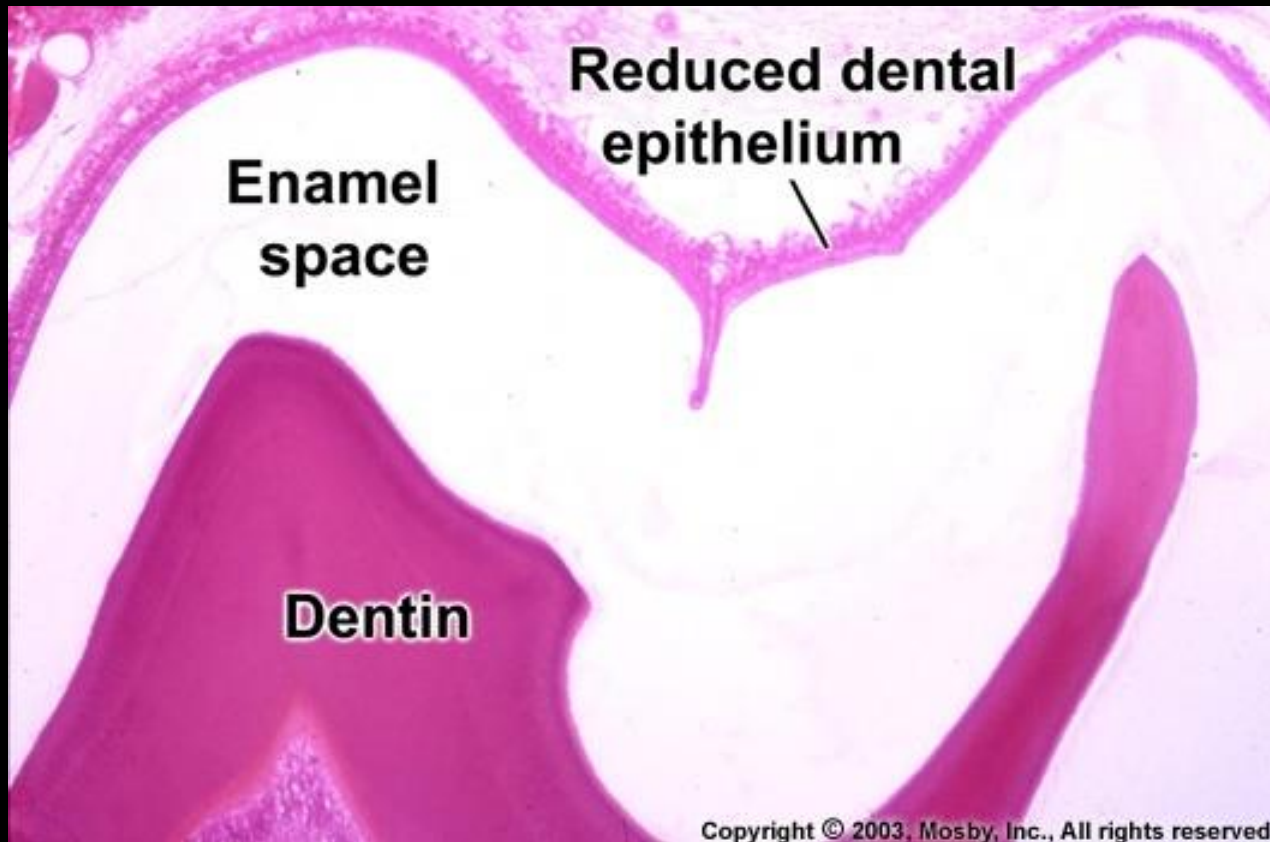
When enamel has completely developed and fully calcified, the ameloblast cease to be arranged in a well defined layer and can no longer be differentiated from cells of stratum intermedium and OEE.

These cell layers forms a stratified epithelial covering of the enamel, called reduced enamel epithelium.



Function of REE:

To protect the mature enamel from CT until tooth erupts.



DESMOLYTIC STAGE:

The reduce enamel epithelium proliferates and induces atrophy of the CT separating it from oral epithelium so that fusion of 2 epithelia can occur.

It is probable that REE cells elaborate enzymes that are able to destroy CT fibers by desmolysis.

Significance:

Premature degeneration of REE may prevent eruption of tooth.

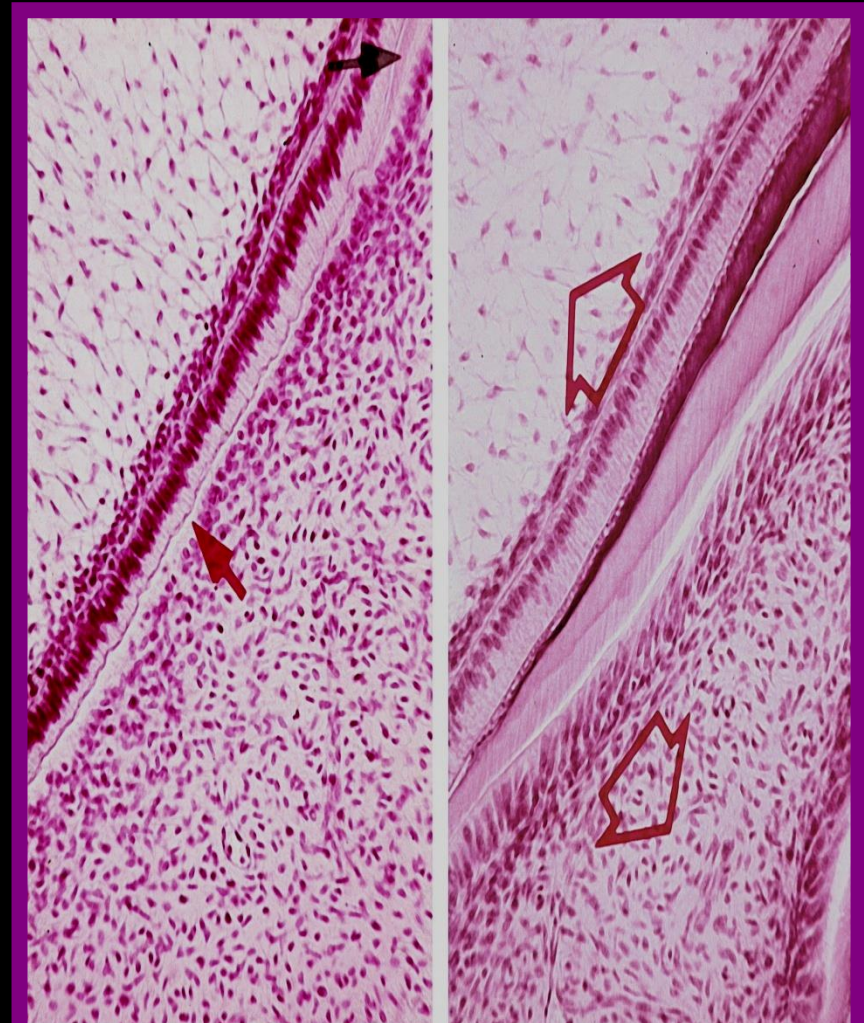
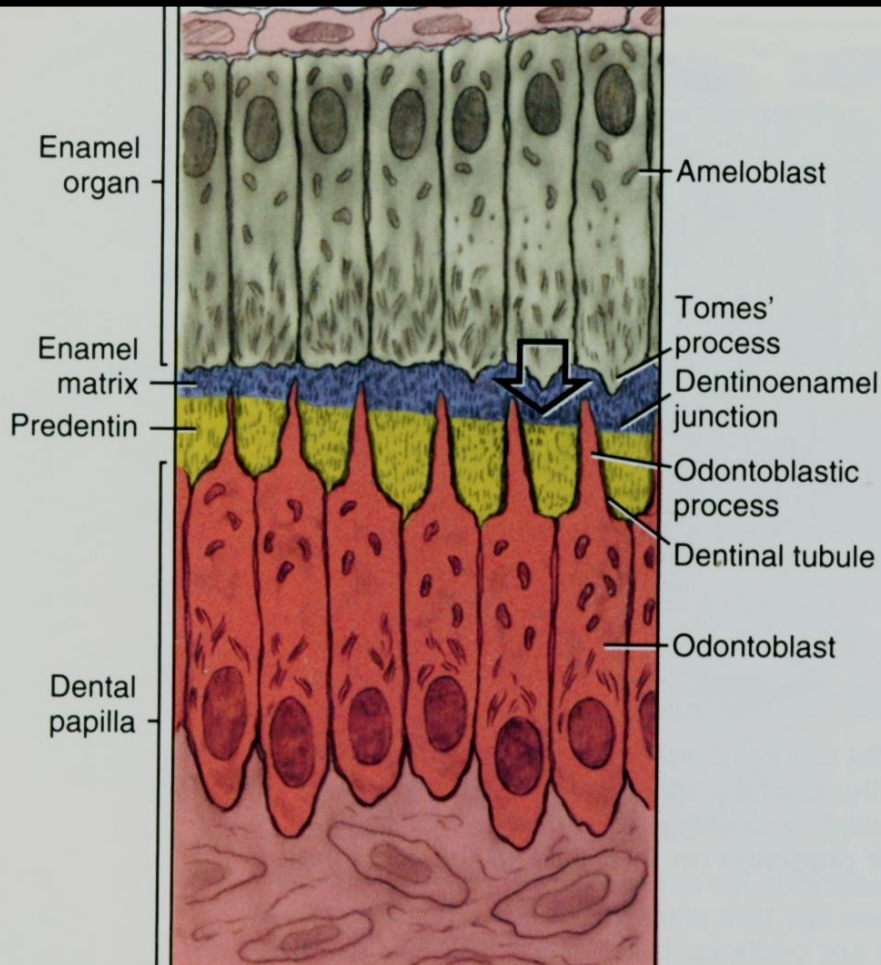
AMELOGENESIS

On the basis of ultra structure and composition, 2 processes are involved in development of enamel..

1. Organic Matrix formation (formation of amelogenin and nonamelogenis proteins[ameloblastin, enamelin, tuftelin])
2. Mineralization

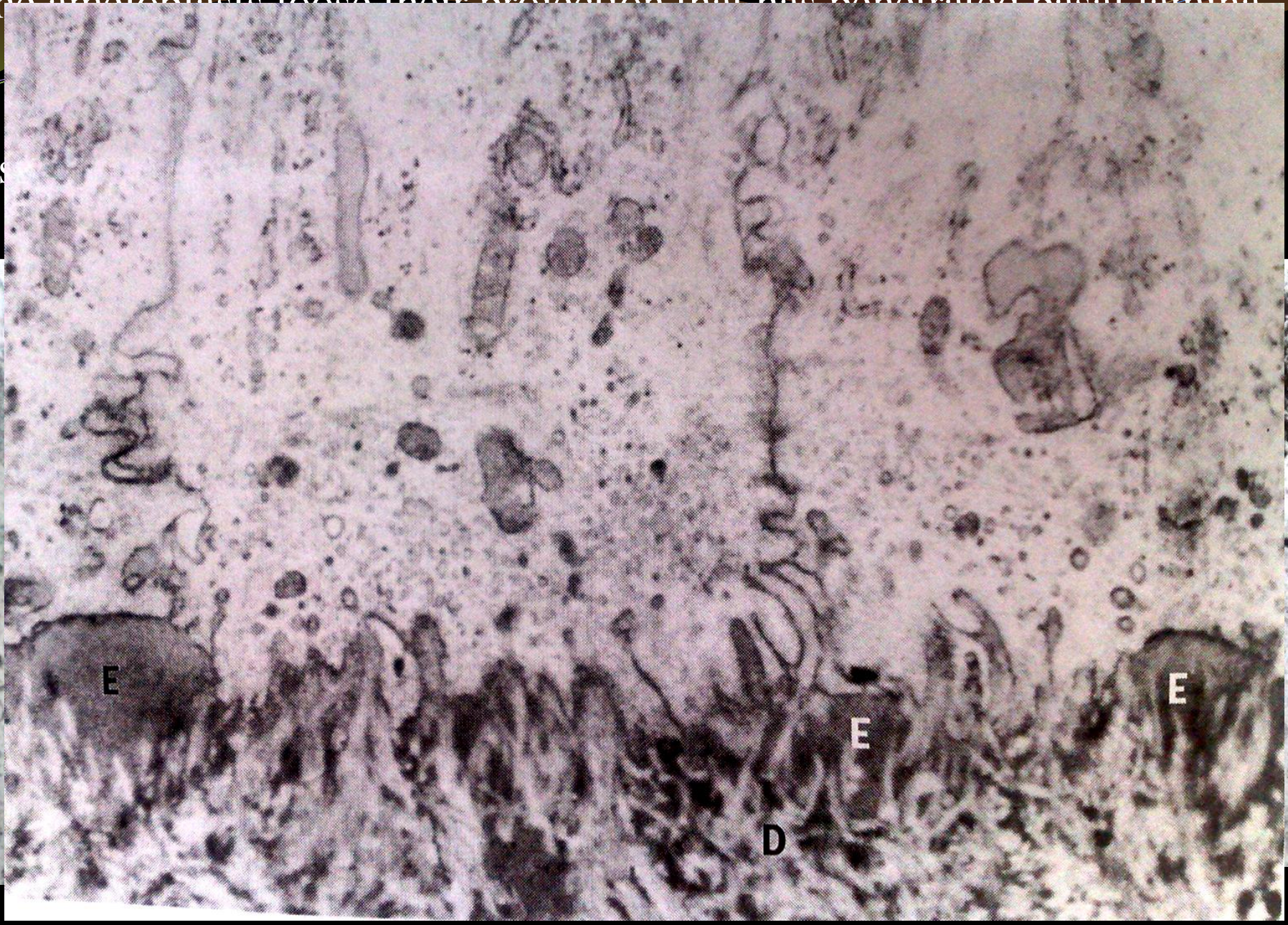
ORGANIC MATRIX FORMATION:

Ameloblasts begin their secretory activity when small amount of dentin has been laid down.



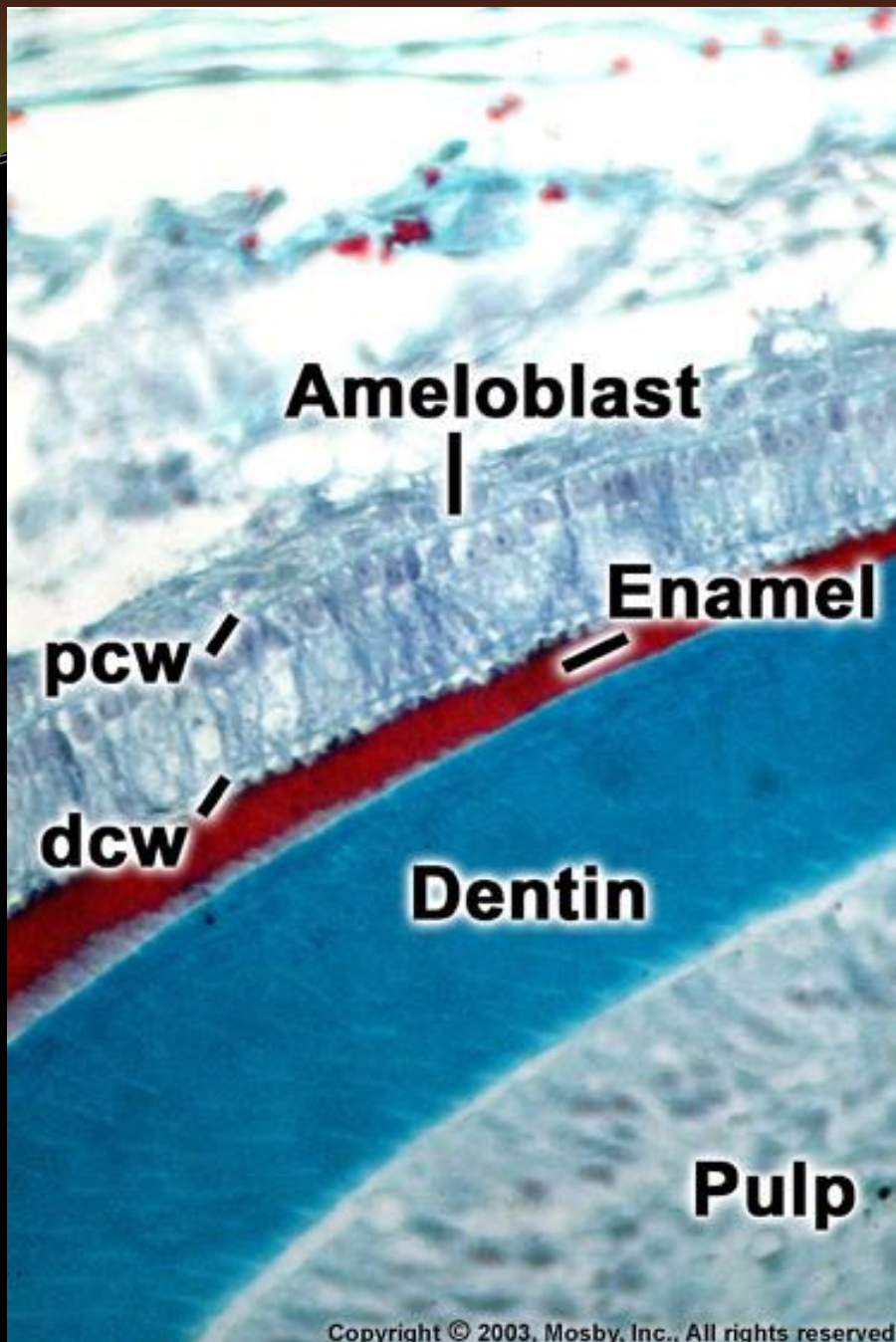
The ameloblasts lose their projection that has penetrated basal lamina

As



Development of TOMES' PROCESS:

As ameloblasts begin to secrete enamel matrix, they move away from the dentinal surface and so each cell forms a conical projection. This projection is called Tomes' process and this gives junction between enamel and ameloblast a picket fence or saw tooth appearance.




Pcw: proximal cell web
Dcw: distal cell web

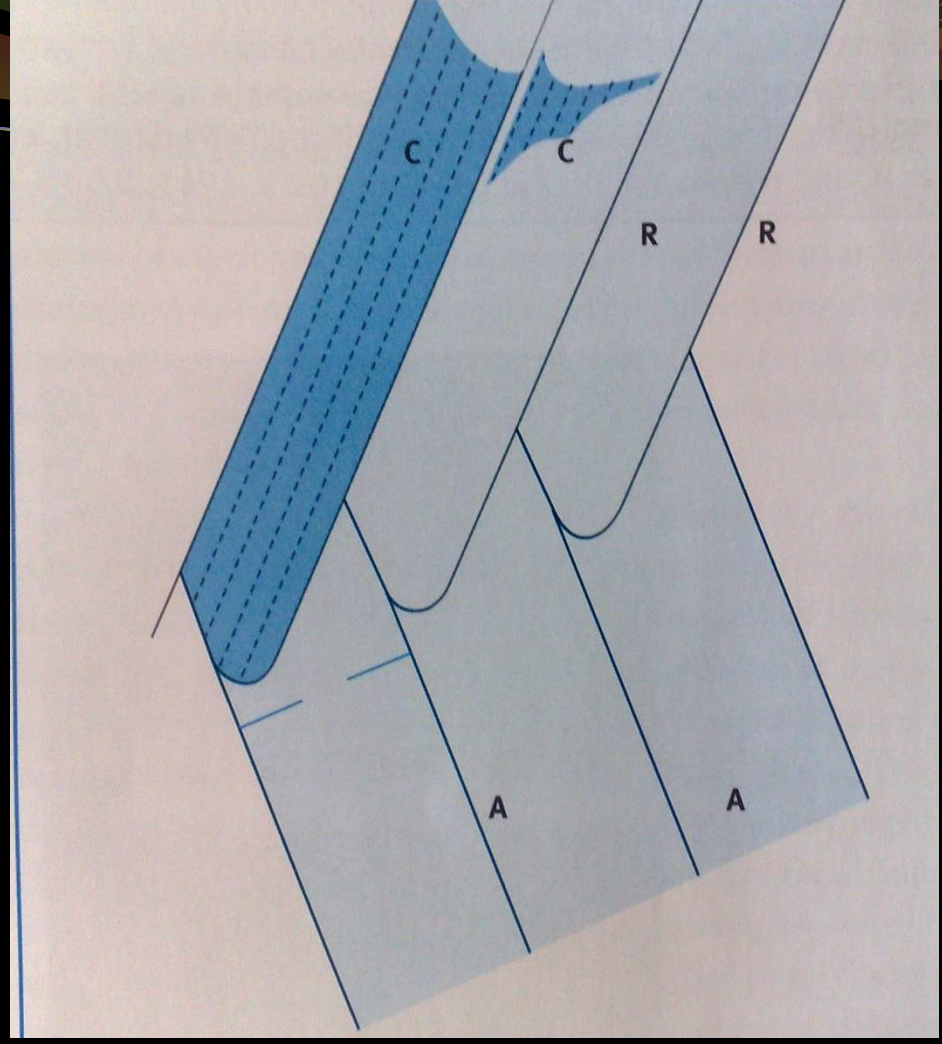
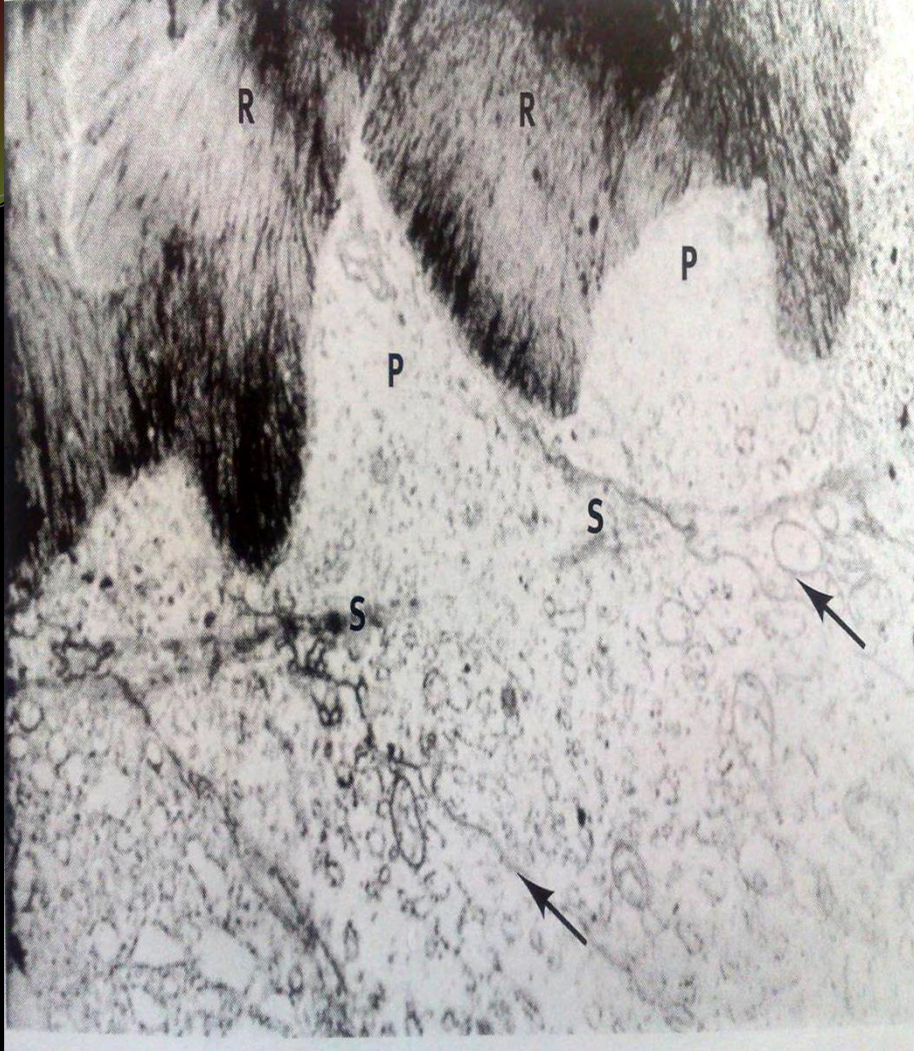


Enamel matrix formation as seen with the light microscope. The Tomes' processes of ameloblasts jut into the matrix, creating a **picket-fence appearance**.

This Tomes' process contains primary secretory granules and small vesicles where cell body cytoplasm contains abundant synthetic organelles.

Distinction between Tomes' process and cell body is clearly marked by distal terminal bars, which are localized condensation of cytoplasmic substance associated with thickened cell membranes.

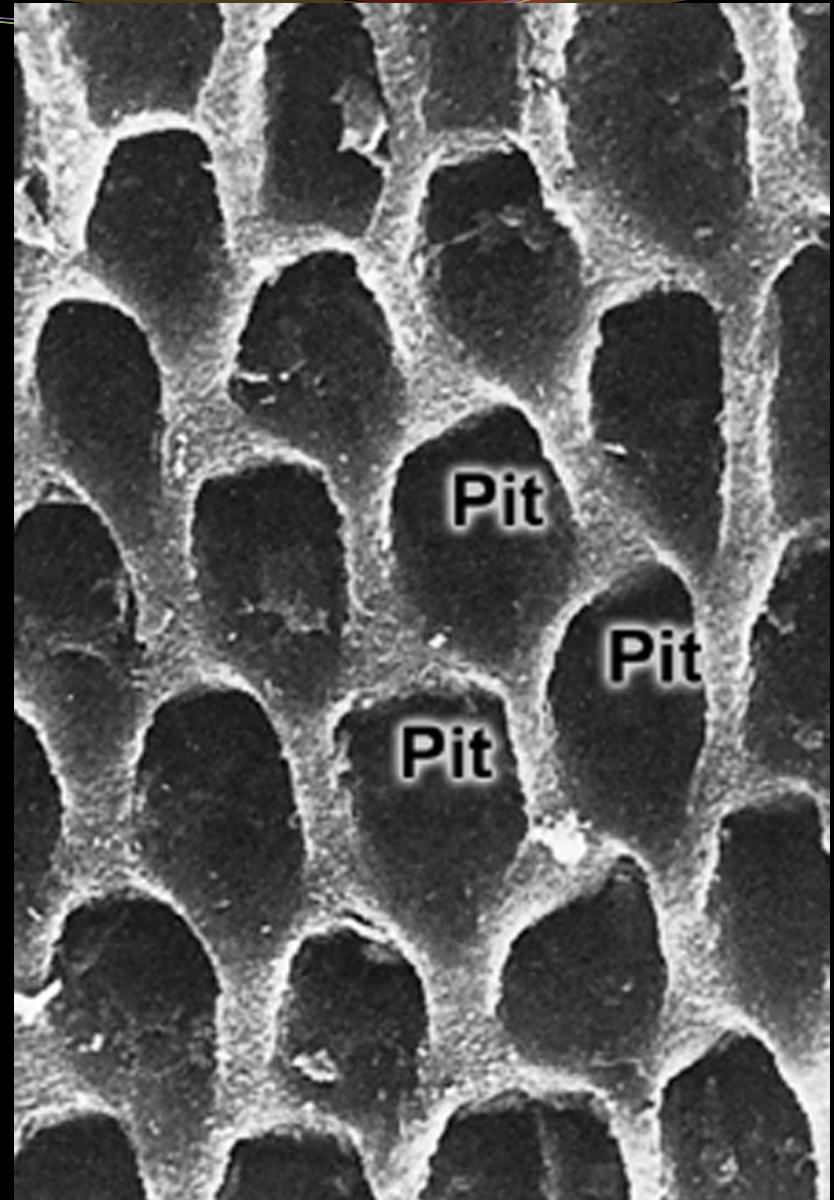




At least two ameloblasts are involved in the synthesis of each enamel rod.

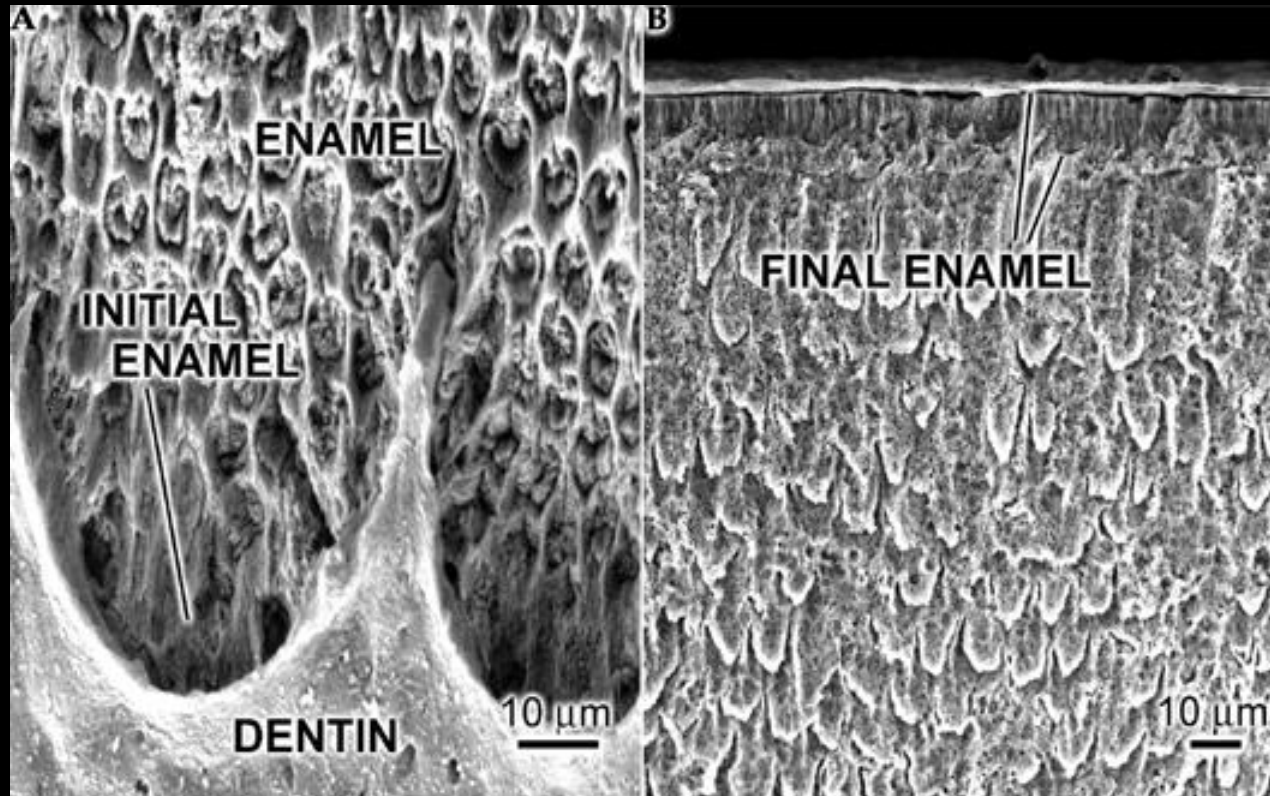
When the tomes process is established, the secretion of the enamel protein becomes staggered and confined to two sites..

1. Proximal parts of the process close to junctional complexes around periphery of cells, along with adjoining ameloblasts, which results in formation of enamel matrix wall. These walls enclosed a pit into which tomes process fits.
2. Secretion from surface of Tomes' process, which fills the pits, created previously.



This difference of secretion sites gives structure to enamel with walls becoming interrod enamel and rest is enamel rod.

Tomes' process persists until final few increments of enamel are formed and as a result this are structure less.



AMELOBLASTS COVERING MATURING ENAMEL

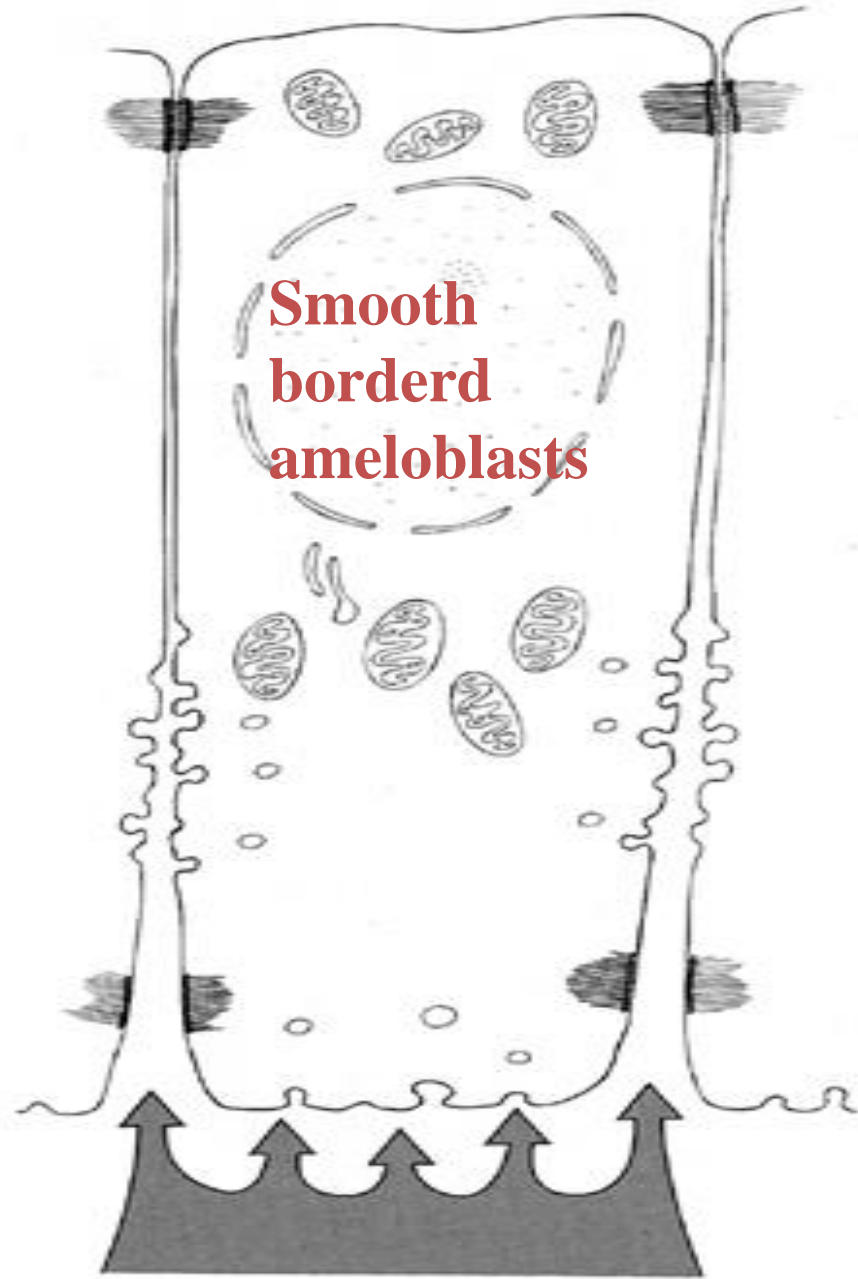
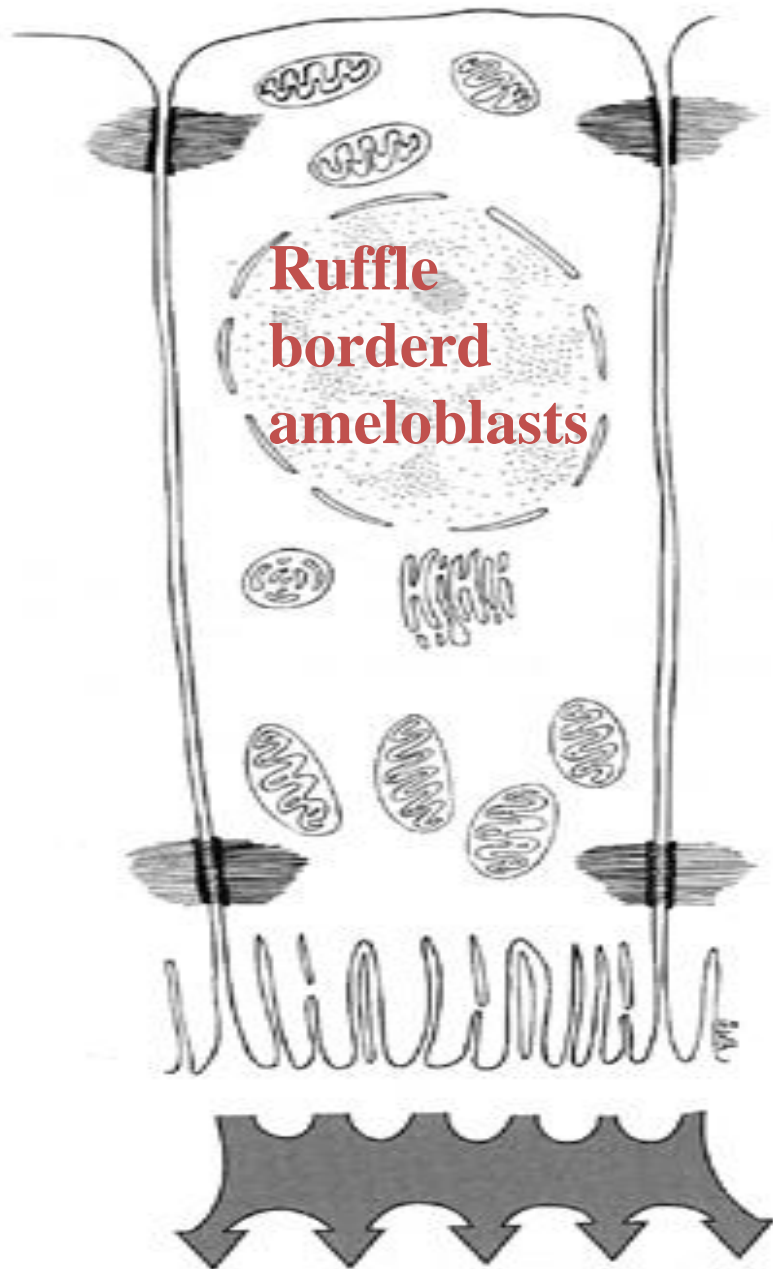
Transition stage: changes occurring in the ameloblasts after secretory stage and prior to the onset of maturation process. During this stage ameloblasts reduce in height, enamel secretion stops completely and the process of amelogenin removal starts. About 50% of ameloblasts undergo apoptosis.

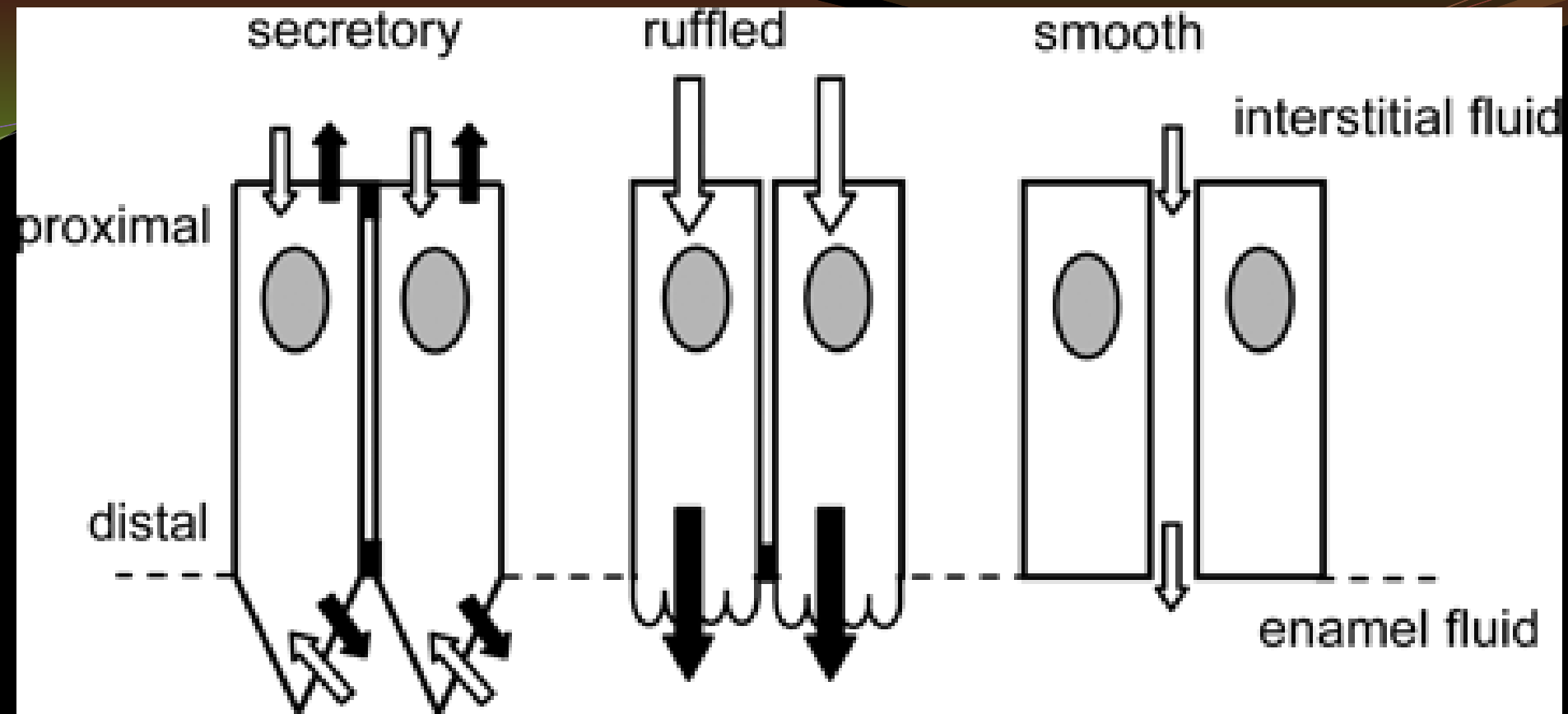
Modulation : ameloblasts alternate cyclically in developing smooth and ruffled borders in the apical cytoplasm during the maturative stage in a cervicoincisal direction. These changes are referred to as modulation.

MINERALISATION & MATURATION OF ENAMEL MATRIX:

Ameloblast covering maturing enamel: Ameloblasts are involved in a cyclic process where organic material is removed from the enamel matrix and minerals are introduced. This is reflected in the cell morphology, with cells alternating between possessing ...

1. A ruffle border (associated with introduction of inorganic material)
2. A smooth border (associated with removal of protein and water)





Calcium transport across the ameloblast layer (enamel epithelium) during the secretory stage of enamel formation and the ruffle-ended and smooth-ended phases of the maturation stage. Active calcium transport is indicated by black arrows, and passive transport is indicated by white arrows. Strontium transport is passive throughout.

Mineralization of enamel takes place in 2 stages:

I. Primary or partial mineralization:

In this stage immediate partial mineralization occurs in the matrix segments and interprismatic substance as they are laid down.

It accounts for 25-30% of total.

II. Maturation:

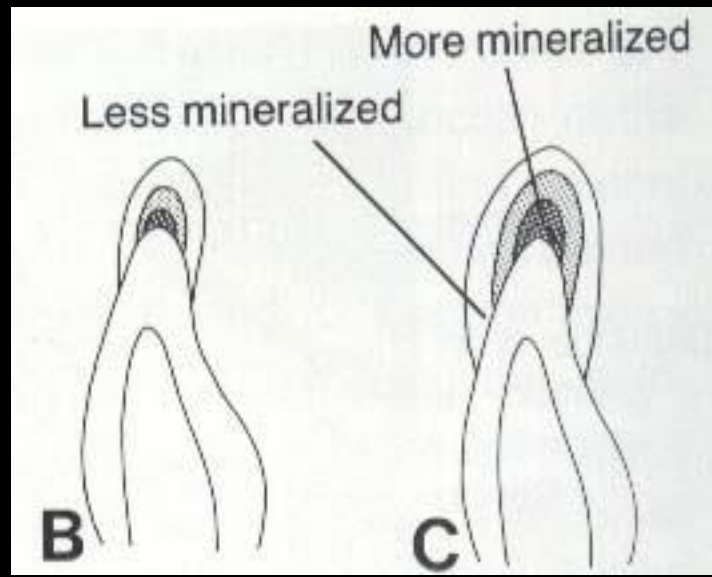
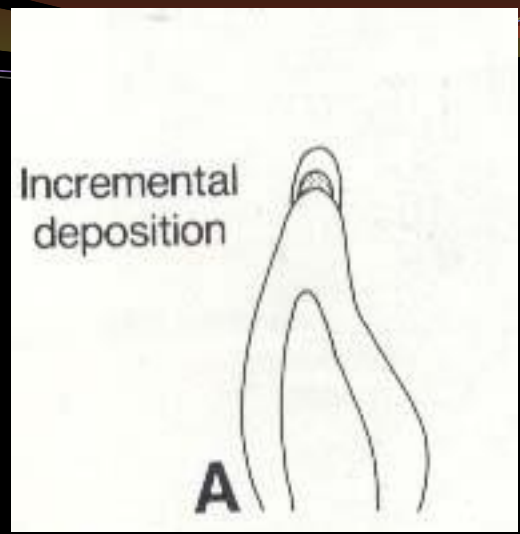
It is characterized by gradual completion of mineralization

It starts from the height of the crown and progresses cervical, however at each level maturation seems to begin at the dentinal end of rods.

Thus, there is an integration of 2 processes,

1. Each rod matures from the depth to surface.
2. Sequence maturing rods is from the cusps or incisal edge toward cervical line.



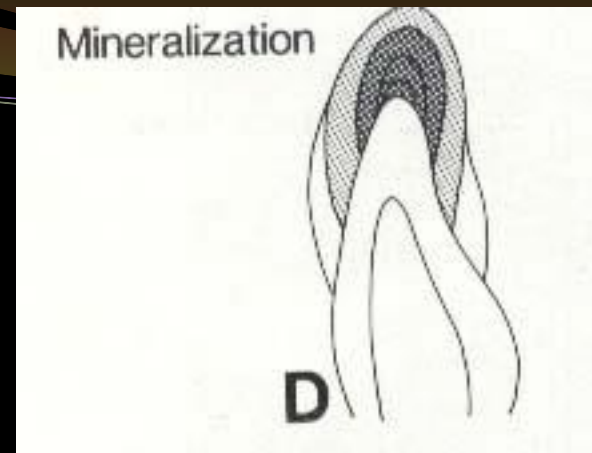
Maturation begins before the matrix has reached its full thickness.


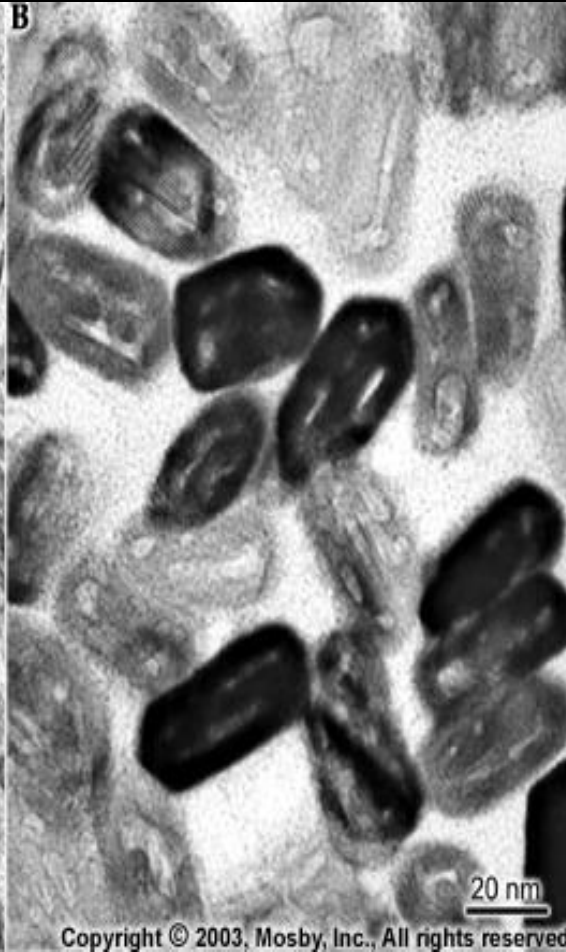


The advancing front is 1st parallel to DEJ and later to outer enamel surface following this pattern, the incisal and occlusal regions reach maturity ahead of cervical regions.

At ultra structural level, maturation is characterized by growth of crystals seen in primary phase.

Original ribbon shaped crystals increase in thickness more rapidly than width. To permit such an increase, most of the enamel protein must be displaced and removed, a function that is well accomplished by ameloblasts.



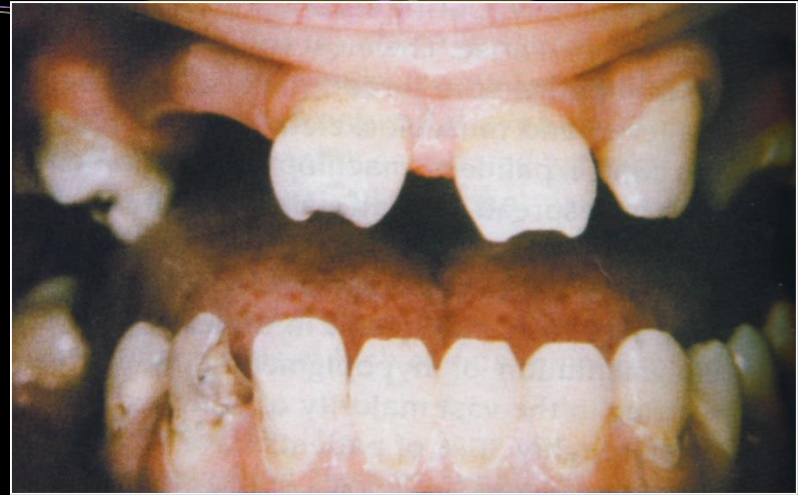
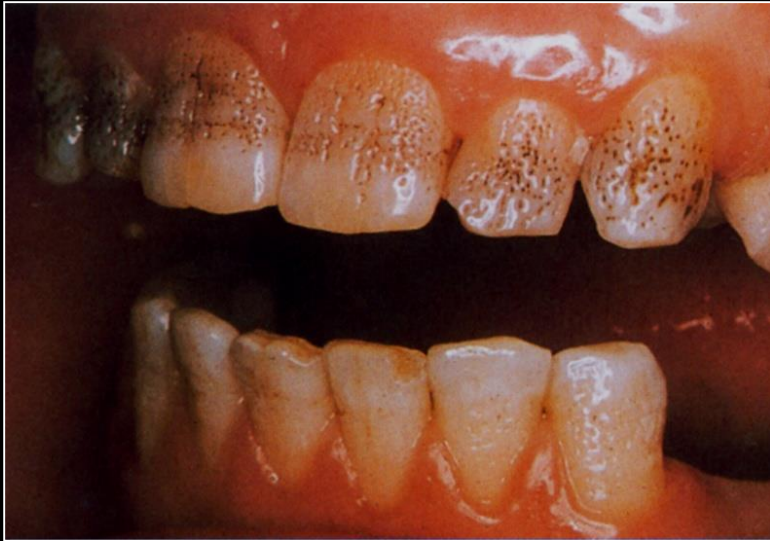
Copyright © 2003, Mosby, Inc., All rights reserved.

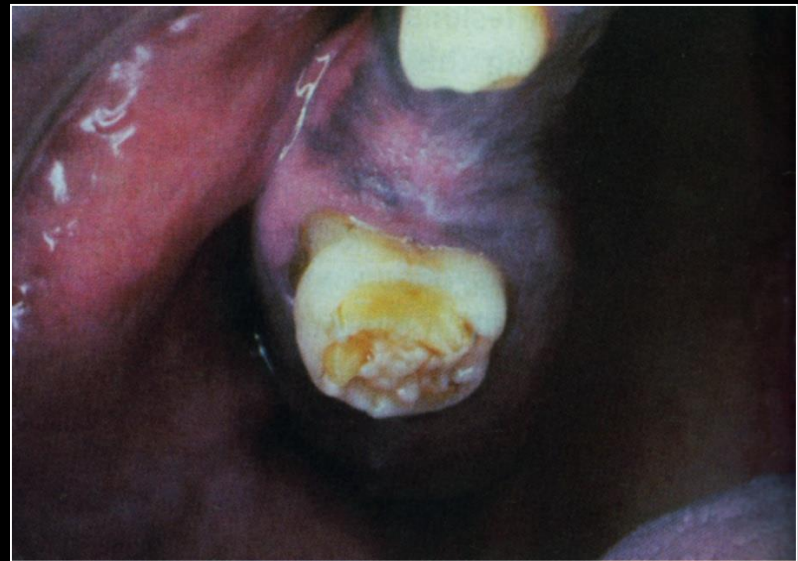
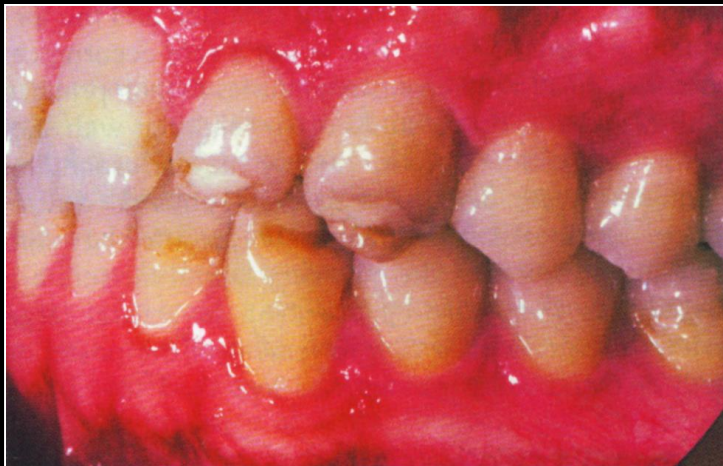Copyright © 2003, Mosby, Inc., All rights reserved.

Growth of hydroxyapatite crystals

Enamel hypoplasia

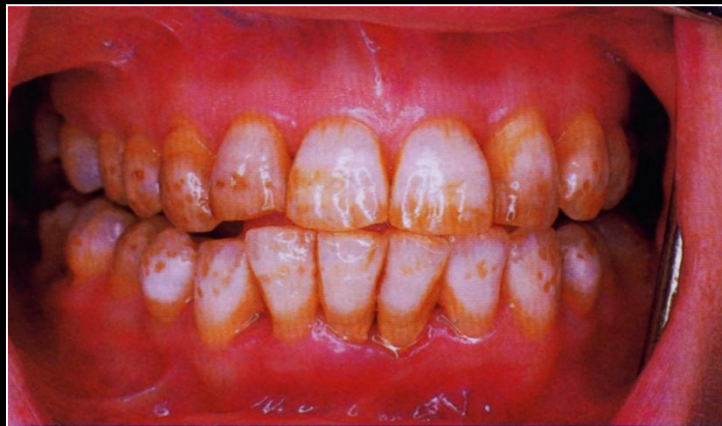
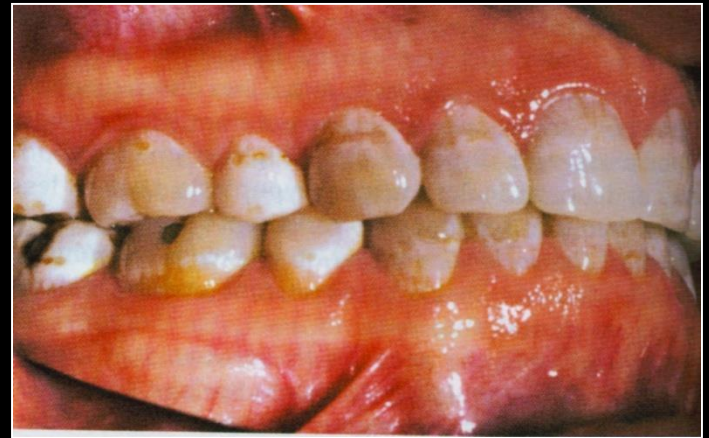
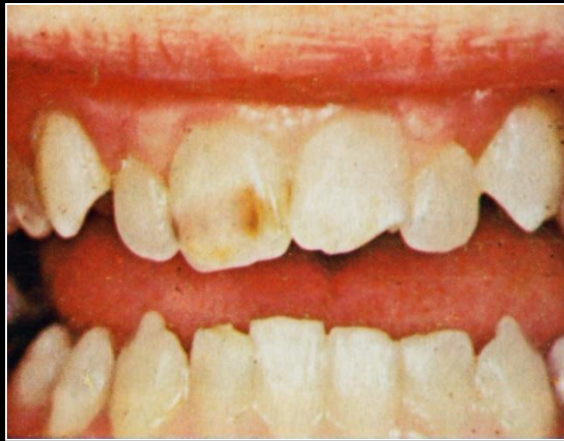Hutchinson's incisors



Mulberry molar

Fluorosis





THANK YOU