

THE PERMANENT MAXILLARY FIRST MOLAR

DEPARTMENT OF ORAL AND MAXILLOFACIAL PATHOLOGY & ORAL
MICROBIOLOGY



INTRODUCTION

The crown of this tooth is wider buccolingually than mesiodistally. Usually the extra dimension buccolingually is about 1 mm.

The maxillary first molar is normally the largest tooth in the maxillary arch. It has four well-developed functioning cusps and one supplemental cusp.

The four large cusps of most physiologic significance are the Mesiobuccal, the distobuccal, the mesiolingual, and the Distolingual. A supplemental cusp is called the **cusp or tubercle of Carabelli**.

This morphological trait can take the form of a well-developed fifth cusp or it can grade down to a series of grooves, depressions, or pits on the mesial portion of the lingual surface.

This cusp is found lingual to the mesiolingual cusp, which is the largest of the well-developed cusps.

Its used to identify the maxillary first molar. A specimen of this tooth showing no trace of its typical characteristic would be rare.

There are **three roots** : The Mesio Buccal, distobuccal, and lingual. There roots are well separated and well developed.

The lingual root is the longest root. It is tapered and smoothly rounded.

The Mesio Buccal root is not as long, but it is broader buccolingually.

The distobuccal root is the smallest of the three and smoothly rounded.

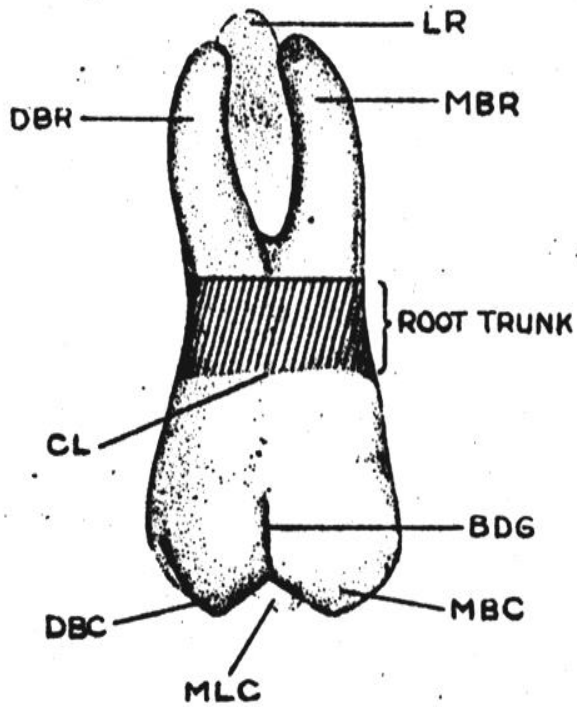


Figure 11-3. Maxillary right first molar, buccal aspect. *DBR*, Distobuccal root; *LR*, lingual root; *MBR*, mesiobuccal root; *CL*, cervical line; *DBC*, distobuccal cusp; *MLC*, mesiolingual cusp; *BDG*, buccal developmental groove; *MBC*, mesiobuccal cusp.

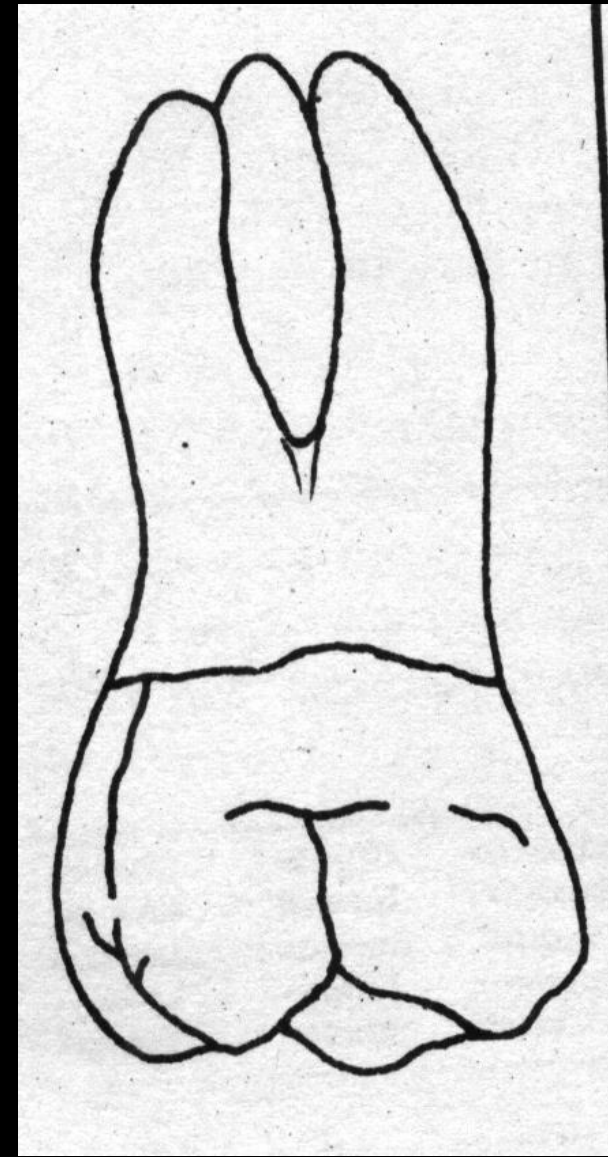
BUCCAL ASPECT:

The crown is roughly **trapezoidal**, with cervical and occlusal outlines representing the uneven sides. The cervical line is the shorter of the uneven sides.

The Mesio Buccal cusp is broader than the distobuccal cusp. The distobuccal cusp is sharper than the Mesio Buccal cusp.

The **buccal development groove** that divides the two buccal cusp is approximately equidistant between the Mesio Buccal and Distolingual line angles.

The groove slants occluso-apically in a line of direction parallel to the long axis of the distobuccal root.



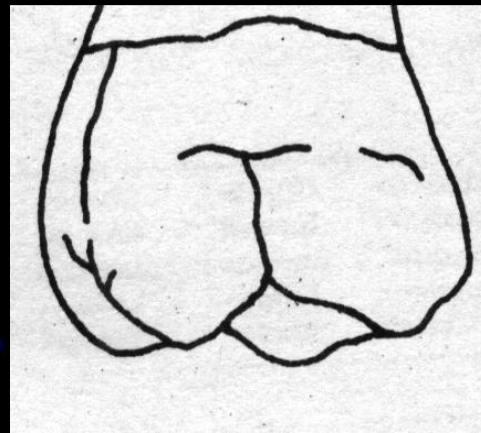
RIGHT SIDE

It terminates at a point approximately half the distance from its origin occlusally to the cervical line of the crown.

Although the groove is not deep at any point, it becomes more shallow toward its termination, gradually fading out.

Lateral to its terminus, there is a dip in the enamel of the crown that is developmental in character and that extends for some distance mesially and distally.

The **cervical line** of the crown does not have much curvature from mesial to distal. The line is generally convex with the convexity toward the roots.



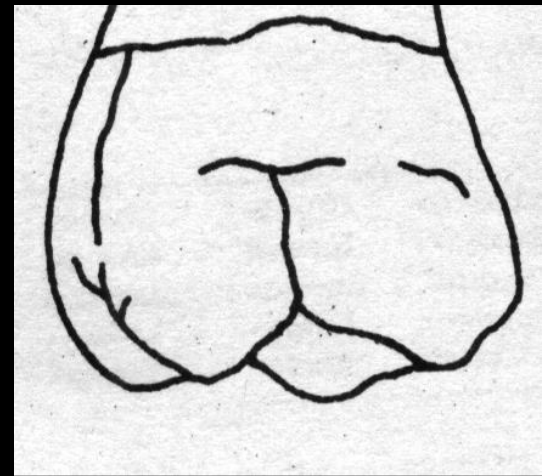
The **mesial outline** of the crown from this aspect follows a nearly straight path downward and mesially, curving occlusally as it reaches the crest of contour of the mesial surface, which is the contact area.

This crest is approximately two thirds the distance from cervical line to tip of mesiobuccal cusp.

The mesial outline continues downward and distally and becomes congruent with the outlines of the mesial slope of the Mesiobuccal cusp.

The distal outline of the crown is convex; the distal surface is spheroidal.

The crest of curvature on the distal side of the crown is located at a level approximately half the distance from cervical line to tip of cusp. The distal contact area is in the middle of the middle third.

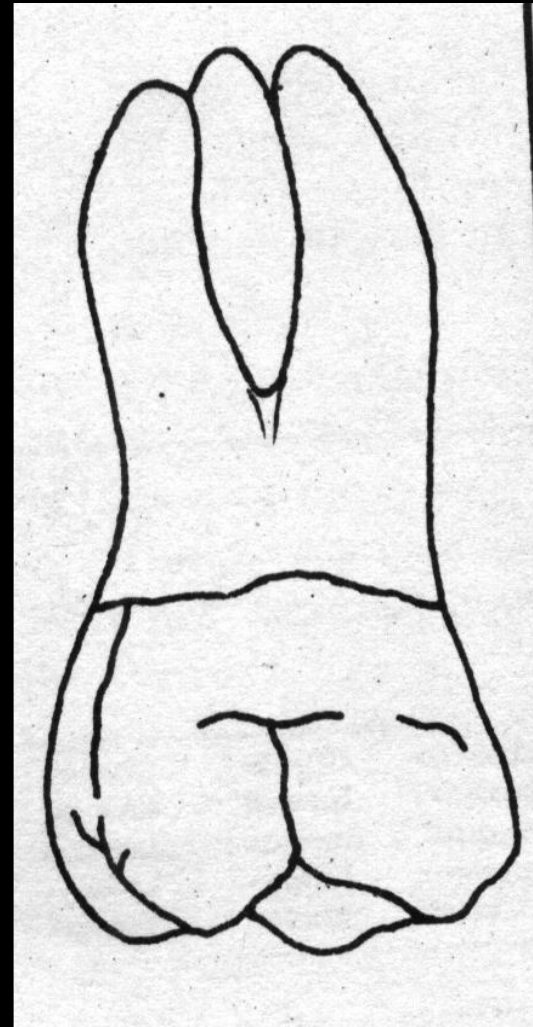


All three of the roots may be seen from the buccal aspect. The axes of the roots are inclined distally.

The roots are not straight, however, the buccal roots showing an inclination to curvature halfway between the point of bifurcation and the apices.

The Mesiobuccal roots curves distally, starting at the middle third. Its axis usually is at right angles to the cervical line.

The distal root is straighter, with its long axis at an acute angle distally with the cervical line. It has a tendency toward curvature mesially at its middle third.



The point of bifurcation of the two buccal roots is located approximately 4 mm above the cervical line.

This measurement varies somewhat, of course. Nevertheless, the point is much farther removed from the cervical line than in the deciduous molars.

This relation is typical when all permanent molars are compared with all deciduous molars.


There is a deep developmental groove buccally on the root trunk of the maxillary first molar, which starts at the bifurcation and progresses downward, becoming more shallow until it terminates in a shallow depression at the cervical line.

Sometimes this depression extends slightly onto the enamel at the cervix

Molars roots originate as a single root of the base of the crown.

They then are divided into three roots, as in the maxillary molars, or into two roots, as in the mandibular molars.

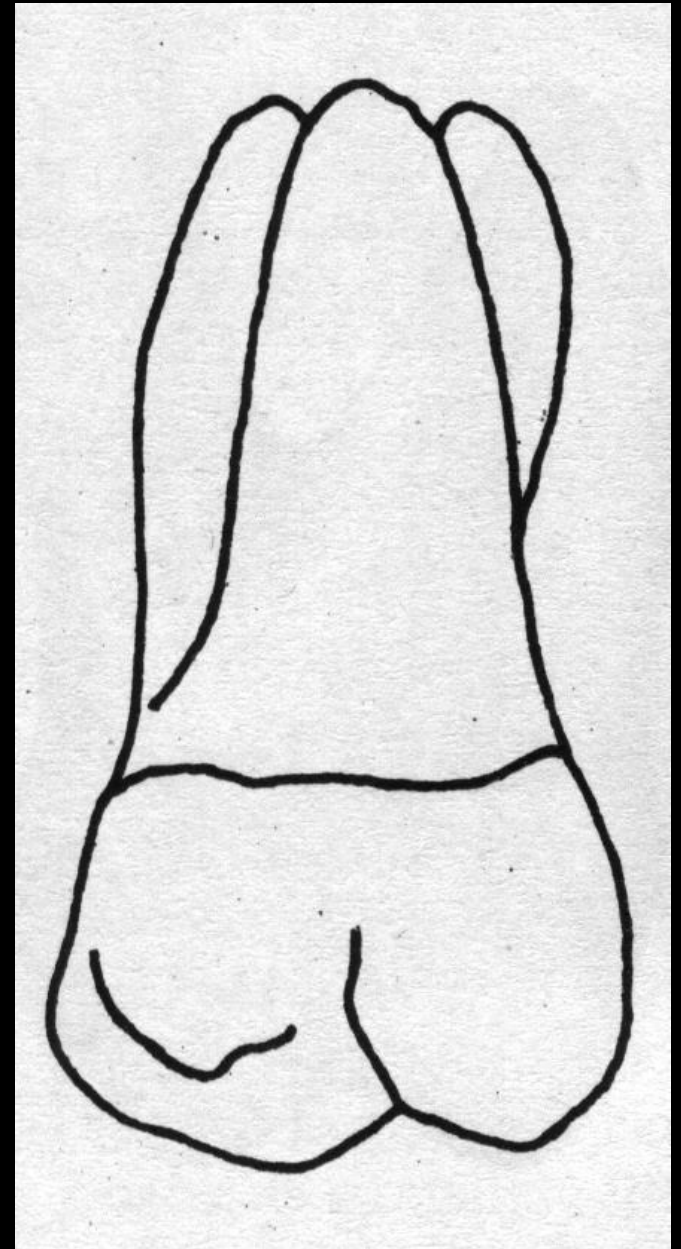
The common root base is called the root trunk.



LINGUAL ASPECT:

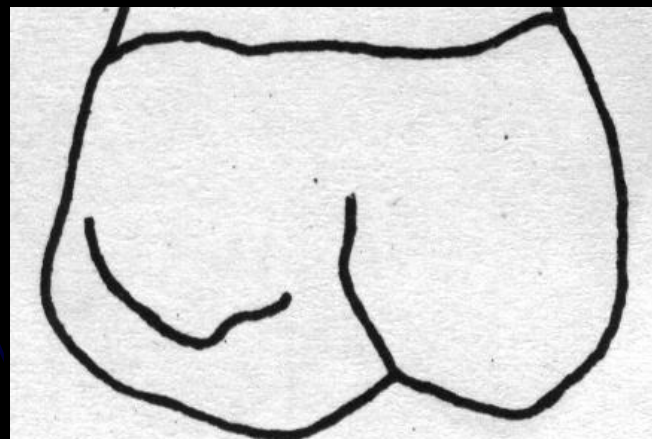
From the lingual aspect, the gross outline of the maxillary first molar is the reverse of that from the buccal aspect.

The variation between the outline of the mesial surface and that of the distal surface is apparent.



Because of the roundness of the Distolingual cusp, the smooth curvature of the distal outline of the crown becoming confluent with the curvature of the cusp creates an arc that is almost a semicircle.

The line that describes the **lingual developmental groove** is also confluent with the outline of the Distolingual cusp, progressing mesially and cervially and ending at a point at the approximate center of the lingual surface of the crown



A shallow depression in the surface extends from the terminus of the lingual groove to the center of the lingual surface of the lingual root at the cervical line and then continues in an apical direction on the lingual root, fading out at the middle third of the root.

The lingual cusps are the only ones to be seen from the lingual aspect.

The mesiolingual cusp is much the larger, and before occlusal wear it is always the longest cusp the tooth possesses.

Its mesiodistal width is about three fifths of the mesiodistal crown diameter, the Distolingual cusp making up the remaining two fifths.

The angles formed by the mesial outline of the crown and the mesial slope of the mesiolingual cusp is almost 90 degrees. An obtuse angle describes the junction of the mesial and distal slopes of this cusp.

The Distolingual cusp is so spheroidal and smooth that it is difficult to describe any angulation on the mesial and distal slopes.

The lingual developmental groove starts approximately in the center of the lingual surface mesiodistally, curves sharply to the distal as it crosses between the cusps, and continues on to the occlusal surfaces.

The fifth cusp appears attached to the mesiolingual surface of the mesiolingual cusp.

It is outlined occlusally by an irregular developmental groove, which may be described as starting in a depression of the mesiolingual line angle of the crown, extending occlusally toward the point of the mesiolingual cusp, then making an obtuse angle turn toward the terminus of the lingual groove and fading out near the lingual groove terminus

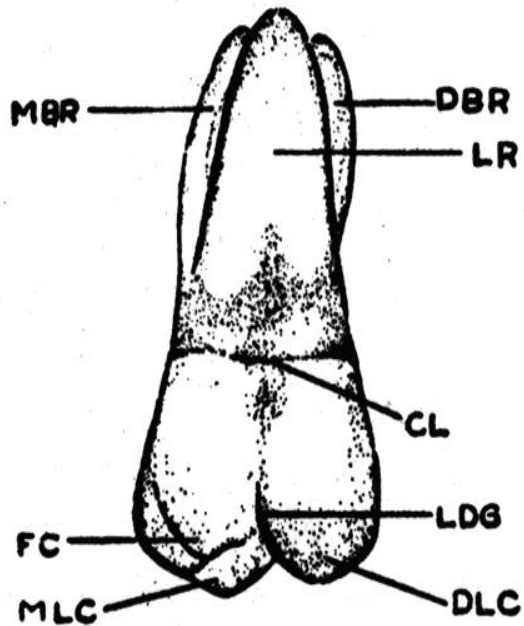


Figure 11-5. Maxillary right first molar, lingual aspect. *MBR*, Mesiobuccal root; *DBR*, distobuccal root; *CL*, cervical line; *FC*, fifth cusp; *MLC*, mesiolingual cusp; *LDG*, lingual developmental groove; *DLC*, distolingual cusp; *LR*, lingual root.

If the fifth cusp is well developed, its cusp angle will be sharper and less obtuse than that of the mesiolingual cusp.

The cusp ridge of the fifth cusp is approximately 2 mm cervical to the cusp ridge of the mesiolingual cusp.

All three of the roots are visible from the lingual aspect, the large lingual root making up most of the foreground.

The lingual portion of the root trunk is continuous with the entire cervical portion of the crown lingually. The lingual root is conical, terminating in a bluntly rounded apex.

All of the mesial outline of the Mesio Buccal root may be seen from this angle and part of its apex.

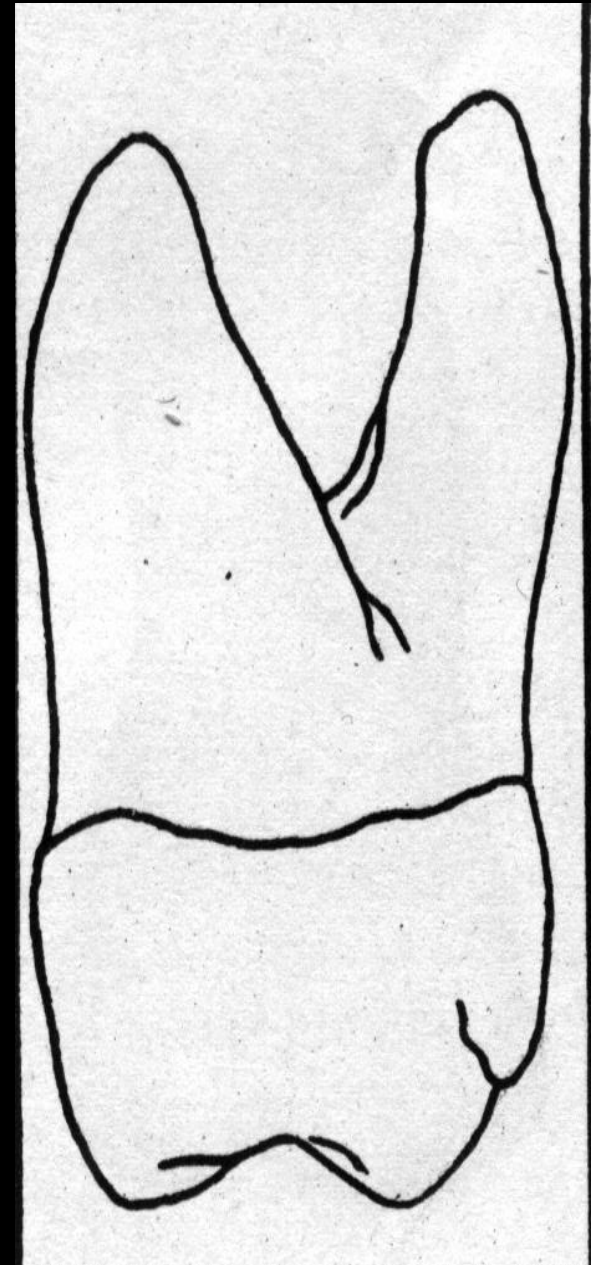
The distal outline of the distobuccal root is seen above its middle third, including all of its apical outline.

MESIAL ASPECT:

From this aspect, the increased buccolingual dimensions may be observed as well as the cervical curvatures of the crown outlines at the cervical third buccally and lingually, and the difference in dimensions between the crown at its greatest measurement and the distance between the cusp tips in a buccolingual direction.

Starting at the cervical line buccally, the outline of the crown makes a short arc buccally to its crest of curvature within the cervical third of the crown.

The extent of this curvature is about 0.5 mm.



The line of the buccal surface then describes a shallow concavity immediately occlusal to the crest of curvature.

The outline then becomes slightly convex as it progresses downward and inward to circumscribed the Mesiobuccal cusp, ending at the tip of the cusp well within projected outlines of the root base.

If the tooth is posed so that the line of vision is at right angles to the mesial contact area, the only cusps in sight are the Mesiobuccal, the mesiolingual, and the fifth cusps.

The distobuccal root is hidden by the Mesiobuccal root.

The lingual outline of the crown curves outward and lingually approximately to the same extent as on the buccal side.

The level of the crest of curvature is neat the middle third of the crown rather than a point within the cervical third, as it is buccally.

If the fifth cusp is well developed, the lingual outline dips inward to illustrate it.

If it is undeveloped, the lingual outline continues from the crest of curvature as a smoothly curved arc to the tip of the mesiolingual cusp.

The point of the cusp is more clearly centered within projected outlines of the root base than the tip of the Mesiobuccal cusp. The mesiolingual cusp is on a line with the long axis of the lingual root.

The mesial marginal ridge, which is confluent with the Mesiobuccal and mesiolingual cusp ridges, is irregular, the outline curving cervically about one fifth the crown length and centering its curvature below the center of the crown buccolingually.

The cervical line of the crown is irregular, curving occlusally, but as a rule not more than 1mm at any one point.

The mesial contact area is above the marginal ridge but closer to it than to the cervical line, approximately at junction of the middle and occlusal thirds of the crown.

It is somewhat buccal to the center of the crown buccolingually.

The Mesio Buccal root is broad and flattened on its mesial surface.

The width of this root near the crown from the buccal surface to the point of bifurcation on the root trunk is approximately two thirds of the crown measurement buccolingually at the cervical line.

The buccal outline of the root extends upward and outward from the crown, ending at the blunt apex.



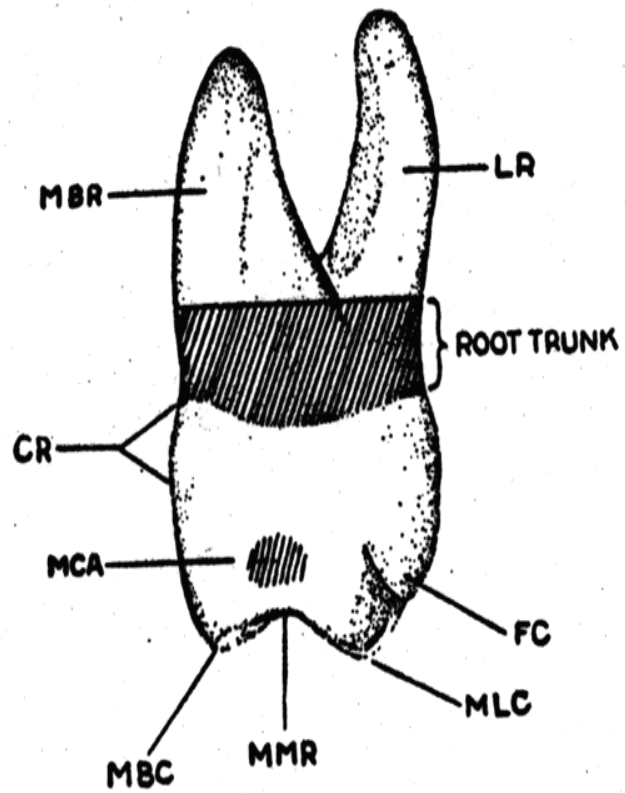


Figure 11-8. Maxillary right first molar, mesial aspect. *LR*, Lingual root; *FC*, fifth cusp; *MLC*, mesiolingual cusp; *MMR*, mesial marginal ridge; *MBC*, mesiobuccal ridge; *MCA*, mesial contact area; *CR*, cervical ridge; *MBR*, mesiobuccal root.



The level of the bifurcation is a little closer to the cervical line than is found between the roots buccally.

The lingual root is longer than the mesial root but is narrower from this aspect.

It is banana-shaped, extending lingually with its convex outline to the lingual and its concave outline to the buccal.

At its middle and apical thirds, it is outside of the confines of the greatest crown projection.

Although its apex is rounded, the root appears more pointed toward the end than the Mesio Buccal root.


DISTAL ASPECT:

The gross outline of this aspect is similar to that of the mesial aspect.

Certain variation must be noted when the tooth is viewed from the distal aspect.

Because of the tendency of the crown to taper distally on the buccal surface, most of the buccal surface of the crown may be seen in perspective from the distal aspect.

This is because the buccolingual measurement of the crown mesially is greater than the same measurement distally. All of the decrease in measurement distally is due to the slant of the buccal side of the crown.



The distal marginal ridge dips sharply in a cervical directions, exposing triangular ridges on the distal portion of the occlusal surface of the crown.

The cervical lie is almost straight across from buccal to lingual. Occasionally it curves apically 0.5 mm or so.

The distal surface of the crown is generally convex, with a smoothly rounded surface except for a small area near the distobuccal root at the cervical third.

This concavity continues on to the distal surface of the distobuccal root, from the cervical line to the area of the root that is on a level with the bifurcation separating the distobuccal and lingual roots.

The distobuccal roots is narrower at its base than either of the others.

An outline of this root, when we view the tooth from the distal aspect, starts buccally at a point immediately above the distobuccal cusp, follows a concave path inward for a short distance, then outward in a buccal direction, completing a graceful convex arc from the concavity to the rounded apex.

This line lies entirely within the confines of the outline of the Mesio Buccal root.

The lingual outline of the root from the apex to the bifurcation is slightly concave.

If anything, the surface at this point on the root trunk has a tendency toward convexity.

The bifurcation here is more apical than either of the other two areas on this tooth. The area from cervical line to bifurcation is 5mm or more in extent.

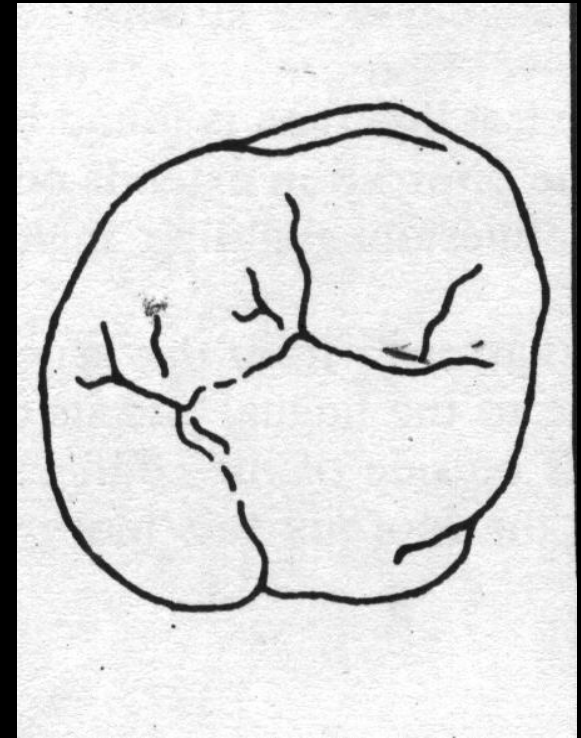
OCCLUSAL ASPECT:

The maxillary first molar is **rhomboid** from the occlusal aspect.

The crown of the first molar is wider mesially than distally and wider lingually than buccally.

The four major cusps are well developed, with a small, minor cusp or the fifth cusp which appears on the lingual surface of the mesiolingual cusp near the Mesio lingual line angle of the crown.

The fifth cusp may be indistinct or absent, however there will be traces of developmental lines in enamel at this site.



The mesiolingual cusp is the largest, it is followed by in point of size, Mesio Buccal, Distolingual, distobuccal and the fifth cusp

ML>MB>DL>DM>fifth cusp

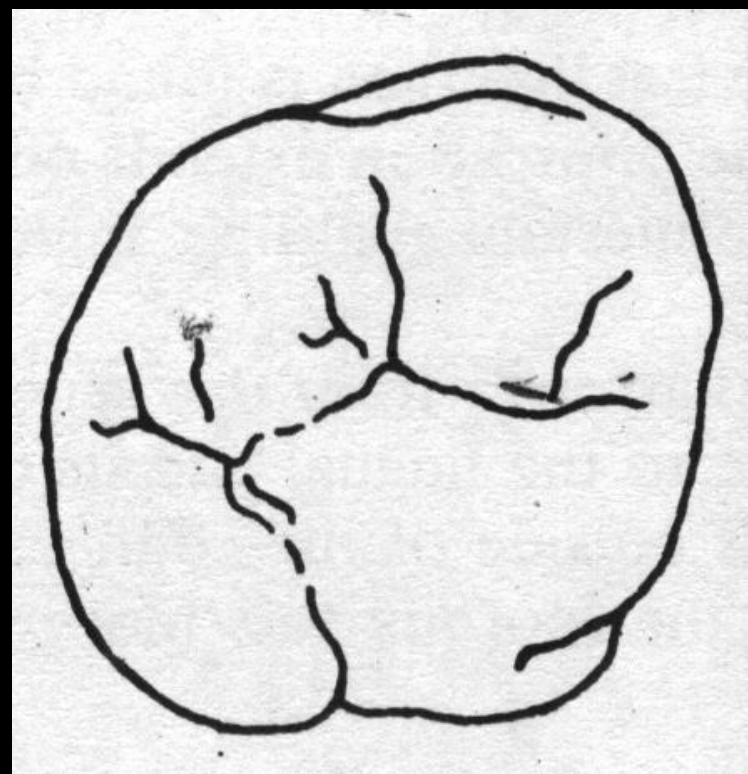
When reduced to a geometric schematic figure, the occlusal aspects of the first molar locates the various angles of a rhombus as follows

Acute angles

Mesio Buccal and Distolingual

Obtuse angles

Mesiolingual and Disto buccal



Developmentally:


The maxillary first molar has **three primary cusps**

Mesilingual (most primitive)

Mesiobuccal and distobuccal

Secondary cusps

Distolingual and cusp of carrabelli/fifth cusp



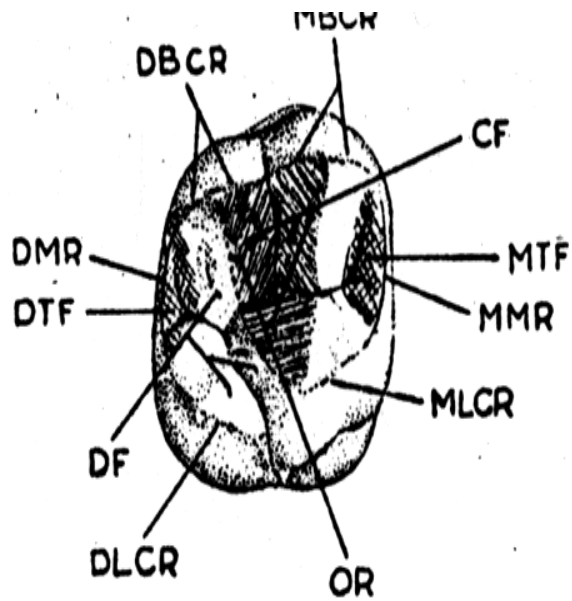


Figure 11-1. Maxillary right first molar, occlusal aspect. *MBCR*, Mesiobuccal cusp ridge; *CF*, central fossa (shaded area); *MTF*, mesial triangular fossa (shaded area); *MMR*, mesial marginal ridge; *MLCR*, mesiolingual cusp ridge; *DF*, distal fossa; *DTF*, distal triangular fossa (shaded area); *DMR*, distal marginal ridge; *DBCRC*, distobuccal cusp ridge; *DLCRC*, distolingual cusp ridge; *OR*, oblique ridge.


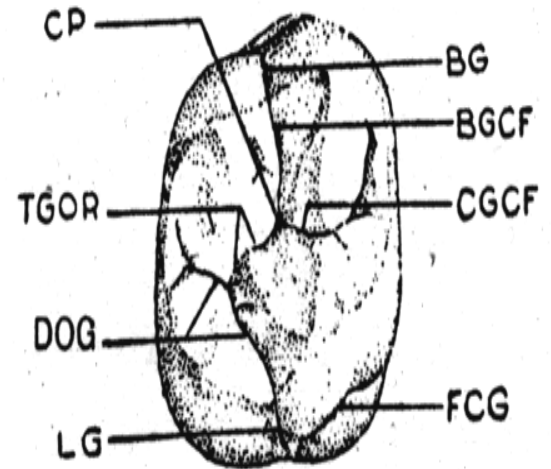


Figure 11-2. Maxillary right first molar, occlusal aspect, developmental grooves. *BG*, Buccal groove; *BGCF*, buccal groove of central fossa; *CGCF*, central groove of central fossa; *FCG*, fifth cusp groove; *LG*, lingual groove; *DOG*, distal oblique groove; *TGOR*, transverse groove of oblique ridge; *CP*, central pit.



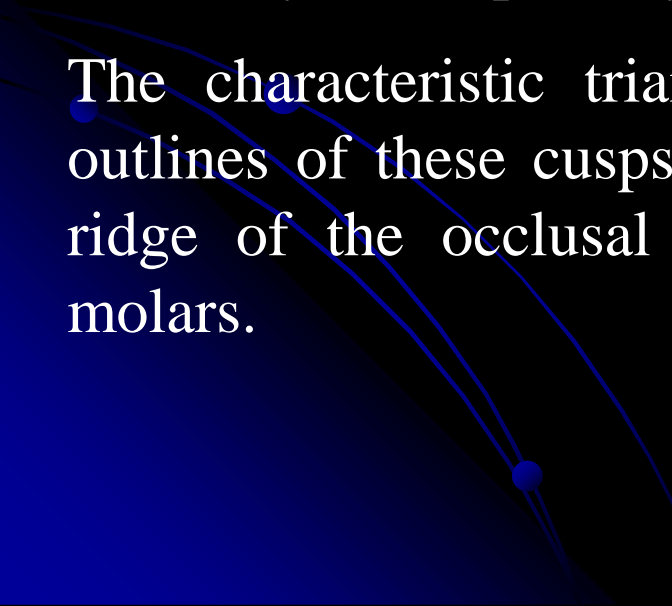
The *maxillary molar primary cusp triangle* supposition follows the cope Osborne hypothesis of tooth origins.

There was a tritubercular stage in human development which forms the basis of the triangular arrangement of cusps.

The Distolingual cusp becomes progressively smaller on second and third molars, often disappearing as a major cusp.

The triangular arrangement of the three important cusps is called the maxillary molar primary cusp triangle .

The characteristic triangular figure made by tracing the cuspal outlines of these cusps, the mesial marginal ridge and the oblique ridge of the occlusal surface, is representative of all maxillary molars.



The occlusal surface can be described as follows

There are two major fossae and two minor fossae.

The major fossae

Central fossa-triangular (roughly) and mesial of oblique ridge.

Distal fossa- linear and distal to oblique ridge

The minor fossae

Mesial triangular fossa- distal to the mesial marginal ridge

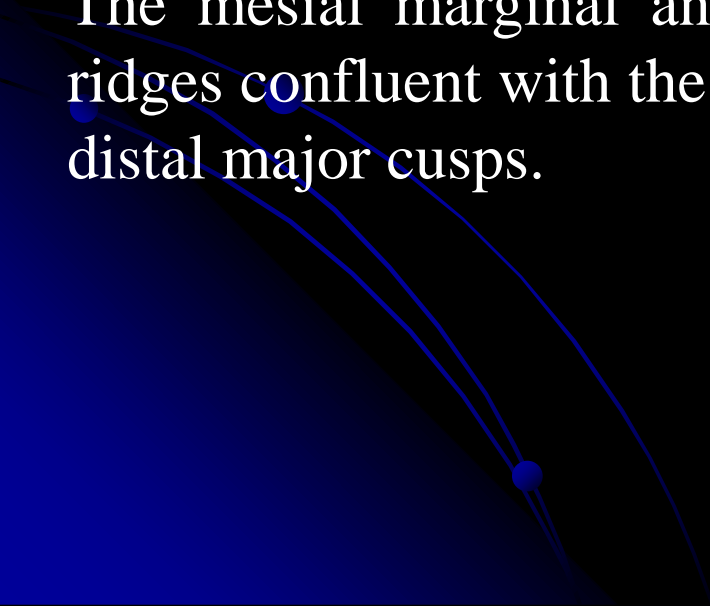
The distal triangular fossa- mesial to distal marginal ridge

The oblique ridge is a ridge which crosses the occlusal surface obliquely.

It is formed by the union of the triangular ridge of the distobuccal cusp and the distal ridge of the mesiolingual cusp.

This ridge is reduced to the level of the marginal ridges in the centre of the occlusal surface

The mesial marginal and the distal marginal ridges are irregular ridges confluent with the mesial and distal cusp ridges of mesial and distal major cusps.



Central fossa:

It is a concave area bounded by the distal slope of the Mesio Buccal cusp, the mesial slope of distobuccal cusp, the crest of the oblique ridge and the crest of the two triangular ridges of the Mesio Buccal and mesiolingual cusps.

It has connecting sulci, and contains supplemental grooves and central developmental pit.

Starting from this pit, the buccal developmental groove radiates buccally and continues onto the buccal surface of the crown between the buccal cusps.

The central developmental groove starts from the central pit progresses in a mesial direction at an obtuse angle to the buccal sulcate groove, it generally terminates at the apex of the mesial triangular fossa.

Here it is joined by short supplemental grooves that radiate from the terminus into the triangular fossa

Another short developmental groove radiates from central pit , it sometimes however crosses the oblique ridge hence joining the central and distal fossae then it is called a transverse groove of the oblique ridge

The distal fossa is linear and located distal to the oblique ridge. An irregular groove traverses its deepest portion this is called distal oblique groove.

This groove connects with the lingual developmental groove at the junction of cusp ridges of mesiolingual and Distolingual cusps.

If the fifth cusp is distinct, a developmental groove outlines it this is called fifth cusp groove.

PULP CAVITY

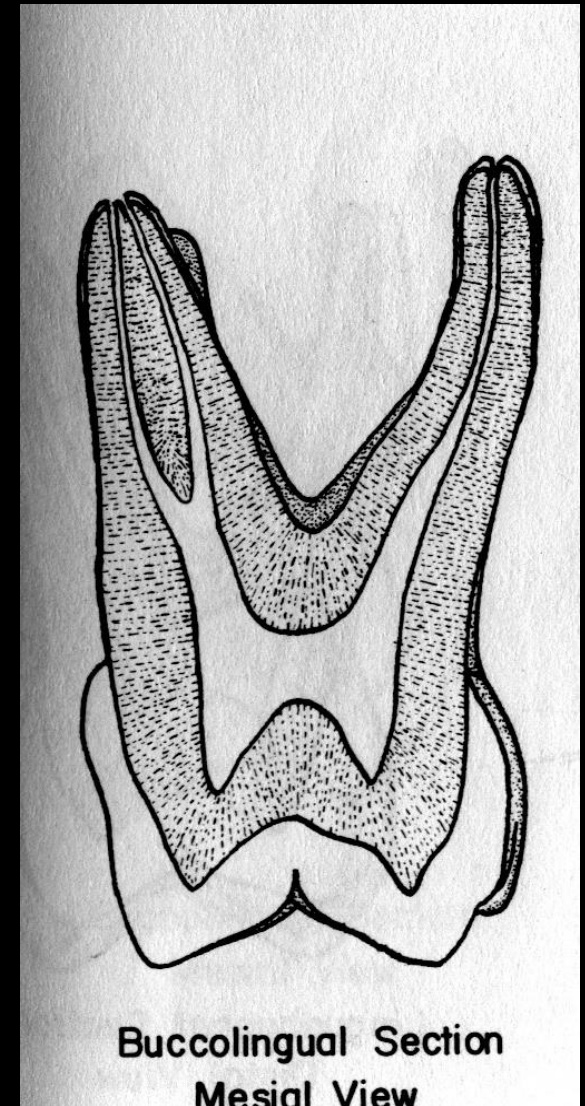
BUCCOLINGUAL SECTION:

The buccolingual section of the maxillary first molar shows the pulp cavities of the Mesio Buccal and palatal root.

These roots were chosen to demonstrate the pulp cavity anatomy because of the complexity of the Mesio Buccal root.

The distobuccal root is straighter and smaller and presents fewer variations in shape.

The entire removal of the pulp is an impossibility in many maxillary first molar teeth because of the complexity of the root canal system.



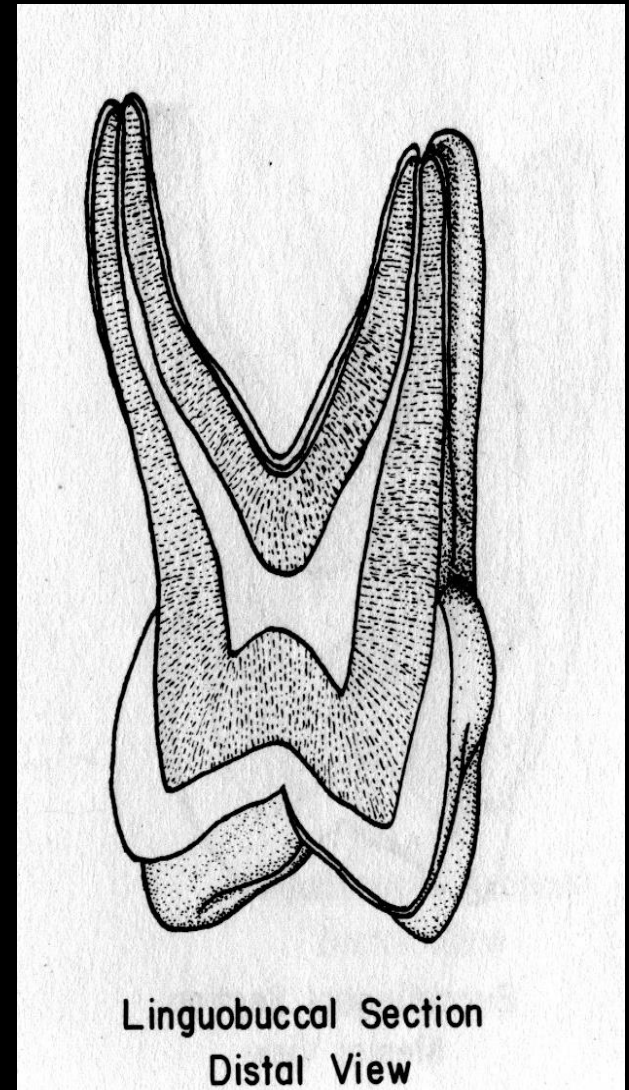
RIGHT SIDE

The maxillary first molar usually has three roots and three canals.

The palatal root usually has the largest dimensions, followed by the distobuccal and Mesio Buccal roots, respectively.

The Mesio Buccal root is often very wide buccolingually and often possesses an accessory canal, which usually is the smallest of all the canals in this tooth.

The pulp horns are usually prominent in this tooth. The pulp chamber is somewhat rectangular in shape when viewed from the mesial aspect of the tooth.



The palatal root canal usually has the largest canal. The Mesiobuccal canal is often very small, but some Mesiobuccal canals may be very wide within a very wide root.

The root canals of the wide Mesiobuccal roots are widest at the midroot level and taper to a very fine diameter at the apical foramen.

The palatal root canal and the Mesiobuccal root canal of most teeth taper gently to the apical region where they terminate to exit at the apex.

The apical foramen of the palatal canal may appear to exit at the apex, slightly lingually or buccally to the root tip.

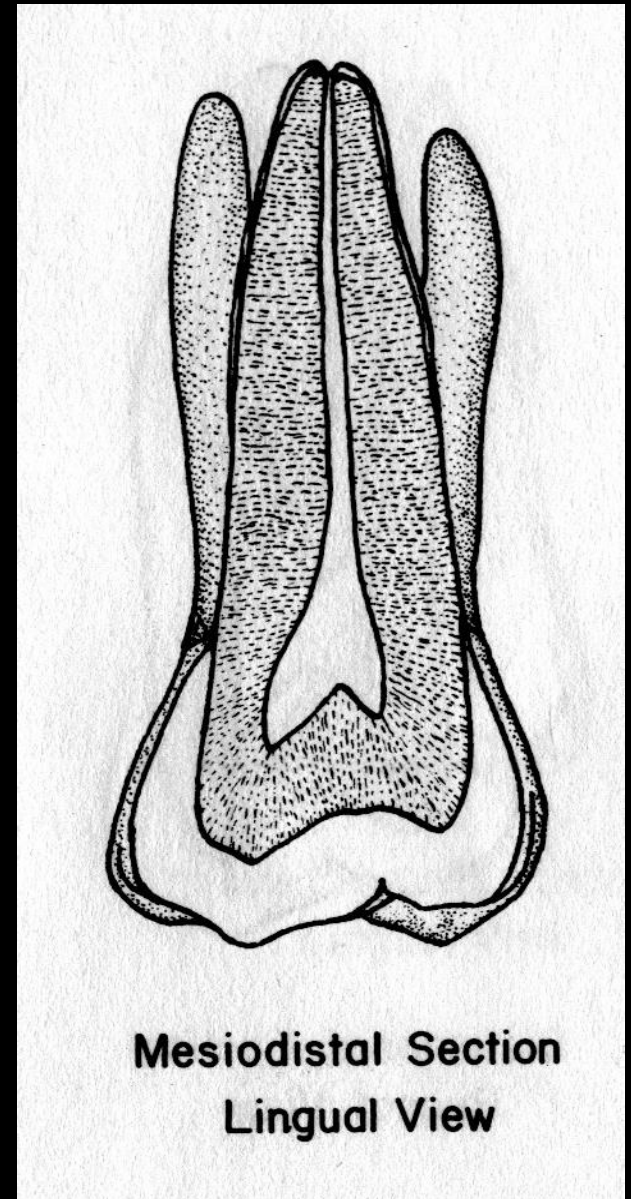
The apical foramen of the Mesiobuccal canal may appear to exit on the tip of the root on the buccal or on the lingual aspect of the root.

MESIODISTAL SECTION:

The mesiodistal section of the maxillary first molar includes the distobuccal root, which was not visible on the buccolingual section.

The Mesio Buccal root has a great tendency to possess a more curved root and canal than the distobuccal root. Some of the buccal canals are relatively straight.

The pulp horns are very distinct from this view, with the Mesio Buccal pulp horn usually appearing a little larger than the distobuccal pulp horn.



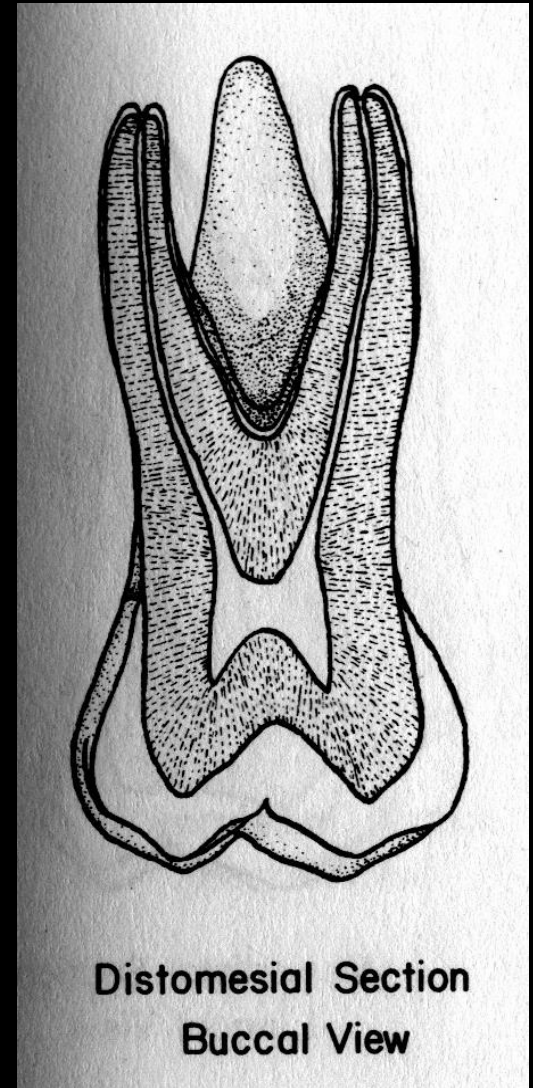
In some teeth, the pulp horns are of equal size. The pulp chamber is somewhat square when viewed from the buccal aspect.

The demarcation of the root canal is much more distinct in the mesiodistal section.

The root canals appear much smaller when viewed from the buccal or lingual aspect.

The canals taper slightly as they approach the apical foramen.

The apical foramen often appears to be located at the tip of the root, but the apical foramen may appear to be located on the mesial or distal aspect of the root.



CERVICAL CROSS SECTION:

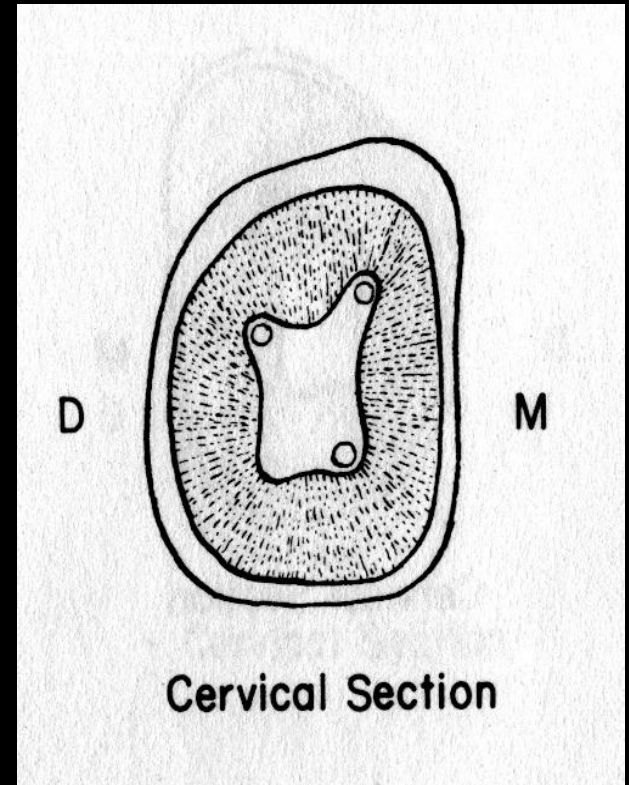
The cervical outline form of the maxillary first molar is rhomboidal in shape with rounded corners.

The Mesio Buccal angle has an acute angle, the distobuccal angle is obtuse, and the lingual angles are essentially right angles.

The orifices of the root canals have the following relation of the floor of the pulp chamber:

The palatal canal is centered lingually;

The distobuccal canal is near the obtuse angle of the pulp chamber;



The Mesiobuccal root canal is buccal and mesial to the distobuccal canal, in what seems to be the extreme corner, positioned within the acute angle of the pulp chamber.

If an accessory Mesiobuccal canal is present, it will be located lingual to the Mesiobuccal canal or Disto lingually

The canals of this tooth form a triangular pattern; a line drawn between the Mesiobuccal canal and the palatal canal makes the base of the triangle, and the distobuccal canal makes the third point of the triangle.

If a Mesiobuccal accessory canal is present, it will be between the Mesiobuccal and palatal canal just off the imaginary line between the two canals.

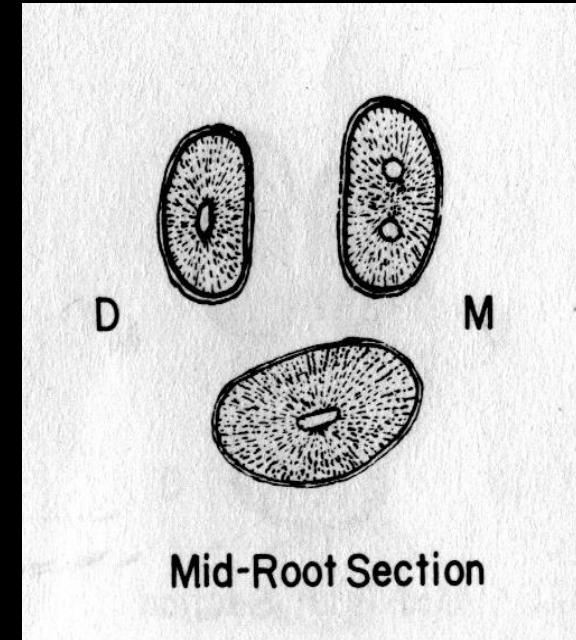
MIDROOT CROSS SECTION:

The midroot sections were added to the molar descriptions because some molars possess more than one canal within the root.

The palatal root is usually the largest root having a round outline form. The distobuccal canal is oval to round in shape but much smaller than the palatal root.


The Mesio Buccal root is an elongated oval to kidney-shaped root with the indentation located toward the furcation.

The root canals of the palatal and distobuccal root are oval to round, whereas the Mesio Buccal canal are elongated, elliptical or round.




The pulp canals may be extremely difficult to locate and instrument if secondary or irritation dentin is abundant.

A thorough knowledge of the anatomy of the pulp chambers and canals is necessary if endodontic procedures are to be accomplished.



THE PERMANENT MAXILLARY SECOND MOLAR



The maxillary second molar supplements the first molar in function. In describing this tooth, direct comparisons will be made with the first molar both in form and development.

The roots of this tooth are as long as, those of the first molar. The distobuccal cusp is not as large or as well developed, and the Distolingual cusp is smaller. No fifth cusp is evident.

The crown of the maxillary second molar is 0.5 mm or so shorter cervico-occlusally than that of the first molar, but the measurement of the crown buccolingually is about the same.

Two types of maxillary second molars are found when we are viewing the occlusal aspect:

1) The type that is seen most has an occlusal form which resembles the first molar, although the rhomboidal outline is more extreme. This is accentuated by the lesser measurement lingually.

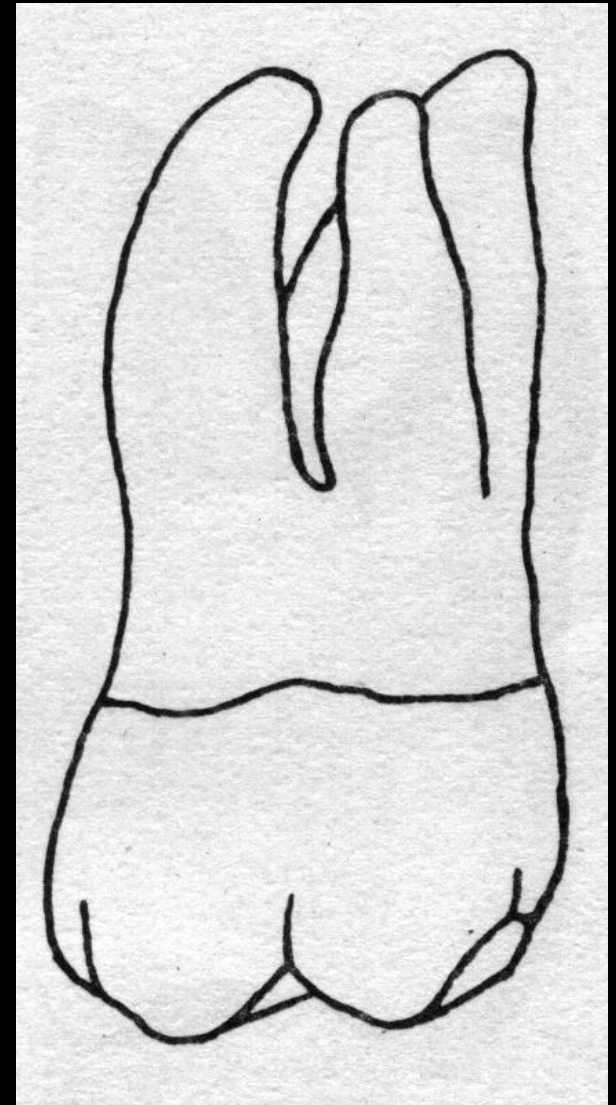
2) This type bears more resemblance to a typical third molar form. The Distolingual cusp is poorly developed and makes the development of the other three cusps predominate.

This results in a heart-shaped form from the occlusal aspect that is more typical of the maxillary third molar.

BUCCAL ASPECT:

The crown is a little shorter cervico-occlusally and narrower mesiodistally than the maxillary first molar.

The distobuccal cusp is smaller and allows part of the distal marginal ridge and part of the Distolingual cusp to be seen.




LEFT SIDE

The buccal roots are about the same length.

These roots are more nearly parallel and are inclined distally more than those of the maxillary first molar so that the end of the distobuccal root is slightly distal to the distal extremity of the crown.

The apex of the Mesiobuccal root is on a line with the buccal groove of the crown instead of the tip of the Mesiobuccal cusp, as was found on the first molar.

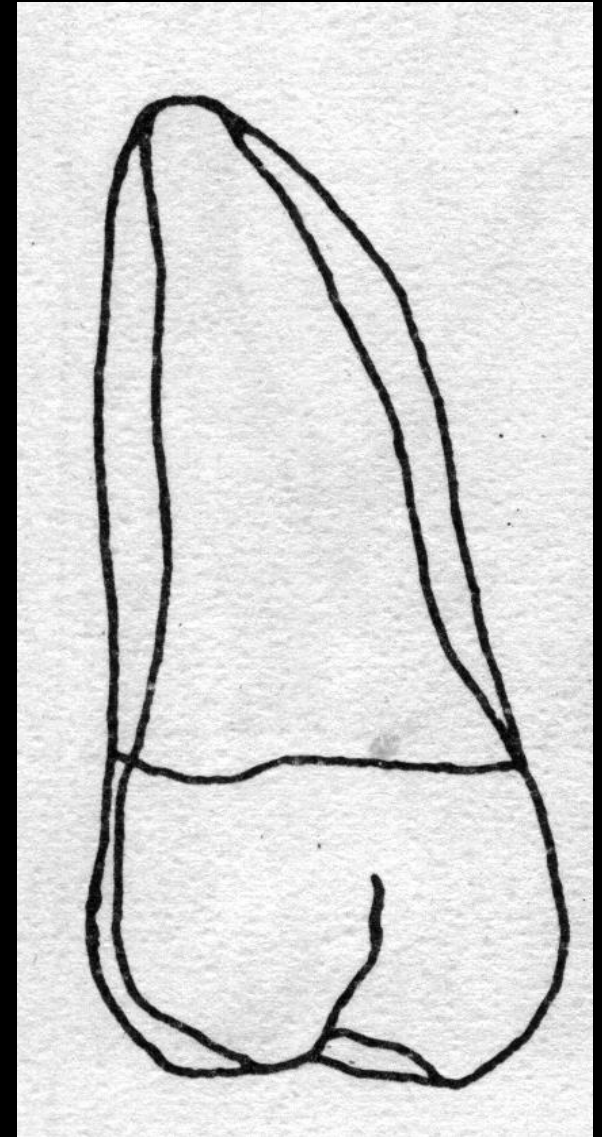


LINGUAL ASPECT:

Differences between the second and first molars to be noted here in addition to those mentioned before are these:

- 1) The Distolingual cusp of the crown is smaller.
- 2) The distobuccal cusp may be seen through the Sulcus between the mesiolingual and Distolingual cusp.
- 3) No fifth cusp is evident.


The apex of the lingual root is in line with the Distolingual cusp tip instead of the lingual groove as was found on the first molar.



MESIAL ASPECT:

The buccolingual dimension is about the same as that of the first molar, but the crown length is less.

The roots do not spread as far buccolingually, being within the confines of the buccolingual crown outline.

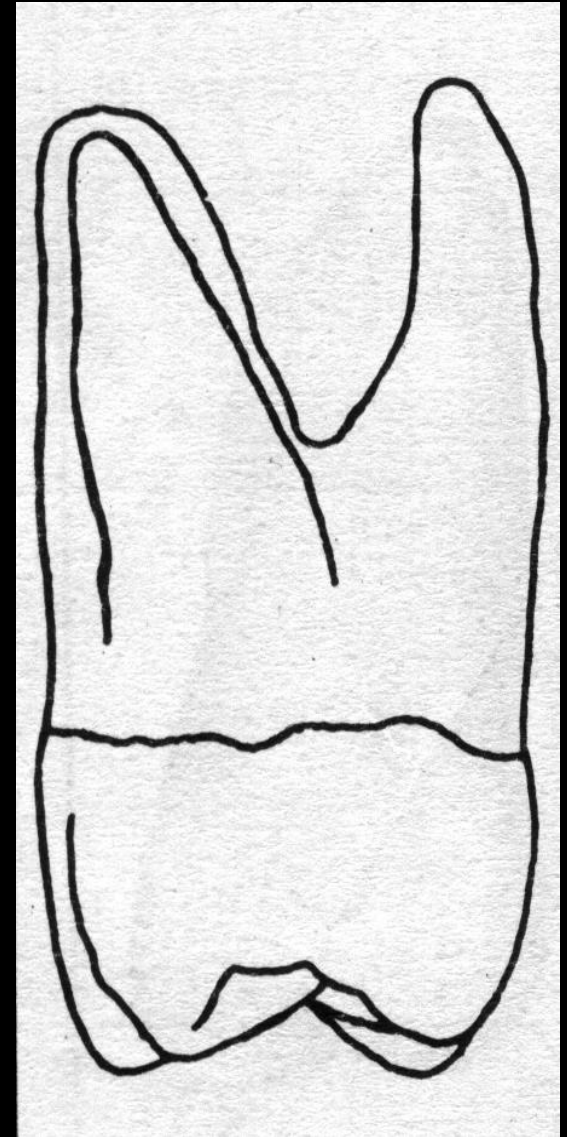


DISTAL ASPECT:

Because the distobuccal cusp is smaller than in the maxillary first molar, more of the Mesio Buccal cusp may be seen from this angle.

The mesiolingual cusp cannot be seen.

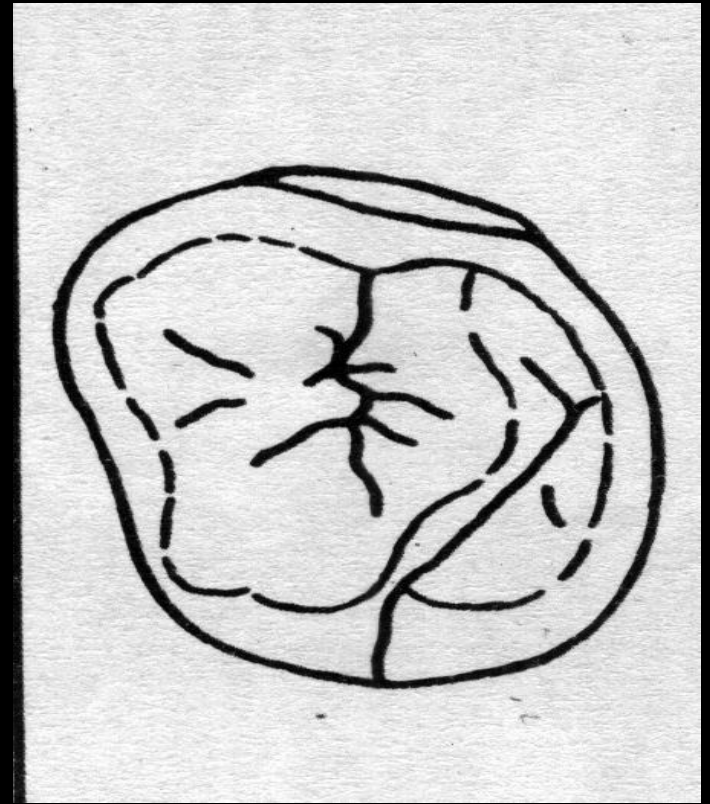
The apex of the lingual root is in line with the Distolingual cusp.



OCCLUSAL ASPECT:

The rhomboidal type of second maxillary molar is most frequent, although in comparison with the first molar the acute angles of the rhomboid are less and the obtuse angles greater.

The buccolingual diameter of the crown is about equal, but the mesiodistal diameter is approximately 1 mm less.



The Mesio Buccal and mesiolingual cusps are just as large and well developed as in the first molar, but distobuccal Distolingual cusps are smaller and less well developed.

Usually, a calibration made of the crown at the greatest diameter buccally and lingually of the distal portion is considerably less than one made at the greatest diameter buccally and lingually of the mesial portion, showing more convergence distally than the maxillary first molar.

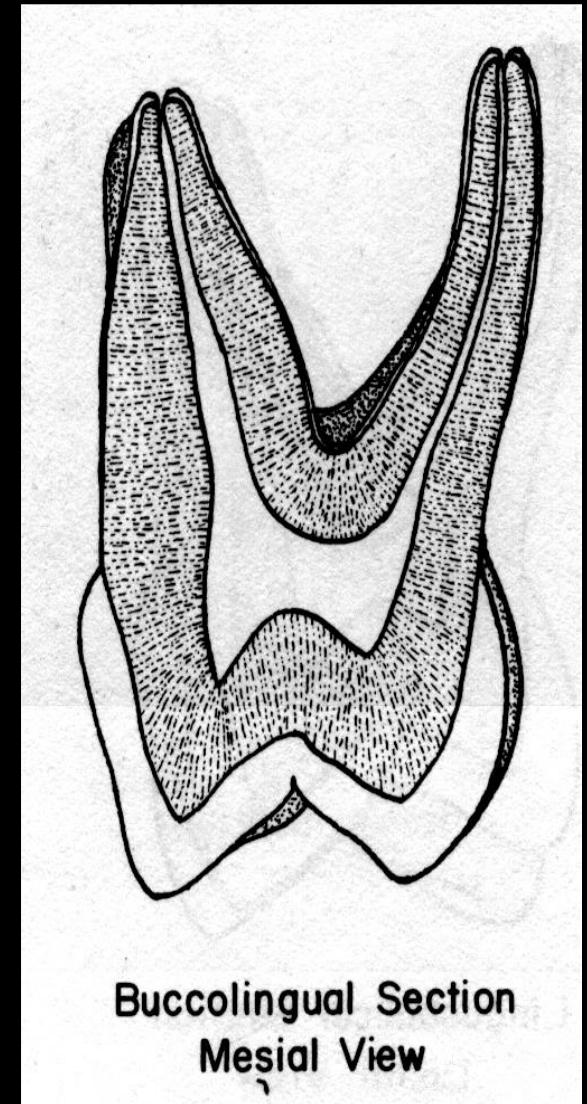
It is not uncommon to find more supplemental grooves as well as accidental grooves and pits on the occlusal surface of a maxillary second molar than are usually found on a maxillary first molar.

BUCCOLINGUAL SECTION:

The buccal roots of the maxillary second molar are straighter and close together than those of the maxillary first molar.

The tendency for root fusion is greater in the second maxillary molar than in the first maxillary molar, but the palatal root is usually separate.

Most maxillary second molars possess three roots and three canals. The Mesio Buccal root of the maxillary second molar is not as complex as that formed in the maxillary first molar.



Buccolingual Section
Mesial View

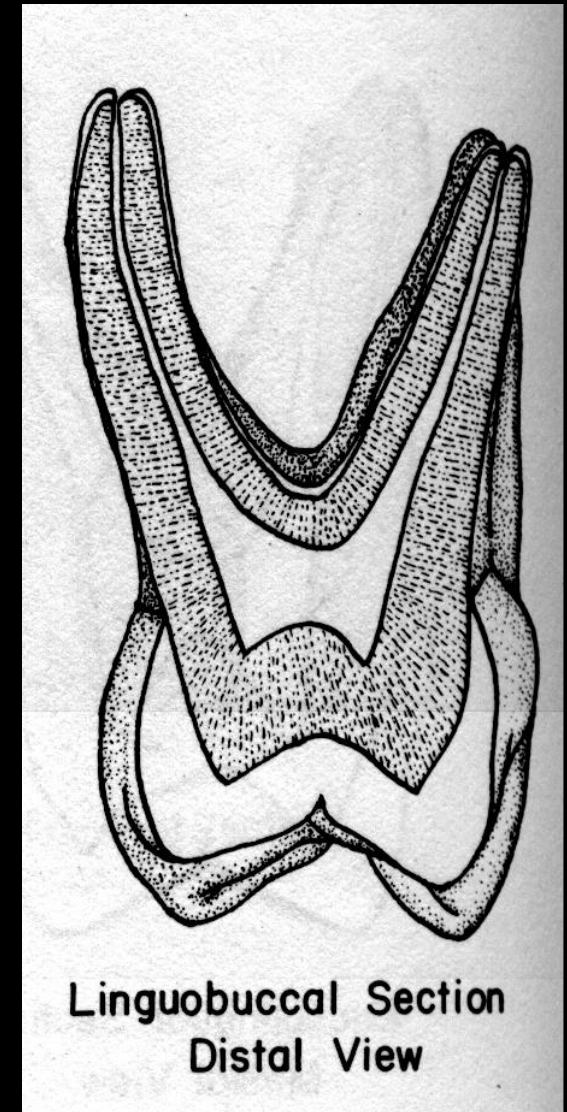
RIGHT SIDE

The tendency for a very wide Mesio Buccal canal is not present in the maxillary second molar.

Although the presence of two canals in the Mesio Buccal root of the maxillary second molar is not common, it does occur.


The pulp horn may be well developed or virtually absent. The pulp chamber appears somewhat rectangular in shape.

The pulp canals gradually taper toward the apex until reaching the apical constriction, which occurs just before the apical foramen.



The Mesiobuccal root canal of the maxillary second molar does not have the tendency to be extremely large, as is demonstrated in the Mesiobuccal canal of the maxillary first molar.

The apical foramen of the palatal root often appears to exit at the tip of the root, but it may exist on the lingual or buccal aspect of the root.

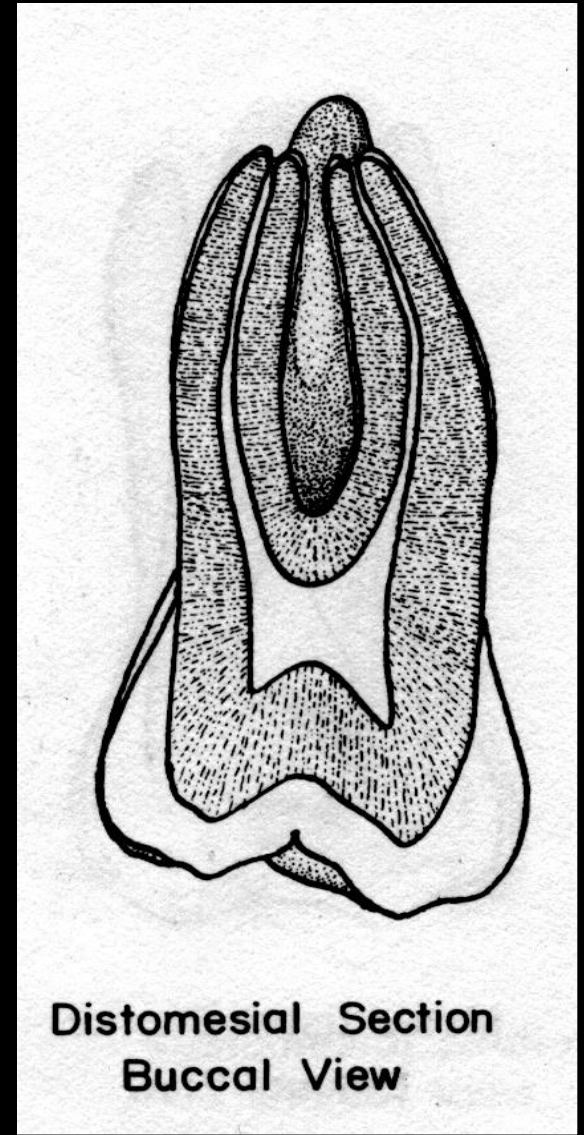


MESIODISTAL SECTION:

The mesiodistal section of the maxillary second molar is similar to that of the maxillary first molar.

The buccal roots of the second molar are not separated as far apart as they are in the maxillary first molar, and their buccal roots have a greater tendency to be fused.

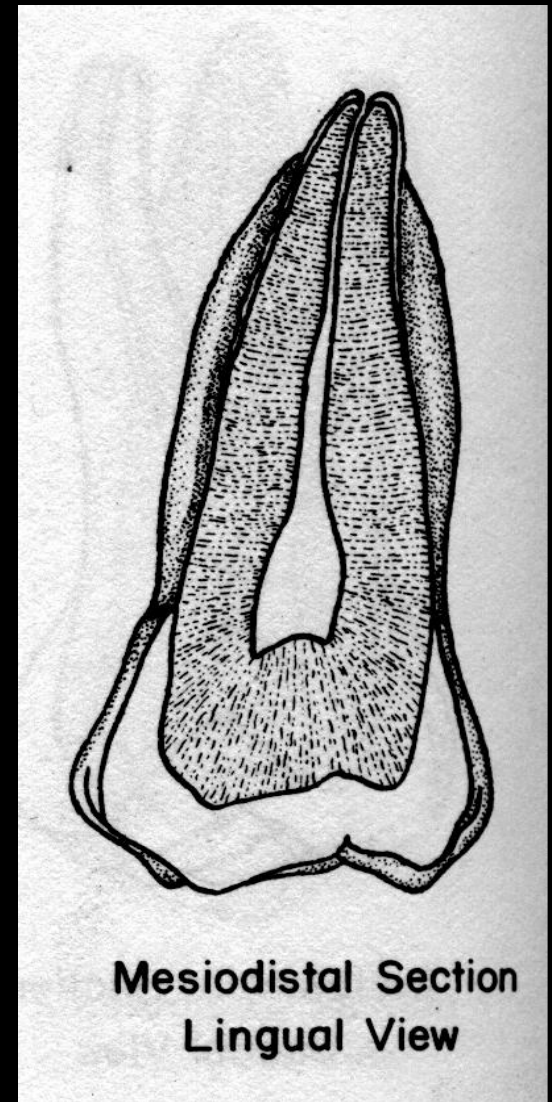
The pulp horns are usually well developed. Some teeth demonstrate an obvious blunting or absence of the pulp horns. The Mesio Buccal pulp horn is often larger than the distobuccal pulp horn.



The pulp chamber is much smaller in the mesiodistal section than in the buccolingual section. The pulp chamber is square when viewed from the buccal aspect.

The pulp canals gently taper from the pulp chamber to the apical constriction. The Mesio Buccal pulp canal has a greater tendency to be curved than the distobuccal canal.

The majority of the apical foramen appears to exit at the tip of the root.

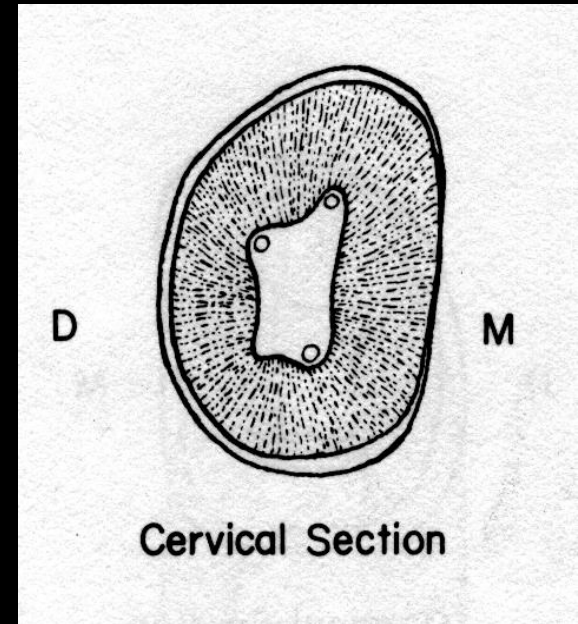


CERVICAL CROSS SECTION:

The cervical cross section of the maxillary second molar demonstrates angulations of the outline form that are more extreme than those found in the maxillary first molar.

The Mesio Buccal angle is more acute and the distobuccal angle is more obtuse than that found in the maxillary first molar and the outline form of the pulp chamber reflects these differences.

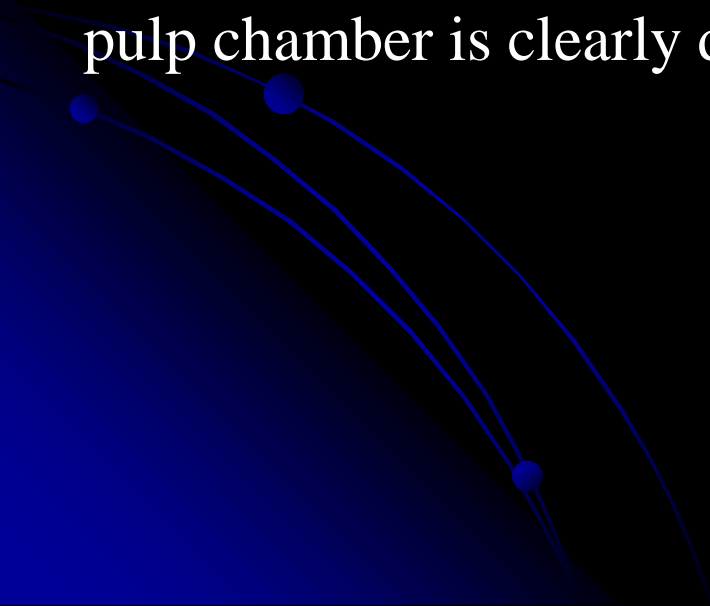
The Mesio Buccal canal orifice is located farther to the buccal and mesial aspect of the pulp chamber.



The distobuccal canal more nearly approaches the midpoint between the Mesio Buccal and palatal canal.

The palatal canal is located at the most lingual aspect of the root. Because of the tendency for the roots to be fused or at least closer together than in the maxillary first molar.

In the cervical cross section, the triangularity of the floor of the pulp chamber is clearly demonstrated.



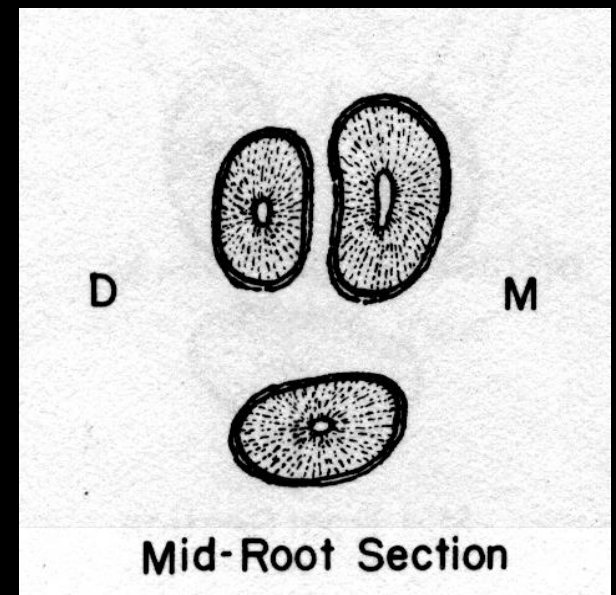
MIDROOT SECTION:

The palatal root of the maxillary second molar may be the largest of the three roots.

The Mesio Buccal root may have a larger buccolingual dimension, but it has a narrower mesiodistal dimension.

The distobuccal canal is the smallest root of the three. The distobuccal root and the palatal root have round or oval outline form.

The Mesio Buccal root is usually rectangular in shape with rounded corners.



If one canal is present, the canal follows the outline form of the root is usually narrower at the middle of the root, making the canal appear as two canals.

If two separate canals are present, they are usually round.

Anatomical similarities are present between the first and second maxillary molars, but differences do exist and should be acknowledge while performing endodontic procedures.

