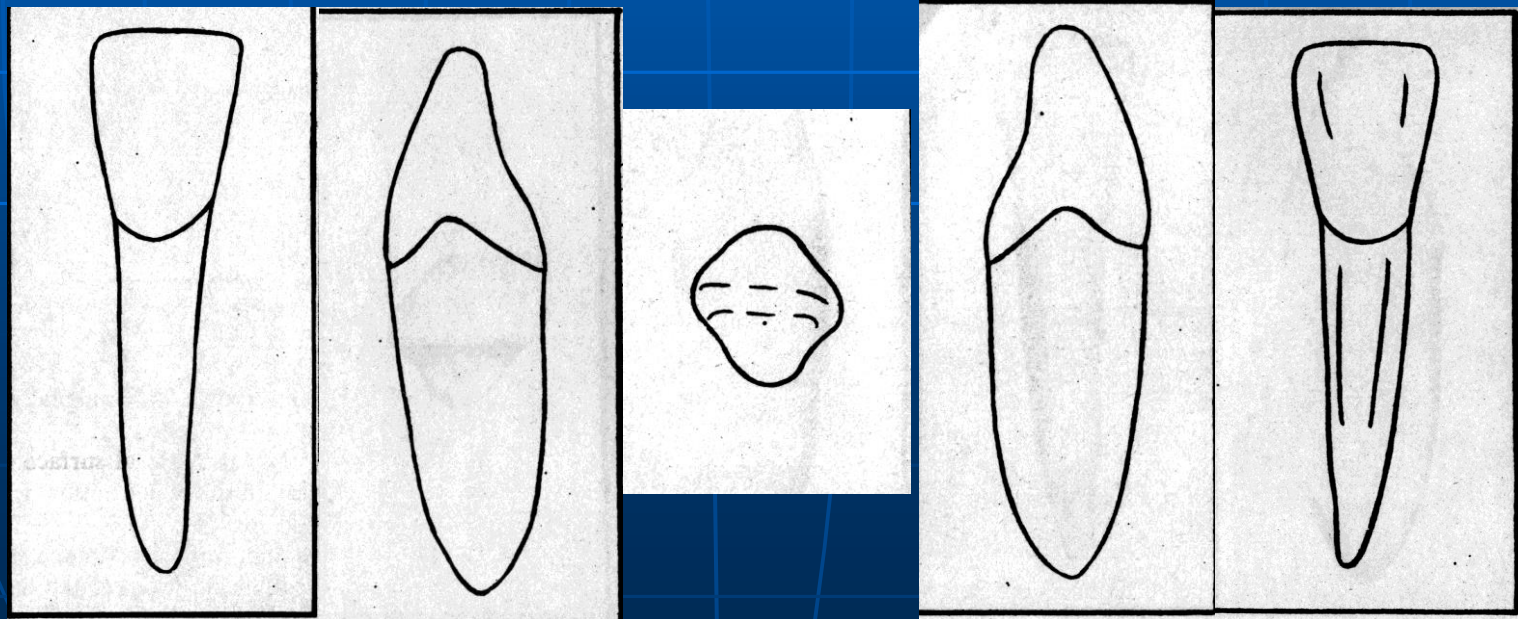


DEPARTMENT OF ORAL AND MAXILLOFACIAL PATHOLOGY

MANDIBULAR LATERAL INCISOR



INTRODUCTION

- The mandibular Lateral Incisor is the second mandibular tooth from median line, right or left. It resembles the mandibular Central Incisor closely. The two incisors operate in the dental arch as a team; therefore, their functional form is related.

- First evidence of calcification 3 to 4 months
- Enamel completed 4 to 5 years
- Eruption 7 to 8 years
- Root completed 10 years


MEASUREMENT TABLE

In mm.

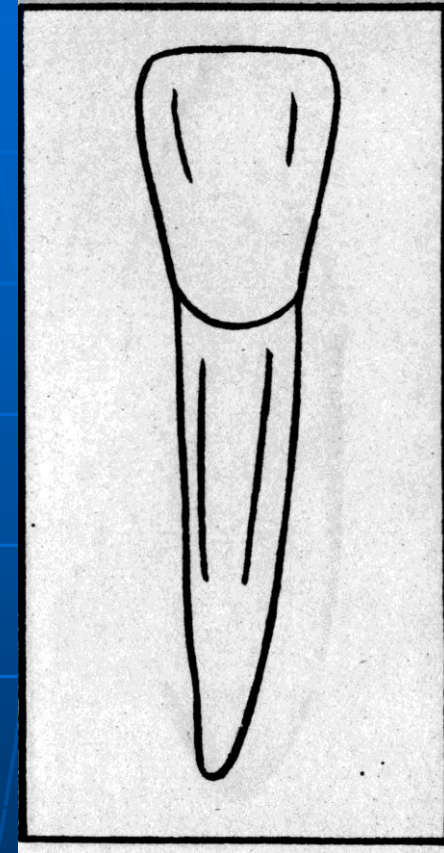
■ Cervico incisal length of crown	10.5
■ Cervico incisal length Of root	13.0
■ Mesiodistal diameter of crown	08.5
■ Mesiodistal diameter of crown At cervix	07.0
■ Labiolingual diameter of crown	07.0
■ Labiolingual diameter of crown At cervix	06.0
■ Curvature of cervical line mesial	03.5
■ Curvature of cervical line distal	02.5

**BRIEF DESCRIPTION
OF MANDIBULAR
LATERAL INCISOR
FROM ALL ASPECTS**

LABIAL AND LINGUAL ASPECT

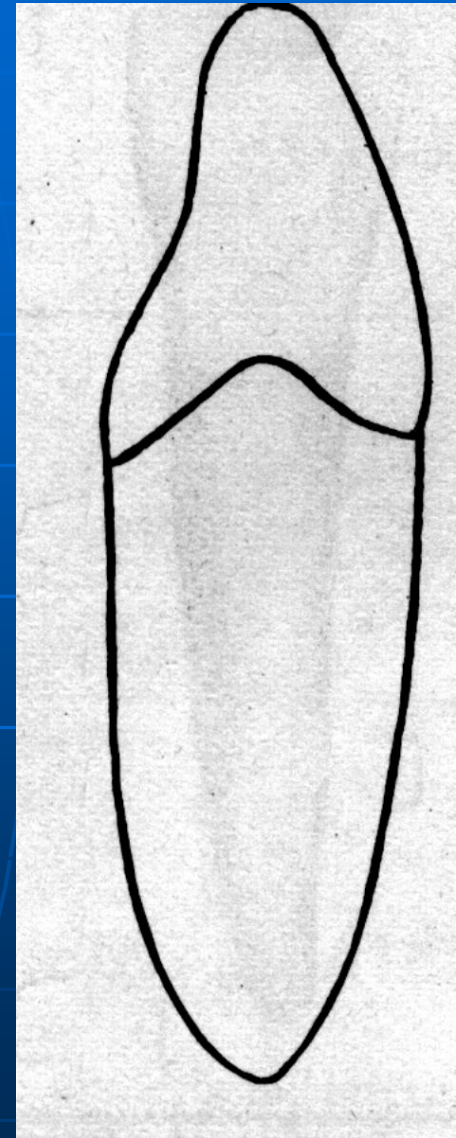
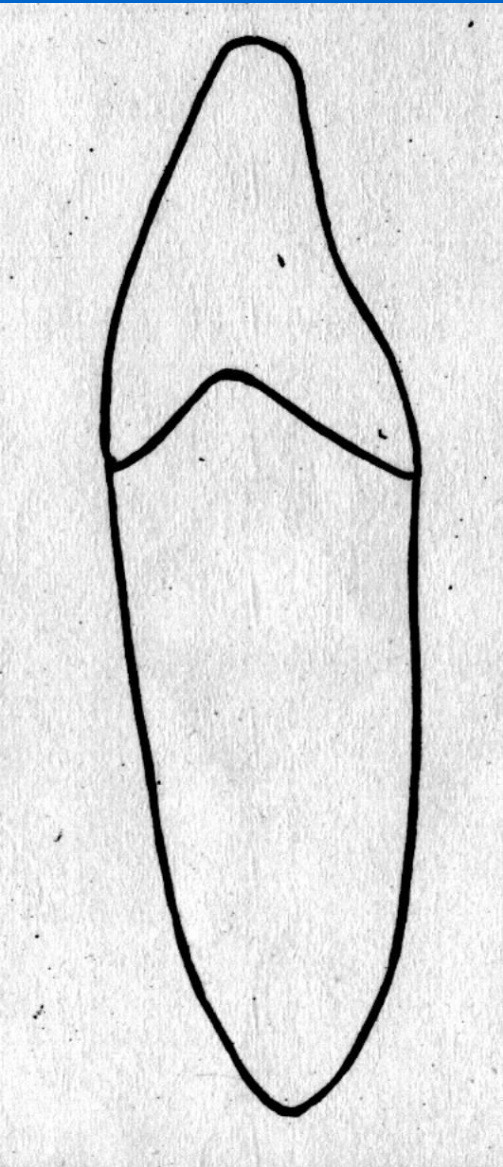


- The labial and lingual aspects show the added fraction of approximately 1 mm of crown diameter mesiodistally added to the distal half.



MESIAL AND DISTAL ASPECT

- The mesial side of the crown is often longer than the distal side causing the Incisal ridge, which is straight, to slope downward in a distal direction. The distal contact area is more towards the cervical than the mesial contact area to contact properly the mesial contact area of the mandibular canine.




- Expect for size, there is no marked difference between the mesial and distal surfaces of central and Lateral Incisors. Even the curvatures of the cervical line mesially and distally are similar in extent. There is a tendency toward a deeper concavity immediately above the cervical line on the distal surface of the mandibular Lateral Incisor.

- Although the crown of the mandibular Lateral Incisor is somewhat longer than that of the Central Incisor, the root may be considerably longer. The tooth is, therefore, a little larger in all dimensions. The root form is similar to that of the Central Incisor, including the developmental depressions mesially and distally.

INCISAL ASPECT

- The Incisal aspect of the mandibular Lateral Incisor provides a feature that can usually serve to identify this tooth. This incisal edge is not at approximate right angles to a line bisecting the crown and root Labiolingually, as was found when observing the Central Incisor.



- The edge follows the curvature of the mandibular dental arch, giving the crown of mandibular Lateral Incisor the appearance of being twisted slightly on its root

