


# NECROSIS

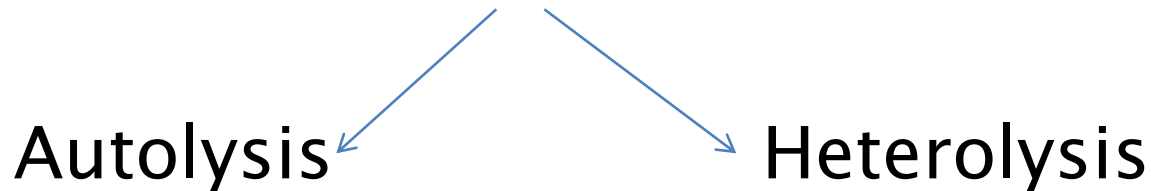
DR.HARSHAD P.PATEL  
ASST.PROFESSOR, GEN.PATHOLOGY  
G.D.C & H.

# DEFINITION

- ▶ Necrosis may be defined as the morphological changes that follow cell death in a living tissue or organ ,resulting from the progressive degradative action of enzymes on lethally injured cell.
  - ▶ It is irreversible cell injury.
  - ▶ It affect both cytoplasm and nucleus.
- 


# PATHOGENESIS

- ▶ Two processes are mainly responsible for necrosis:
  - Enzymatic digestion of the cell .



- Denaturation of structural protein.

# ETIOLOGICAL FACTORS

- ▶ Failure of circulation e.g. Ischemia
  - ▶ Physical agents  
e.g. Trauma, cold, heat, electricity, radiation  
etc.
  - ▶ Poisons
  - ▶ Nutritional factors
- 

# Morphological findings


## ▶ CYTOPLASMIC CHANGES:

- Increase eosinophilia → Loss of normal basophilia of RNA.  
→ Binding of eosin to denatured protein is increased.
- More homogenous appearance due to loss of glycogen content in the cytoplasm.
- Moth-eaten appearance.
- Calcification.

▶ NUCLEAR CHANGES:


- Earliest change is reversible clumping of chromatin and attach to nuclear membrane.  
( Reversible change )
- Pyknosis– Nucleus progressively shrunken in size and become a small wrinkled mass of tightly packed chromatin material.
- Karyolysis– Progressive dissolution of chromatin as a result of hydrolytic action of DNAase enzyme.
- Karyorrhexis – Nucleus break down in small fragments.

# TYPES OF NECROSIS


- ▶ Coagulative necrosis
  - ▶ Liquefactive necrosis
  - ▶ Caseous necrosis
  - ▶ Fat necrosis
  - ▶ Fibrinoid necrosis
  - ▶ Gangrenous necrosis(GANGRENE)
- 

# COAGULATIVE NECROSIS


- ▶ Common type, outline of cell is maintain.
- ▶ Coagulation of structural protein is main cause mainly due to ischemia.
- ▶ Cells shows classical changes of necrosis and general architecture of the tissue is well preserved for considerable time. e.g. Infarction, skin & mucous membrane by carbolic acid , formalin , Diphtheria , bacillary dysentery.

- ▶ Organ commonly affected– heart , kidney, spleen and limb(dry gangrene).
  - ▶ Gross change: Affected organ is dry, yellow ,pale and firm. It is wedge shaped in kidney and spleen.
  - ▶ Microscopic changes.
- 


# LIQUEFACTIVE NECROSIS

- ▶ Results from action of powerful hydrolytic enzymes.
  - ▶ Dead tissue undergoes softening and transforms into a liquid viscous mass.
  - ▶ Example is brain infarct, abscess anywhere, wet gangrene.
  - ▶ Microscopically pus consist of liquefied necrotic cell debris, dead leukocytes and macrophages.
- 

# CASEOUS NECROSIS

- ▶ It shows combined features of both coagulative and liquefactive necrosis.
  - ▶ Grossly affected organ is yellowish, granular and cheese like in appearance.
  - ▶ E.g. Tuberculosis.
- 

# FAT NECROSIS

- ▶ It is specific morphological pattern of cell death in adipose tissue due action of lipases.
  - ▶ E.g. Pancreatitis, breast necrosis.
  - ▶ Grossly it shows appearance of chalky white area .
  - ▶ Microscopically the necrotic fat cells appeared with shadowy outlines surrounded by inflammatory reaction.
- 

# FIBRINOID NECROSIS

- ▶ Characterized by deposition of fibrin like proteinous material in the tissue.
- ▶ Usually it present in autoimmune disease like polyarteritis nodosa , SLE, Rheumatic fever.

THANK YOU

