

# *LAMINATES & VENEERS*

PRESENTED BY : ABHISHEK PARMAR  
(2020)

# ***CONTENTS***

- **Introduction**
- **History**
- **Indications & contraindications**
- **Types of veneers & classification system**
- **Case Selection**
- **Clinical steps**
  - *Color and shade selection*
  - *Tooth preparation*
  - *Impression*
  - *Temporization*
- **Cementation – The adhesion Complex**
- **Failures**
- **Repair of Failures**
- **Advantages & Disadvantages**
- **Recent Advances- Lumineers**
- **Conclusion**
- **References**

- Restorative dentistry is an evolving specialty and technical innovations has a large role in determining how it is practiced.
- Earlier focus on the mere restoration of carious teeth has shifted to treatment for enhancement of the esthetic appearance of already healthy teeth
- Today, the dental profession strives not only to preserve healthy teeth with proper function, but also to create and enhance teeth that are esthetically pleasing as well.

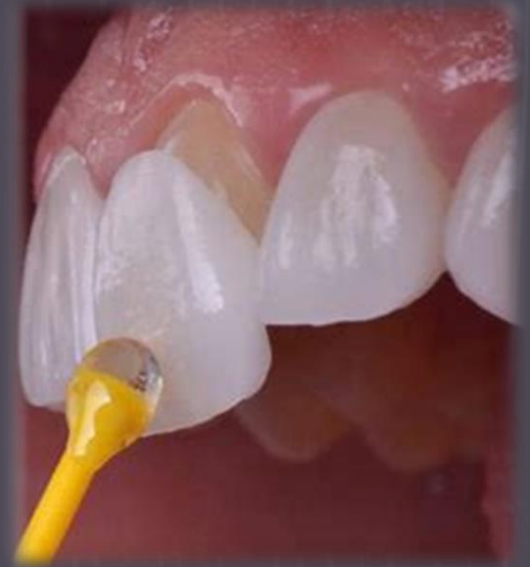

- It is estimated that as many as 50% of individuals seeking dental care are actually seeking esthetic self-improvement

*Mosby's Dental Dictionary defines Esthetic Dentistry as,*

*“The skills and techniques used to improve the art and symmetry of the teeth and face to enhance the appearance as well as the function of the teeth, oral cavity, and face.”*

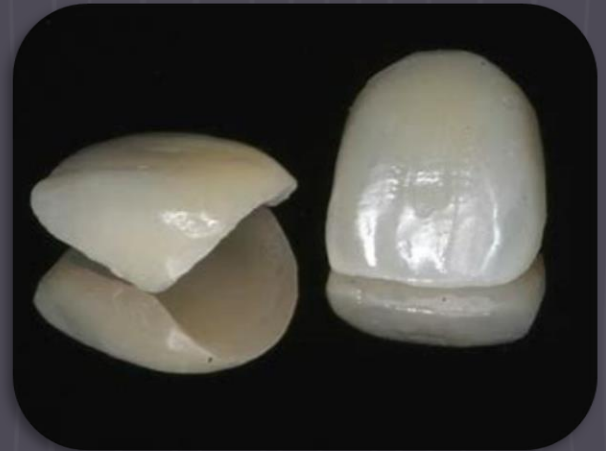- *Veneer is one of the most revolutionary techniques developed over the past 25 years*
- *First described in 1940 by Dr. Charles Pincus*
- *Conservative treatment for unaesthetic anterior teeth*



## ***VENEER***

*“Layer of tooth colored material that is applied to a tooth for esthetically restoring localized or generalized defects or intrinsic discolorations”*

*--Sturdevant's Art & Science of Dentistry*



**In the late 1970s, Direct laminate veneers** were introduced, which used light-cured composite resin to overlay the entire facial surface, allowed **great flexibility in both shaping and shading teeth.**

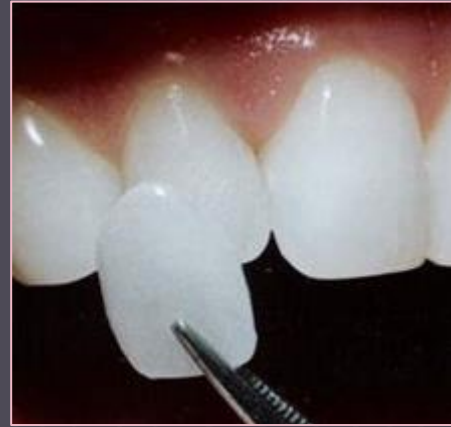However, they were

- **Time consuming**
- **Required substantial artistic skill.**
- **Poor color stability and wear resistance**

**Indirect or preformed veneers** they exhibited greater color stability and stain resistance than early direct composite resin veneers, the composite resin-to-laminate veneer bond proved to be a fatal weak link

In 1983, the *porcelain-laminate veneer* was introduced. It combined

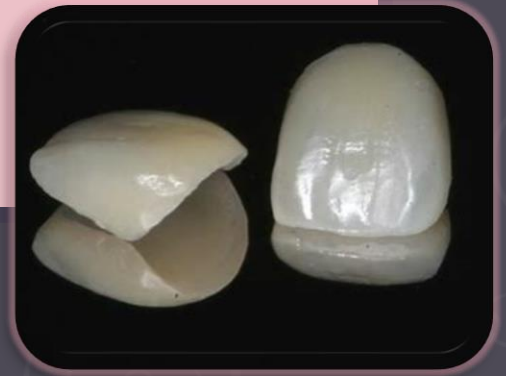- Esthetic and positive tissue response of porcelain
- Adhesive strength of acid-etch retained restorations
- Convenience of a laboratory-fabricated restoration



“

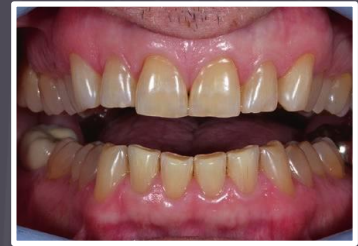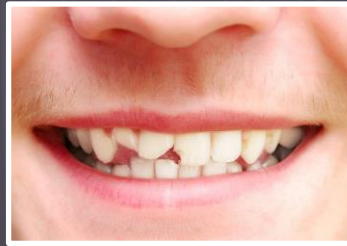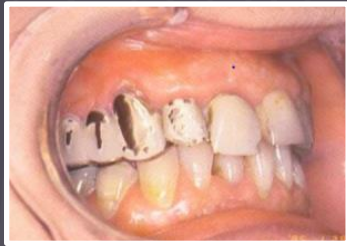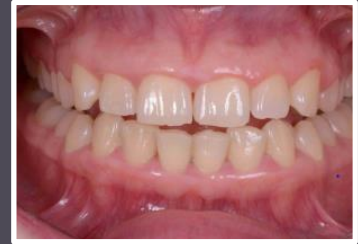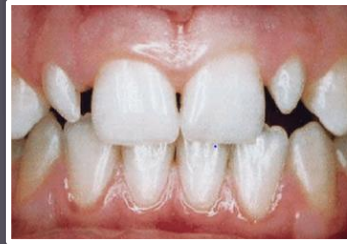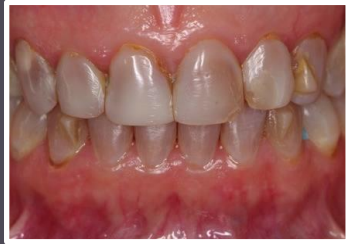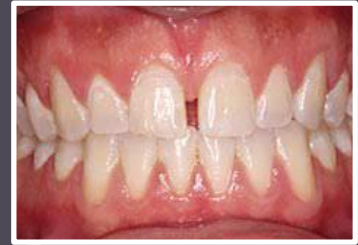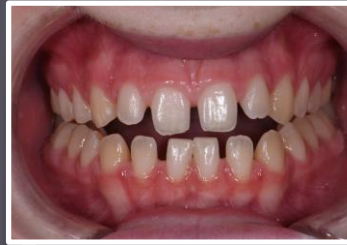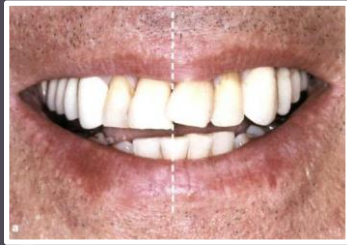*“A thin bonded ceramic restoration that restores facial surface and part of the proximal surfaces of teeth that requiring aesthetic restoration.”*

-GPT





# *Indications*



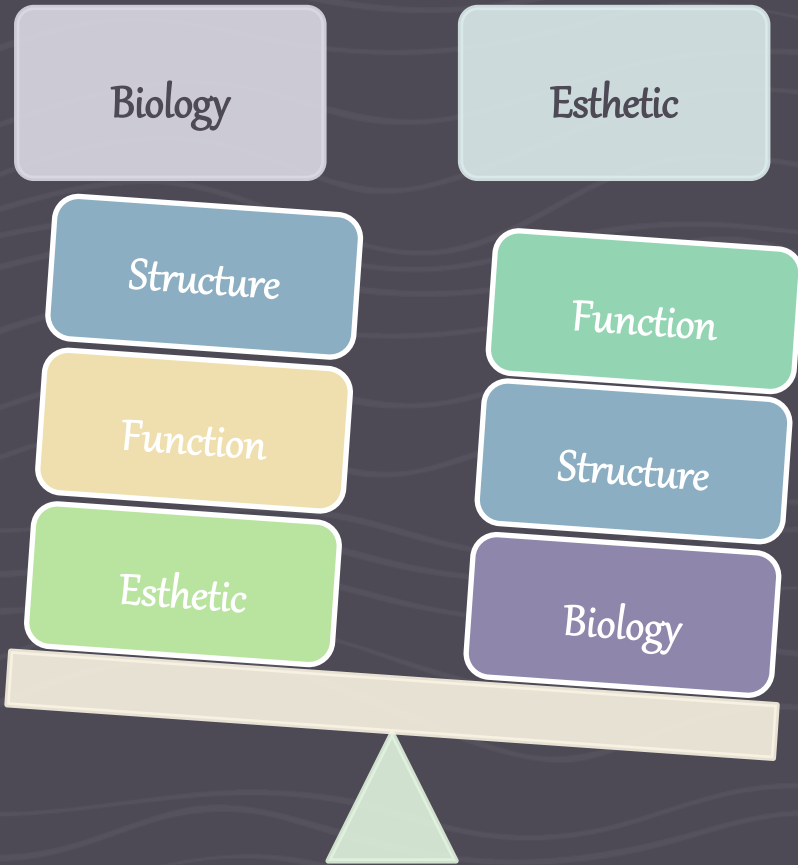
## *Contraindications*

- Large Diastemas
- Contact Sports
- Severe crowding
- Parafunctional Habits like Bruxism
- Mouth Breathers
- Periodontal diseases

2

# *Case selection and treatment planning*

*“Beginning with esthetics in mind”*



**Sequencing the planning process**

# ANATOMY OF A SMILE

## Macro-esthetics

Facial proportions  
in all three planes  
of space

- Frontal Examinations
- Profile Analysis

## Mini-esthetics

The dentition in  
relation to the face

- Dental midline
- Transverse cant of occlusal plane
- Degree of incisor and gingival display
- Buccal corridors
- Smile arc

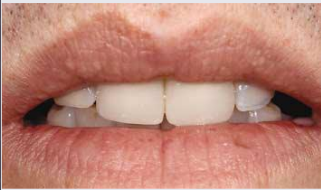## Micro-esthetics

The teeth in relation  
to one another

- Tooth proportions
- Tooth dimensions
- Tooth inclinations
- Interdental contact area & Embrasures
- Tooth shade and color.

1

Central incisor  
position in relation  
to upper lip



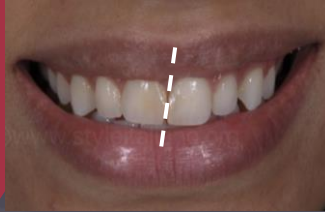
2

Maxillary Dental  
Midline

Mediolateral  
inclination  
of the maxillary  
central incisors

3

Labiolingual  
Positioning of  
maxillary anterior  
teeth



4

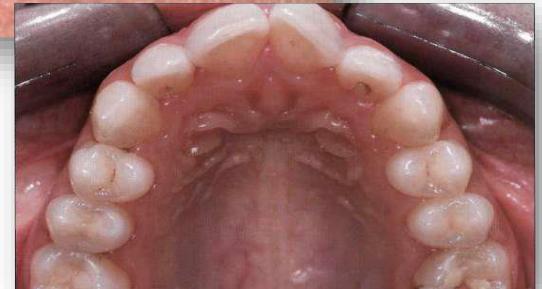
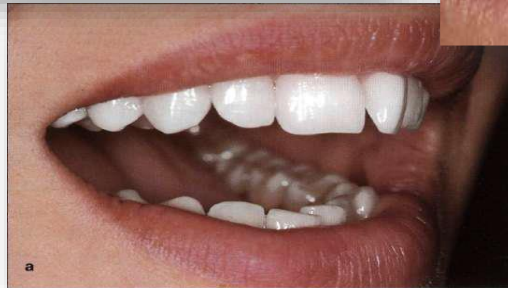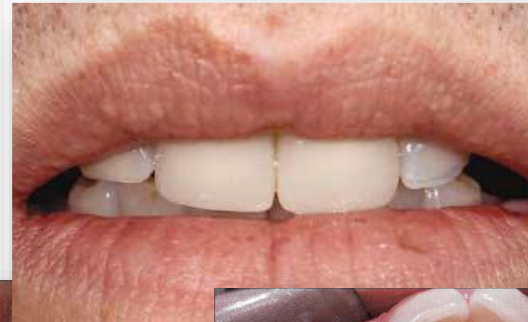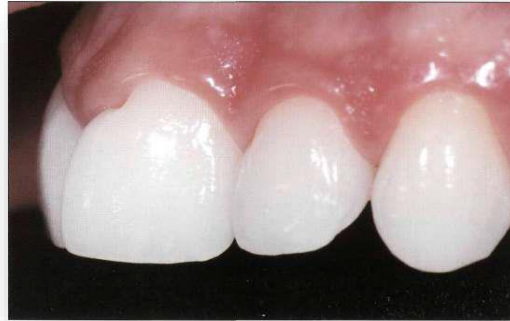Determining the  
gingival levels and  
interdental papilla  
Relative to overall  
crown length

- **Defining our goals** is as essential as the steps necessary to reach them.
- Once the esthetic needs are confirmed, the dentist should **identify the potential difficulties**.
- Careful **evaluation of present clinical situation and radiographic examinations**.

# *Factors affecting Treatment Planning*

## Tooth Position

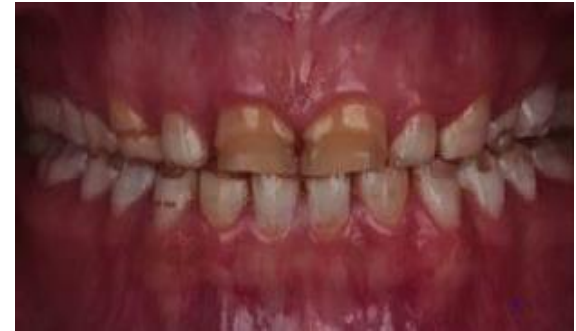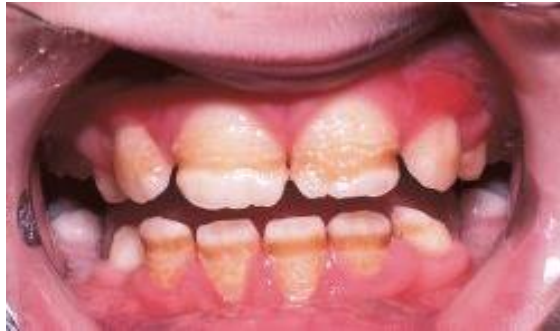- Alignment in the arch
- Rotations
- Lingual or Labial positions



## *Factors affecting Treatment Planning*

### Discoloration

- Deeply pigmented teeth (Severe Fluorosis)
- Hereditary Enamel Defects



## *Factors affecting Treatment Planning*

### *Aged/Worn-Out teeth*

- Thinning of the existing enamel surfaces

↓ Thickness of enamel



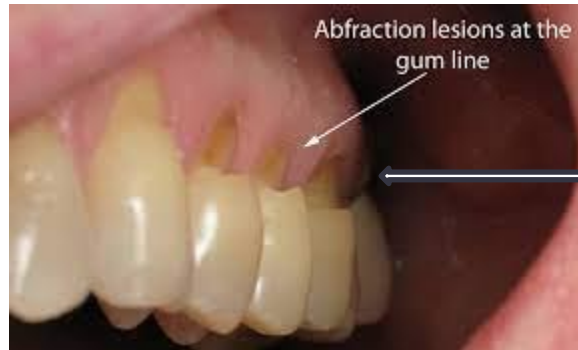Poor stress distribution  
↑ Tooth flexion under occlusal loading  
↓ Surface Area for bonding

✓ This is vitally important to respect the remaining thickness of enamel

# *Factors Affecting Treatment Planning*

## Occlusion

- Heavy Function or Parafunctional habits
- Unfavorable Occlusal relations

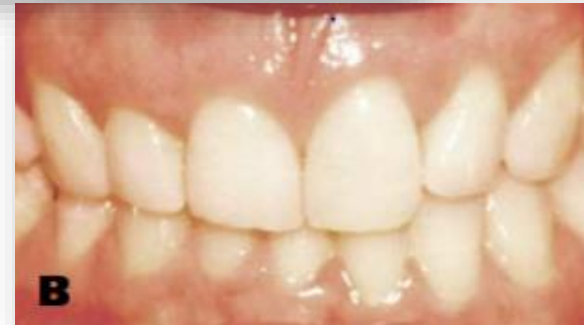
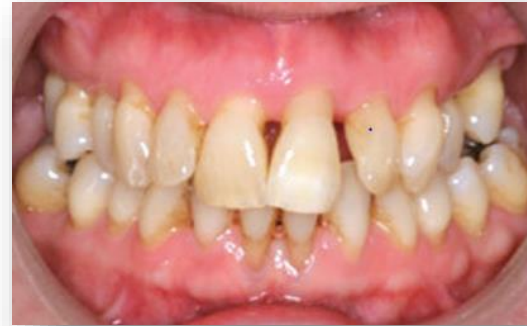
Indicates heavy occlusal loading

# *Factors Affecting Treatment Planning*

## Gingival Margins

- Gingival Recessions
- Root Exposures
- Cant of gingival margin



“

*Determine if the arrangement of the maxillary anterior teeth  
can be accomplished restoratively???*

*If not, whether the patient will require previous interventions  
to facilitate restoration*

# Interdisciplinary management of anterior dental esthetics

Frank M. Spear, DDS, MSD; Vincent G. Kokich, DDS, F

The second aspect of esthetic tooth positioning to be evaluated is the maxillary dental midline. If the midline is deviated to the right or left, studies have shown that midline deviations of up to 3 or 4 mm are not noticed by laypeople if the long axes of the teeth are parallel with the long axis of the face.<sup>14,15</sup> So perhaps the most important relationship to evaluate is the mediolateral inclination of the maxillary central incisors. Researchers have found that if the incisors are inclined by 2 mm to the right or left, laypeople regard this discrepancy as unesthetic.<sup>15,16</sup> A canted midline can be corrected with orthodontics<sup>17</sup> or restorative dentistry.<sup>18</sup> Usually the decision will depend on whether the maxillary incisors will require restoration.



# *Clinical Procedures*

## *Composite Mockup*

Direct application of composite without surface preparation that perches itself on the teeth

Diastema

Misshapen or  
malpositioned  
teeth

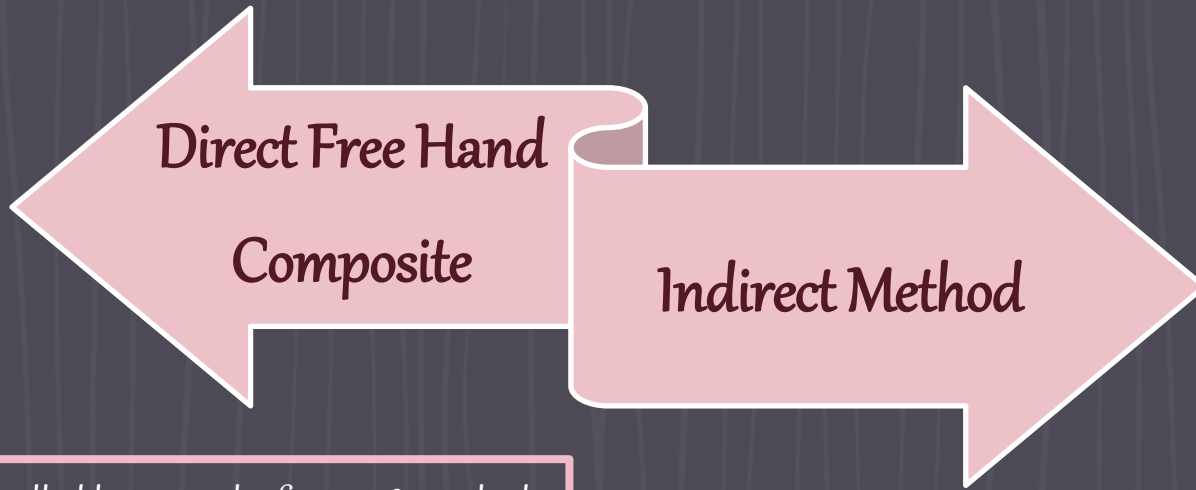
Alteration of  
buccal-lingual  
position of the  
incisal edge

To establish a  
favorable buccal  
corridor.

Fractures

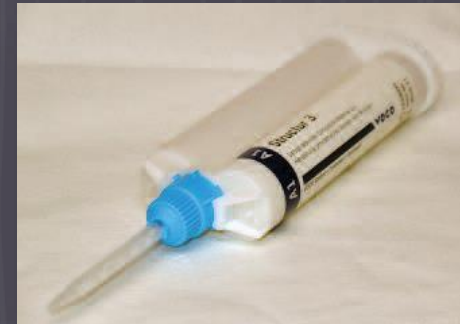Correction of  
incisal length of  
anterior teeth

Alteration of  
incisal edge plane




- Composite is rolled between the fingers & applied over the dried tooth structure.
- It is shaped with the help of the fingers and special hand carving instruments and then light cured

- Fabrication of wax pattern & Silicone Index



## Direct Technique

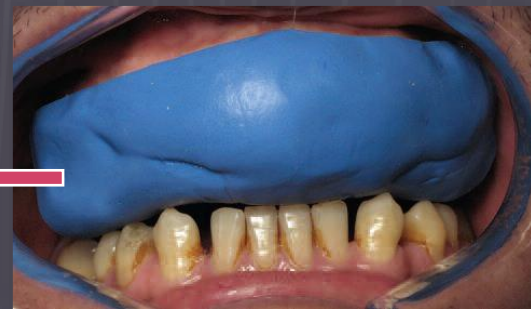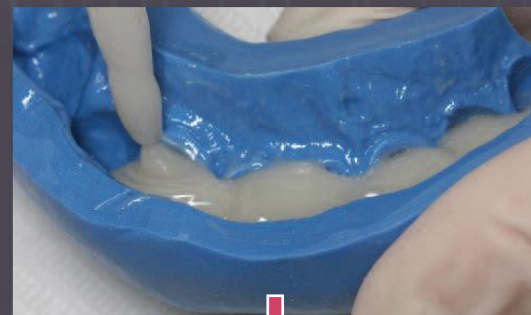
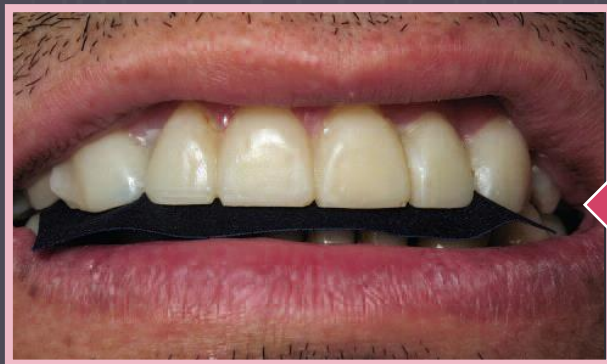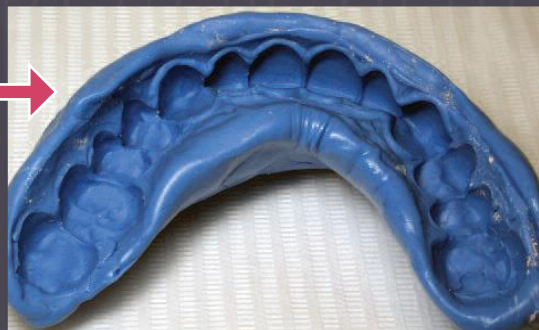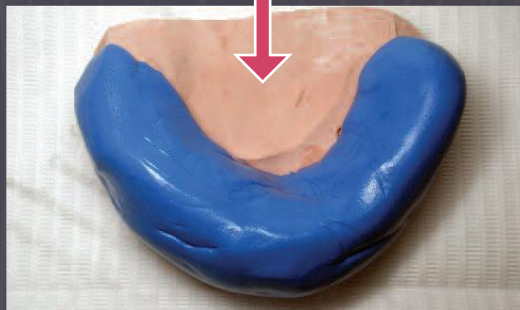
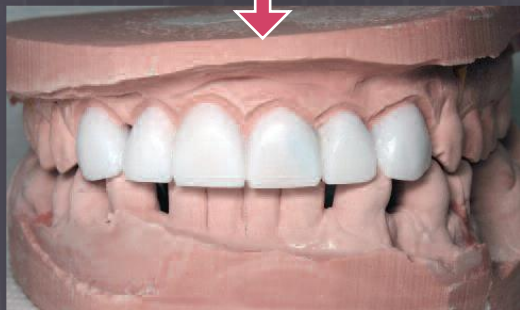


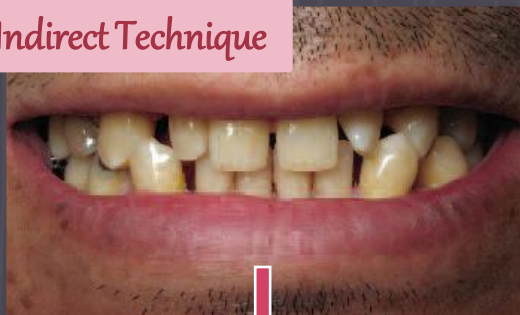Instruments used for diagnostic preview/mock-up – 1½” Indianhead mirror (front face) [Miltex – York, PA] – Caliper/orthodontic divider

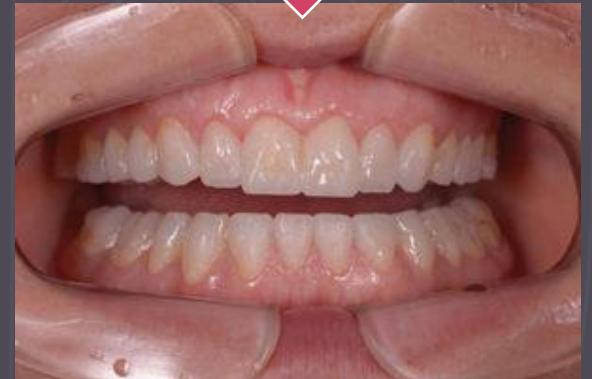
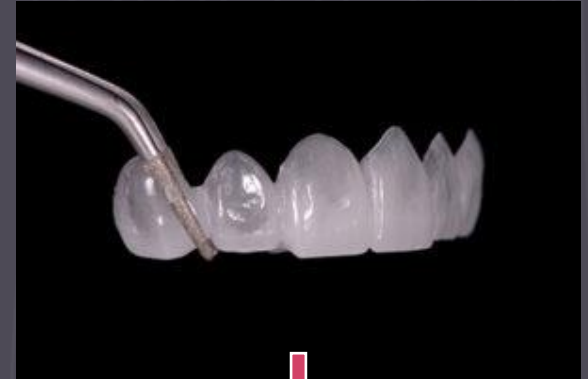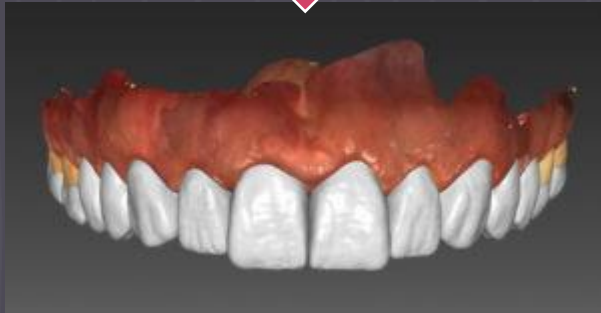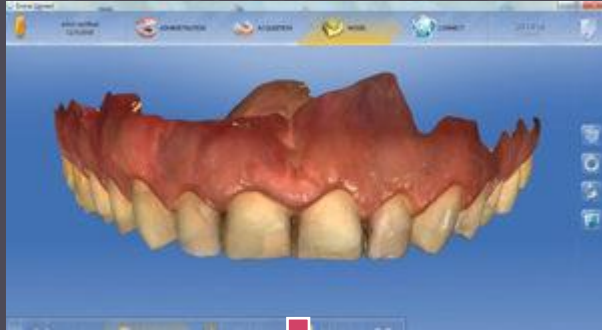#11 Bard Parker Blade – Disposable plastic/silicone cuticle pusher – Flat, chisel-shaped ceramist brushes



# Indirect Technique

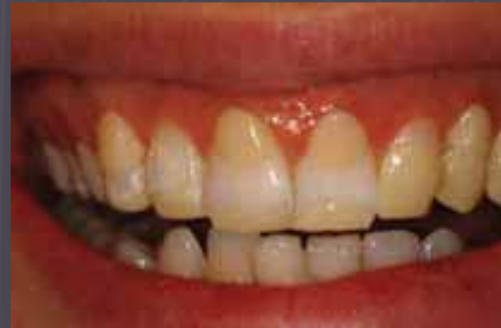
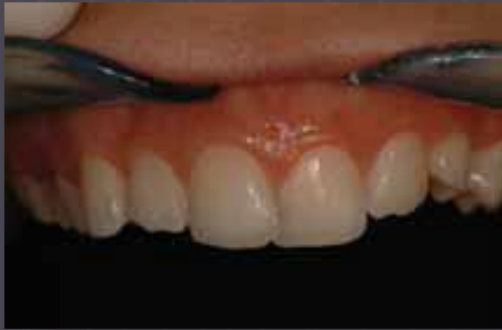
# Digital Mock-Up



## *Reverse Mockup*

- Indicated for alteration of the gingival levels as in case of short clinical crowns



- Transparent template can be built which can be used as a surgical stand, to dictate where the new gingiva should be located

## *Advantages of Mockup*

### *Indicative Preview of desired occlusal scheme.*

- Protrusive and lateral excursive jaw movements can be controlled
- Especially when lengthening of mandibular or maxillary teeth has to be done

### *Short-term provisional:*

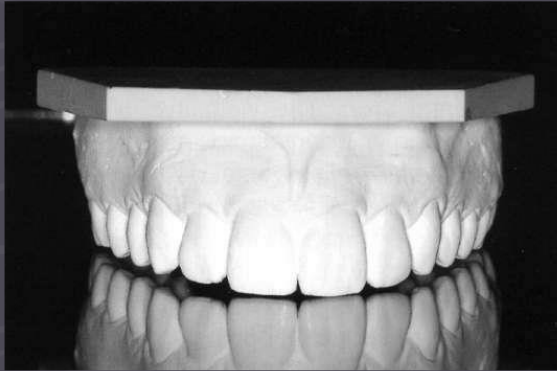
- Patient's lips to adjust to the uncomfortable pressure from the mock-ups.

### *Laboratory Communication:*

- Best way to transfer the information to the lab.
- Simple and self explanatory

## Wax-up for Tooth Preparation:

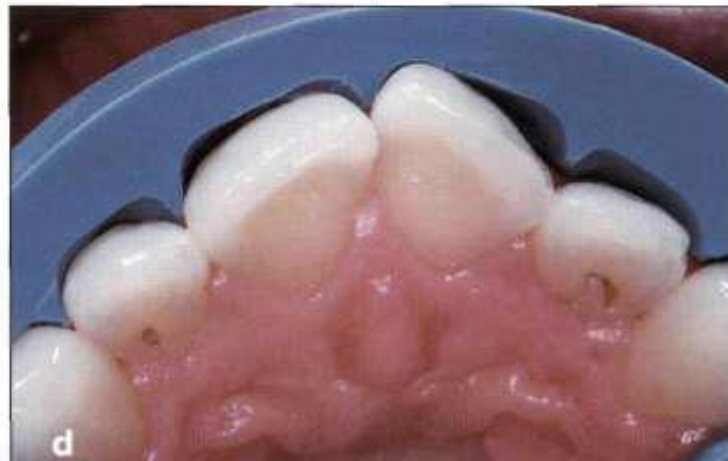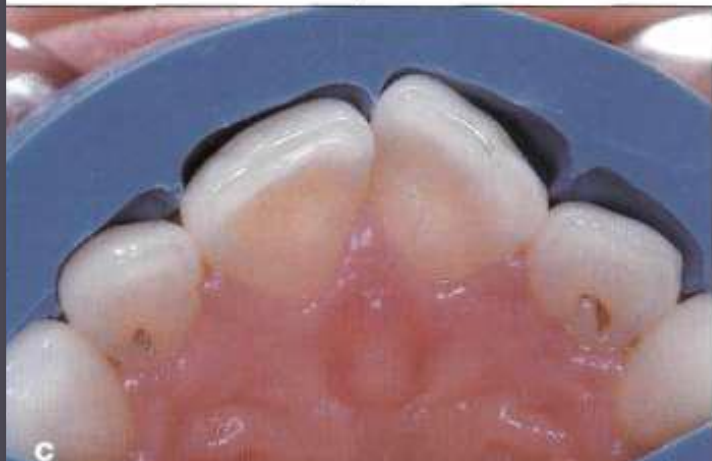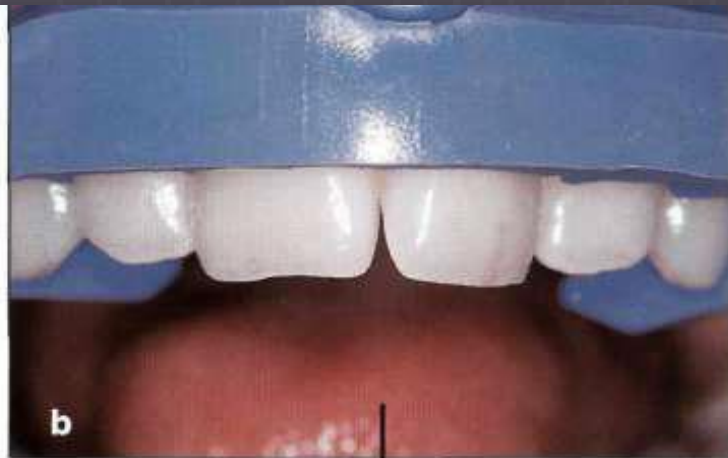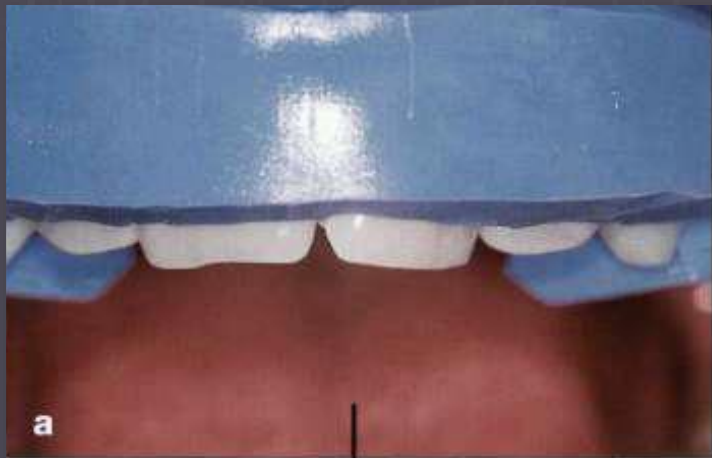
- ✓ *The amount of tooth reduction should never be made according to the existing tooth surface but rather to the final volume of the restoration.*

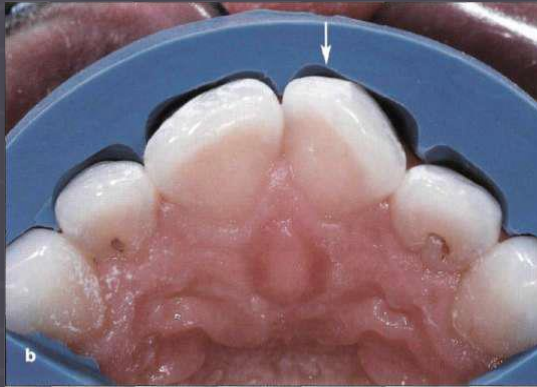

- The spatial orientation and architectural dimensions of the wax-up will be used to predesign and validate the intended preparations
- A stone model is duplicated from this wax-up in order to prepare the silicon index, transparent template

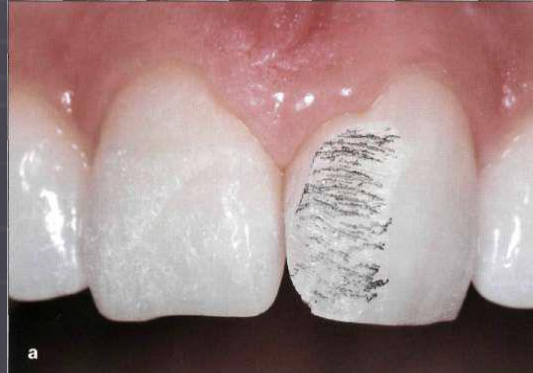## *Aesthetic Pre- Recontouring (APR)*

- Necessary mean reduction of the tooth surface that protrudes out before the actual material preparation
- The index is then placed over the dental arch in order to visualize the existing positions of those teeth on the dental arch, relative to the final outcome of the wax-up and veneer

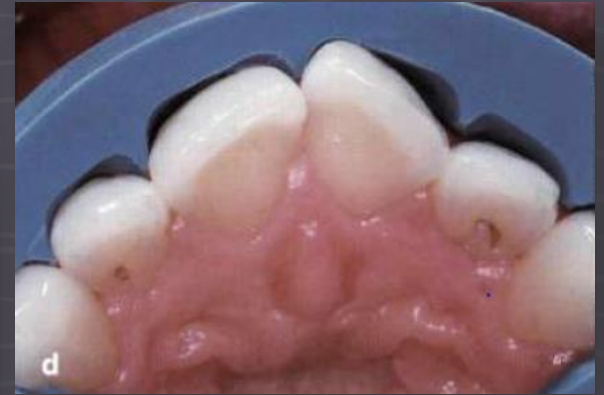



**Facially protruding portions are in contact with the index, preventing passive seating of the index over the teeth.**



**The facially protruded central is trimmed down with a fissure diamond bur.**

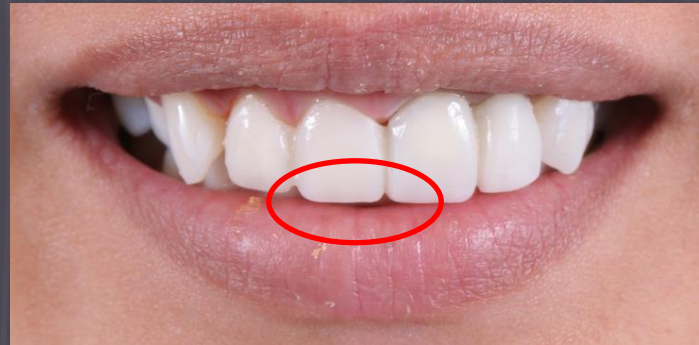
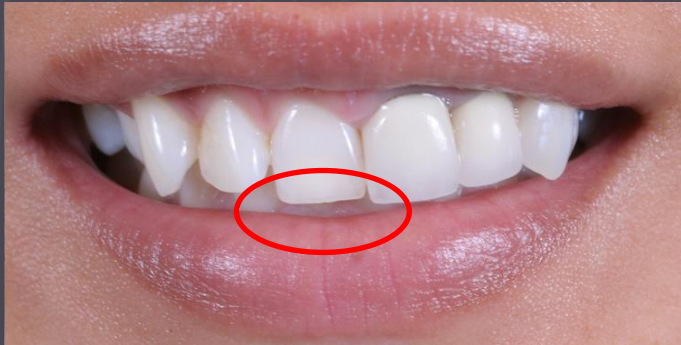
**The silicone index can passively sit on the unprepared teeth.**

## *Procedure for APR*

### *Determining incisal edge position & midline :*

- If the mid-line is not perpendicular to the horizon or the pupillary line, all symmetry will be distorted
- Difficult for dentist to correct the midline if the teeth are not prepared enough to supply the space to adjust to it.



### *Exacting the facial contours :*

- The facial inclination and/or rotation are not corrected before treatment, The final preparation will also result in a facial inclination or rotation that will be very difficult to correct with PLV that has a maximum thickness of 0.3-0.5 mm

### *APR of gingiva :*

- Gingival contouring to achieve proper height
- Zenith points can also be changed, especially in the diastema cases
- Can be accomplished with a diode laser

## *Aesthetic Pre- Evaluative Temporaries (APT)*

- The amount of tooth reduction should never be made according to the existing tooth surface but rather to the final volume of the restoration
- Indicated in complicated cases like **ROTATED TEETH, LABIO-LINGUO VERSION TEETH, AGED/WORN-OUT TEETH**
- In order to fill the esthetically missing volume as in linguallly rotated teeth

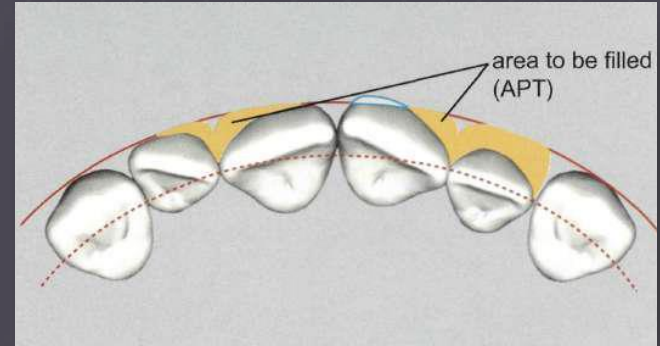
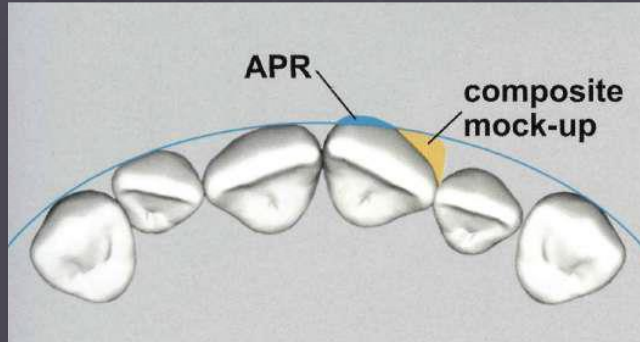
## *Gurel Technique*

- Composite resin can simply be added to the facial surfaces of lingually positioned teeth/worn-out tooth.
- With spot etching and bonding up to where the tooth needs to be buccally reoriented or filled by volume

For those teeth that are extremely lingually inclined, orthodontic intervention is a must

1 or 2 Teeth rotated

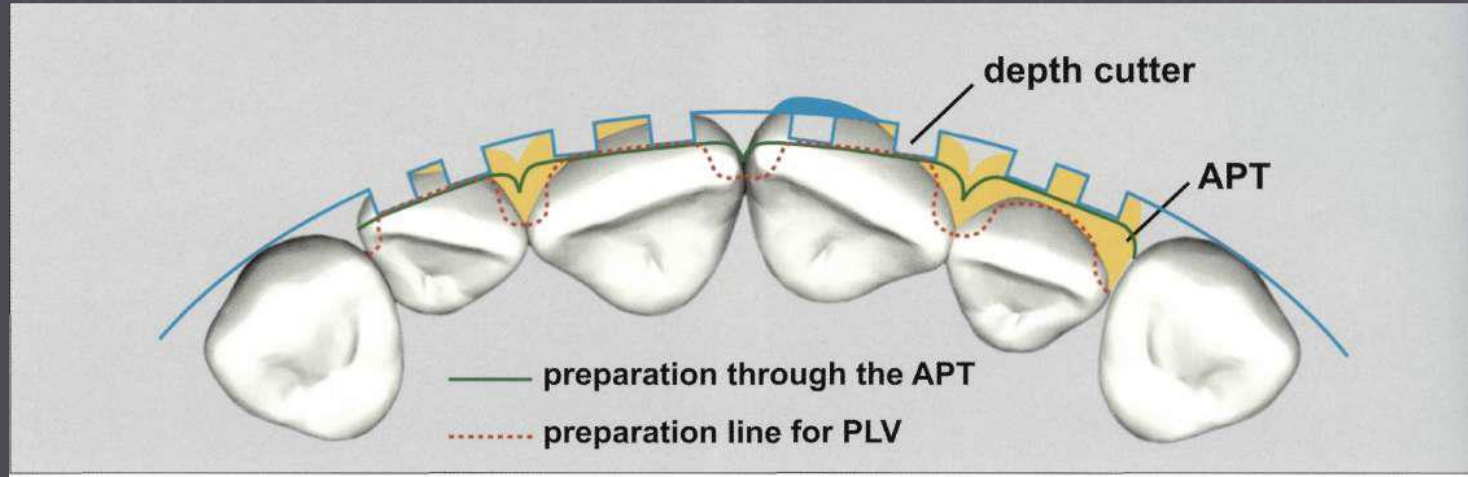
Multiple rotated teeth



“

▷ *IS IT REALLY NEEDED??*

The depth cutters always reduce the same amount of tooth that their grid depth indicates



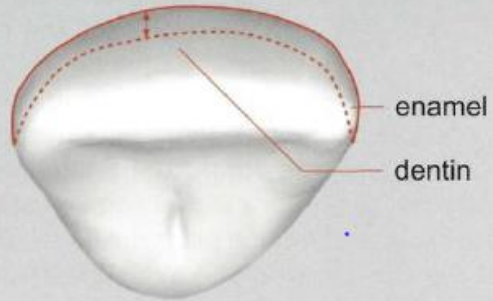
*What if the lingual inclination of the tooth is more than the depth of our depth cutter??*

*Amount of mock-up composite added to that surface properly to align its position over the dental arch might be thicker than our intended reduction (i.e. > 0.5 mm)*



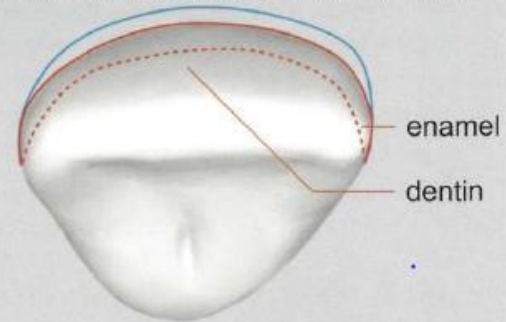
*Preparation will not even reach the enamel surface. In such instances, the APT should be removed and the surface of the untouched enamel be roughened, to remove the surface luster for improved bonding*

facially worn-out thin enamel

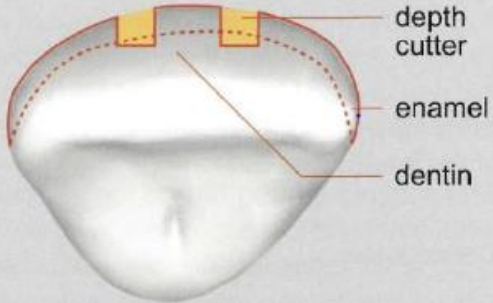


a

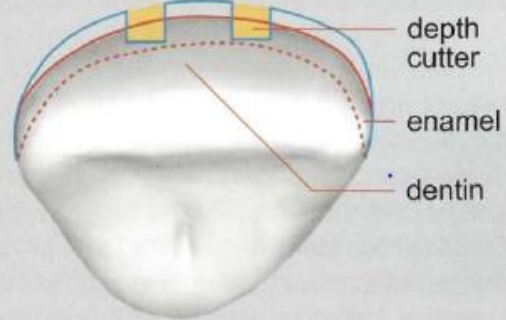
the level where the enamel should be rebuilt



b



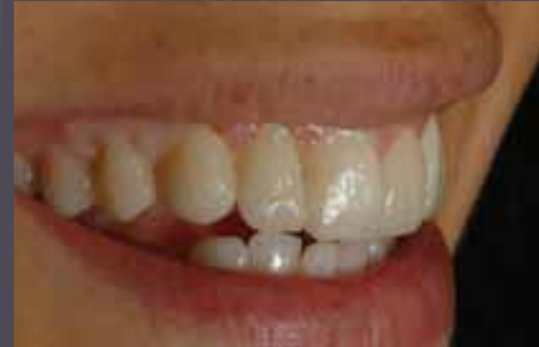c

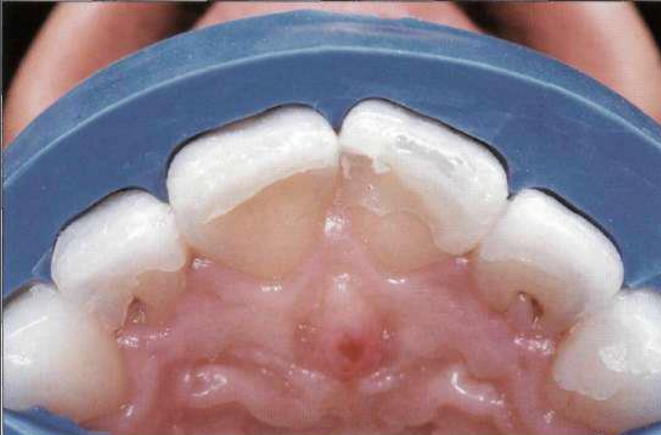

d

## *Advantages of APT*

- For visualizing the final esthetic treatment outcome
- Esthetic adjustments before preparation
- Act as a guideline during actual tooth preparation





*The exact facial thickness of the APT, and so of the final outcome, can be double checked with the help of the silicone index. Note that there is no gap between the silicone index and APT.*



# *Classification of Veneers*

*Based on depth  
of preparation*

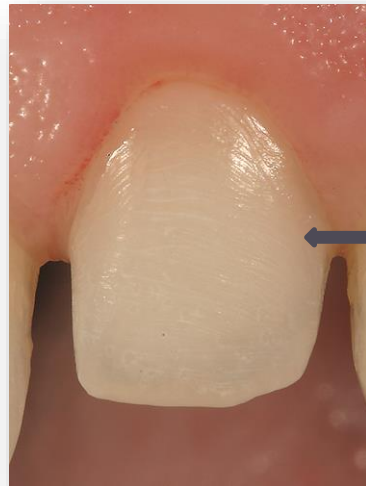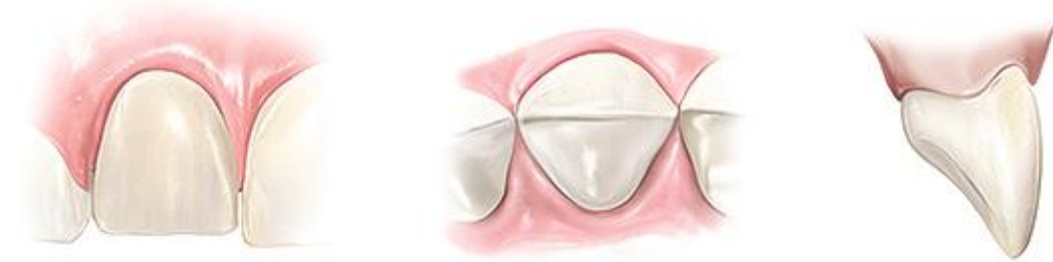*LeSage veneer classification system:*

Divides preparation and veneering into

- Reduction (referred to as space requirement, working thickness, or material room),
- Volume of enamel remaining
- Percentage of dentin exposed

| Reduction   | Facial   | Enamel remaining |
|---|--|------------------|
| <b>CL-I</b> No-prep or practically prep-less          | Detectable with magnification, with or without gingival finish lines | 95–100%          |
| <b>CL-II</b> Modified prep-less or minimally invasive | Up to 0.5 mm   | 80–95%           |
| <b>CL-III</b> Conservative design                     | 0.5–1 mm   | 50–80%           |
| <b>CL-IV</b> Conventional all-ceramic design          | 1+ mm  | <50%             |

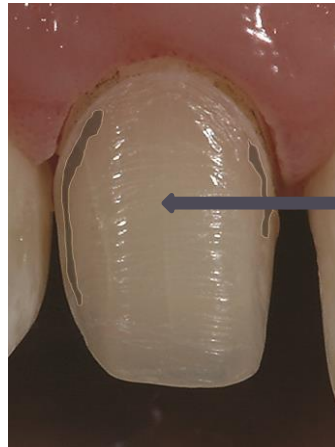
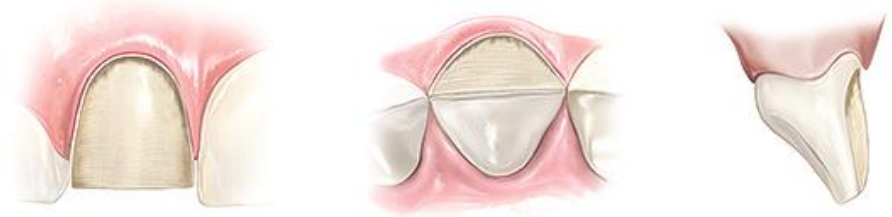*Class I  
(No Prep/  
Practically Prep-  
less Veneers)  
Loupe detectable  
margin*



- 95-100% enamel volume remaining
- No dentin exposed
- Subgingival finish line due to change in cervical contour is required to close diastema on M-D sides

*Class II  
(Minimally  
invasive/  
Modified Prep-  
less)*

*upto 0.5mm reduction*



80-95% enamel volume remaining

10-20% dentin exposed

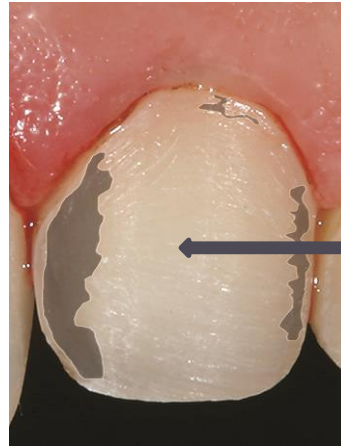
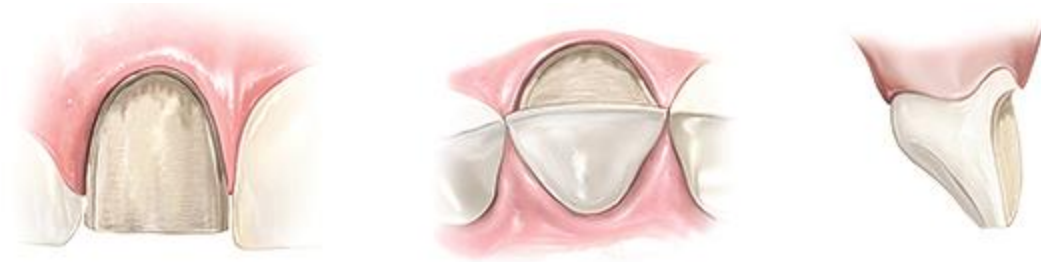Complete enamel periphery

*Classification I, II—both incorporate “Addition Veneers”.*

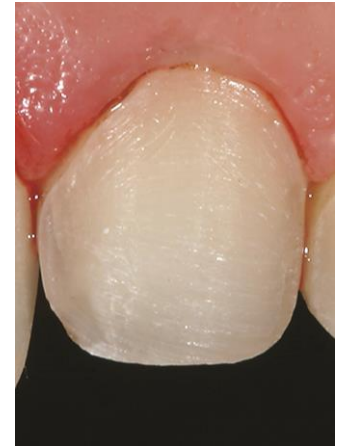### **Indications**

- Peg laterals
- Genetic anomalies producing smaller teeth
- Short and worn teeth,
- Orthodontics leading to a narrow arch
- Patients with larger lips

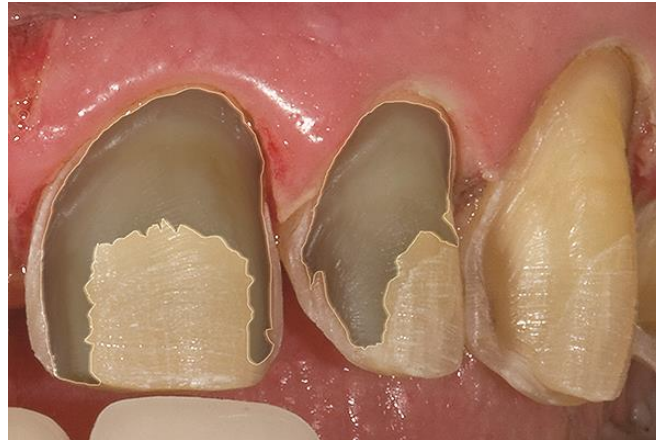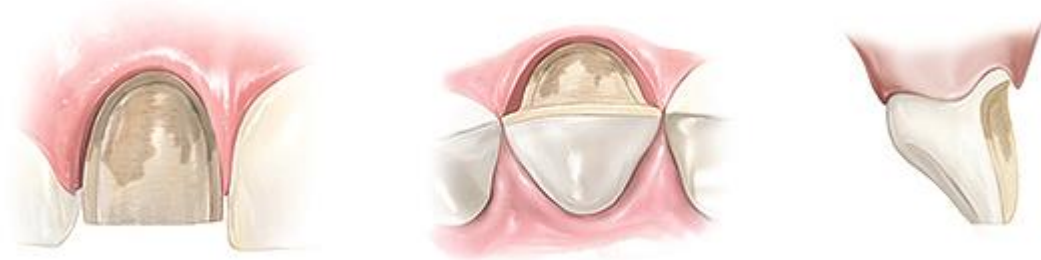***Class III  
(Conservative  
Preparation)  
0.5-1 mm reduction***



60–80% enamel volume remaining  
20–40% dentin exposed  
More than 70% enamel periphery



*Class IV  
(Full veneer)  
>1 mm reduction*



- 50% enamel volume remaining
- >40% dentin exposed
- Margins with 30% enamel periphery

***Based on  
Preparation Design***

**Window Preparation**

(Incisal Edge is Preserved)

**Feather Preparation**

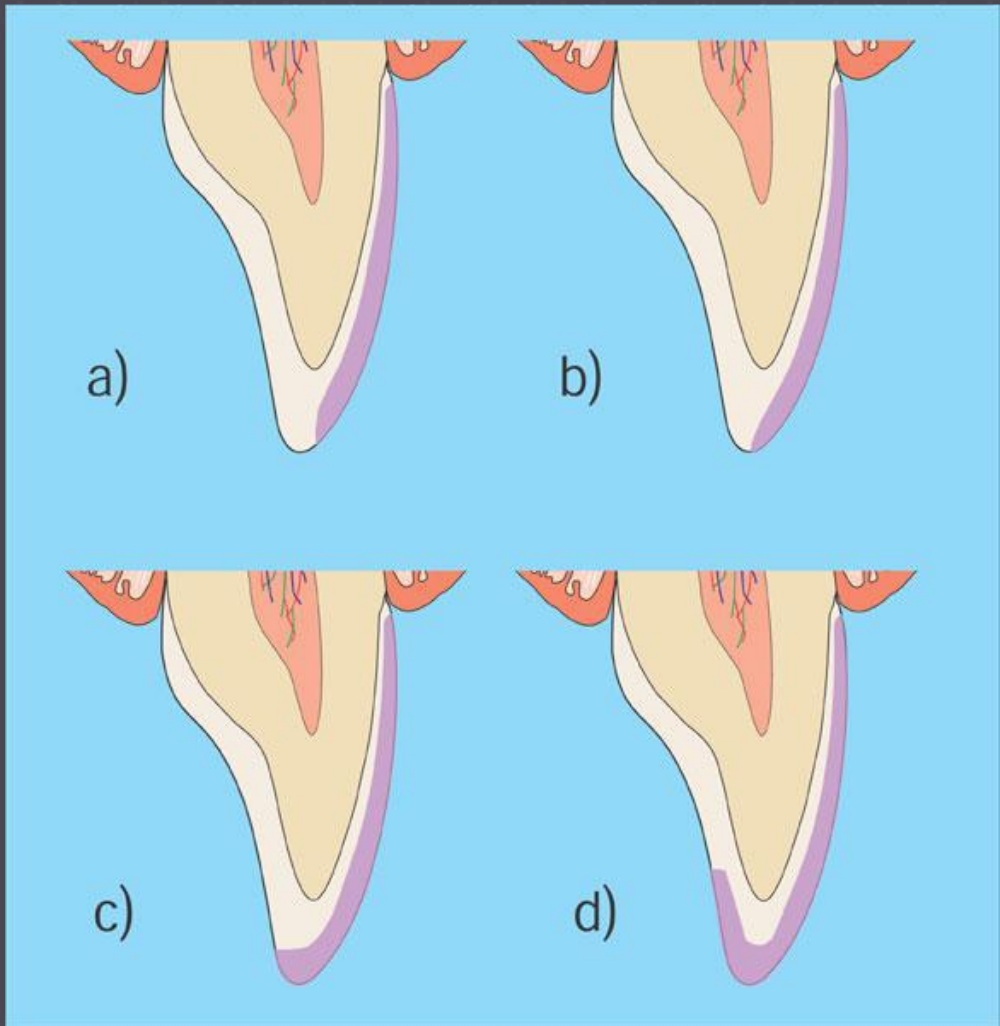
(Incisal edge is prepared bucco-palatally without reducing length)

**Bevel Preparation**

(Incisal edge is prepared bucco-palatally with upto 0.5mm reduction in length)

**Incisal Overlap**

(the veneer is extended to the palatal aspect of the tooth)



## *Window Preparation*

- Veneer preparation is taken close to but not up to the incisal edge

Natural enamel is retained over the incisal edge

Most Conservative preparation design

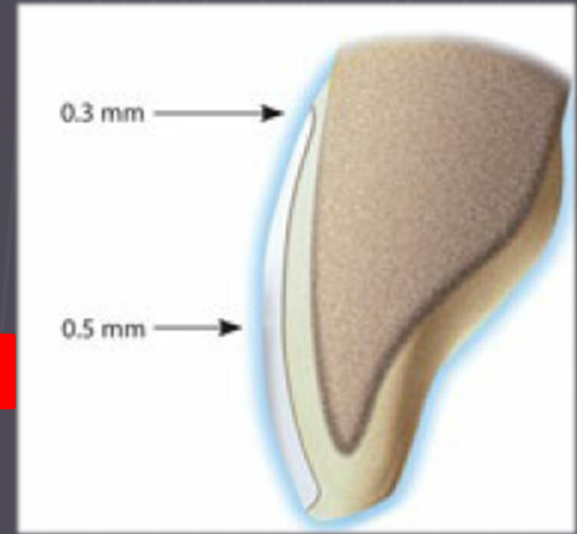
Withstand axial stresses most favorably

Incisal Edge is weakened

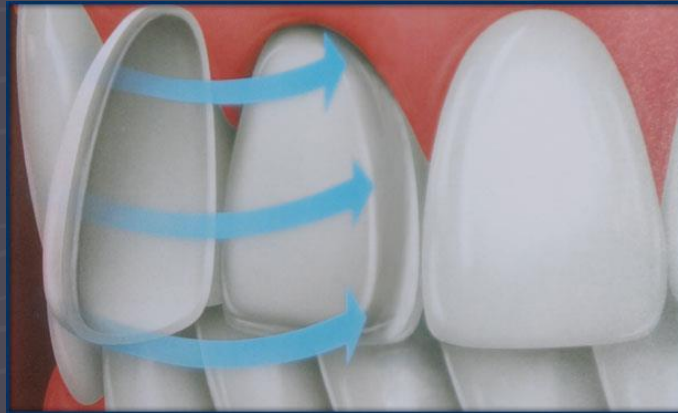Margins will become vulnerable if there is incisal edge wear

Visible Composite veneer interface

Least restricted path of insertion



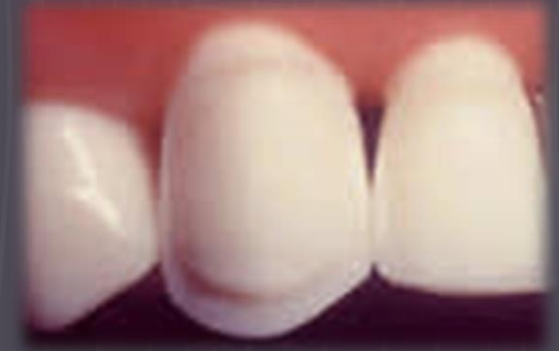- ✓ Most common indication is Maxillary Canine with appropriate length and incisal edge but a large lingual wear facet extending into incisal edge



- ✓ Preparation of choice when strength is the first priority

## *Feather Edge/ Incisal Chamfer*

- Veneer preparation is taken upto the height of incisal edge but edge is not reduced in length



Preserves natural palatal guiding surface of tooth.

Fragile at the incisal edge

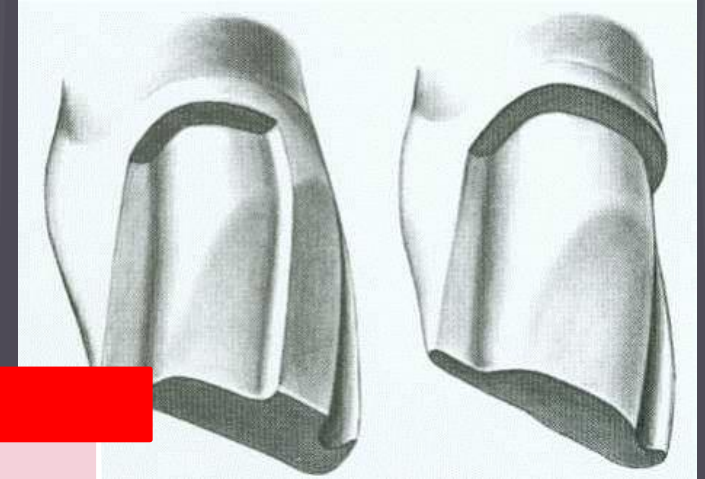
Subjected to peel/shearing forces during protrusive guidance

Visible Composite veneer interface

Least restricted path of insertion

## *Butt joint/Bevel preparation*

- The incisal bevel preparation (butt joint) with 0.5- to 1-mm incisal reduction




Allow incisal characterization to give natural appearance.

Positive seat during try-in and cementation

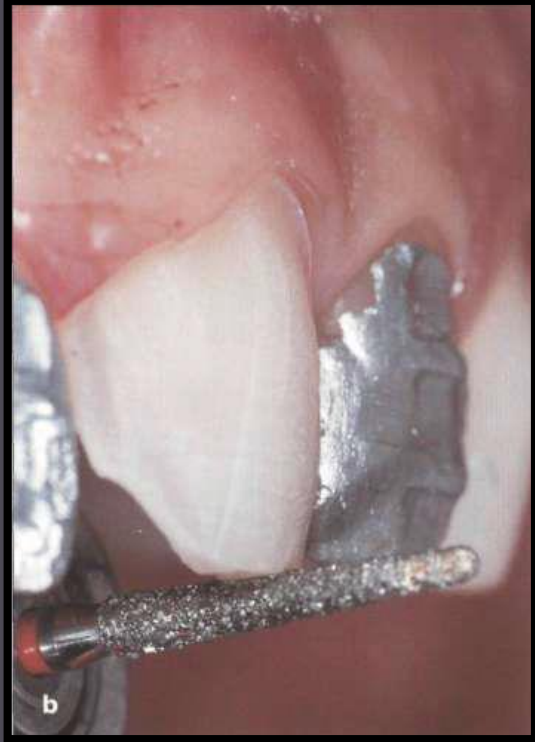Reinforcement of incisal edges

Provides favorable ceramic/luting composite ratio on palatal surface

- *A flat incisal surface that emerges perpendicular to the angle of the final emergence profile*
- *Place the margin finish line 2.00-2.5 mm down from the incisal on the lingual, away from the incisal edge*

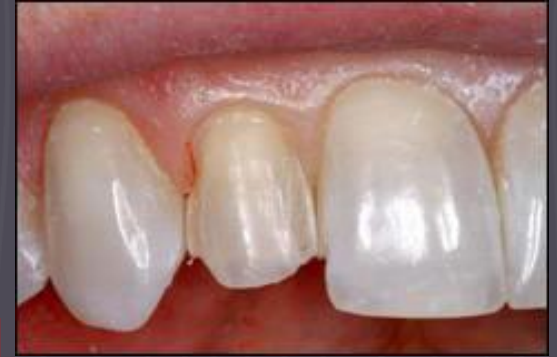

- ✓ *The only true mechanical indications of a butt joint are the cases where the proximal preparations are extended all the way to the Palatal*



*The bur is held 90° to the incisal edge and the necessary preparation is done.*

## *Incisal Overlap*



Increases the bulk of porcelain

Prevents shearing under functional loads

Most restricted path of insertion

Distributing the occlusal load over a wider surface

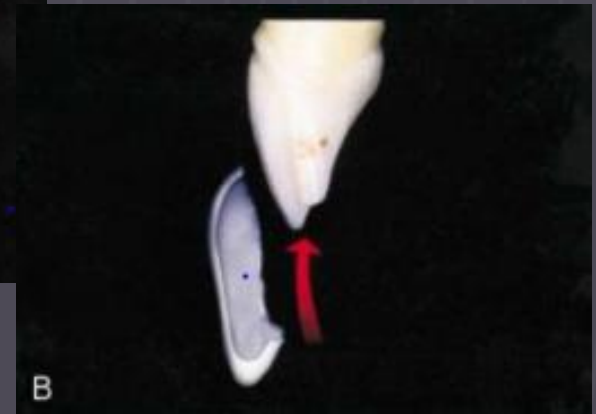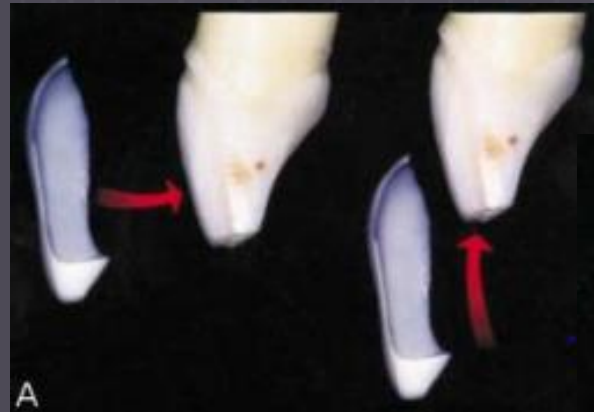

Increased risk of cohesive fracture due to maximum stress placed on the veneer

- ✓ The most common indication if the incisal edges are thin bucco-lingually or when an increase in crown length is desired

It is also emphasized that *only when occlusal or esthetic requirements necessitate should the incisal edge be incorporated into the preparation.*

## Path of insertion of a veneer with incisal overlap/butt joint preparation design??

- ✓ The only true mechanical indications of a butt joint are the cases where the proximal preparations are extended all the way to the Palatal



## What should be the distance of the preparation margin from incisal edge??

delicate incisal edge configuration where the incisal edge grooves are connected.<sup>91</sup> This will place the margin finish line 2.00-2.5 mm down from the incisal on the lingual, away from the incisal edge while creating a pleasing length, form and incisal characterization, allowing the c much more flexibility.

the finish line on the central contact points. In the case of a worn incisal a 2.0-2.5 mm reduction from the desired length of the finished veneer is required.<sup>10</sup> If the already existing tooth length is 1.5 mm shorter than the expected final outcome, than in order to achieve a 2.0 mm incisal reduction, only 0.5 mm of preparation will be sufficient. In any of these cases, the fracture potential of the final restoration can be avoided by the rounding of the incisal line angles that reduce the internal stress.<sup>182</sup>

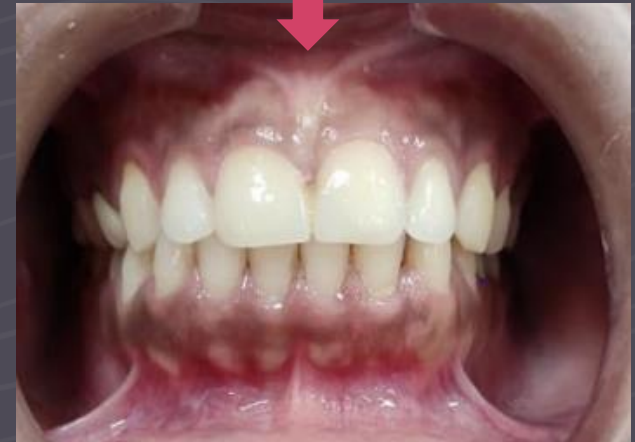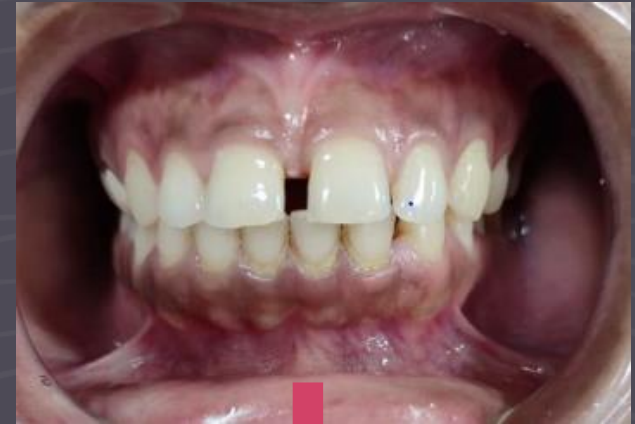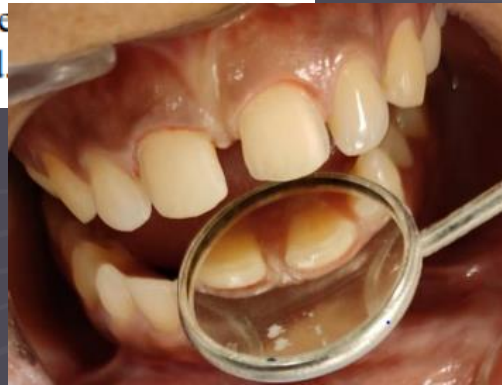# Midline Diastema Correction by Laminate Veneer - A Case Report

Baisakhi Mallick<sup>1</sup>, Mandira Ghosh<sup>2</sup>, Rony Samaddar<sup>3</sup>

<sup>1</sup>Clinical Tutor and Demonstrator, <sup>2</sup>Associate Professor,  
Department of Prosthetic Dentistry, Dr R Ahmed Dental College and Hospital, Kolkata-14  
<sup>3</sup>House Surgeon, Department of Dentistry, NRS Medical College and Hospital, Kolkata-14

Corresponding Author: Baisakhi Mallick

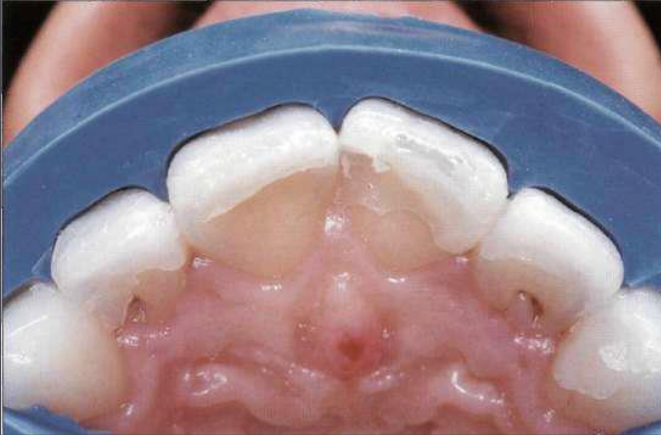0.5 mm depth cuts were prepared in the incisal surface of tooth <sup>[7,8]</sup> (pic 4). The incisal surface was reduced in a manner similar to incisal butt-joint preparation. The lingual finish line was re round-end tapered diamond





# *Tooth Preparation*

*“Instruments do not create beauty, people do”*



*The exact facial thickness of the APT, and so of the final outcome, can be double checked with the help of the silicone index. Note that there is no gap between the silicone index and APT.*

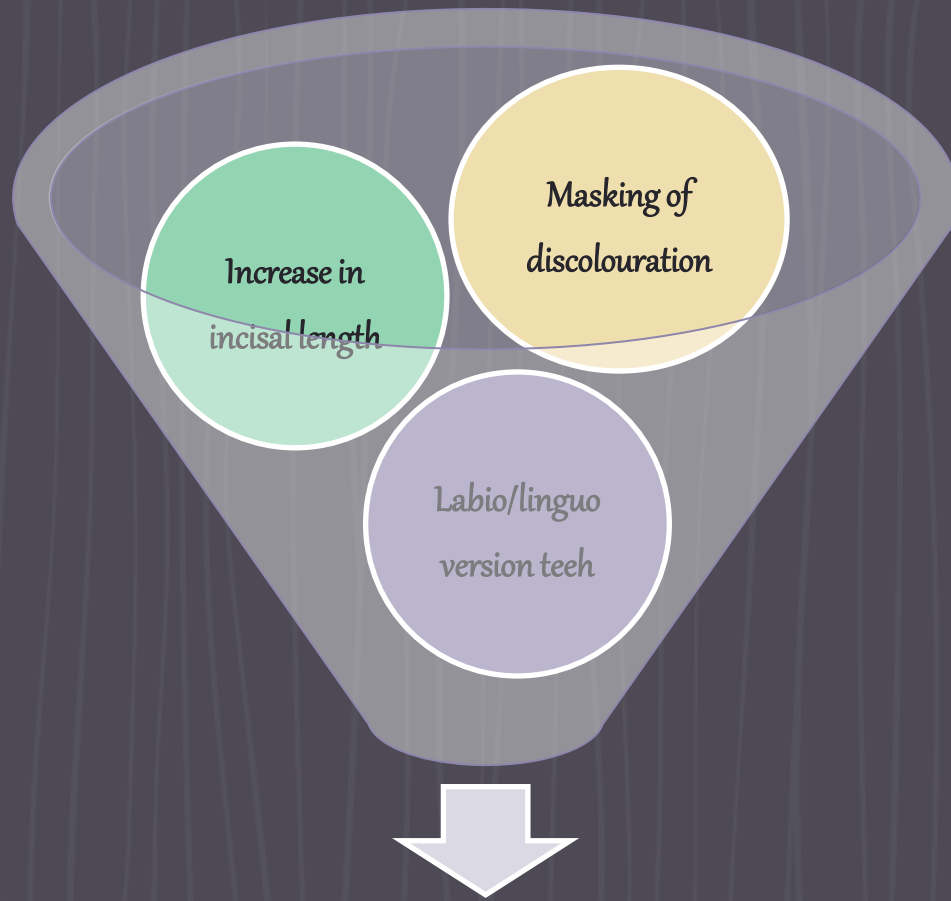
## Actual Material Preparation

A key element in success with porcelain veneers is *carefully controlled but appropriate tooth tissue reduction*

*The aim of the tooth preparation is to:*

- A Conservative 0.3-0.5mm intra-enamel preparation with the finish line as close to the gingiva as possible
- Adequate thickness to the porcelain to reproduce the natural light transmission (i.e. refraction, reflection, translucency)
- Provide a smooth preparation and with rounded internal line-angles to prevent areas with high stress concentration in the restoration

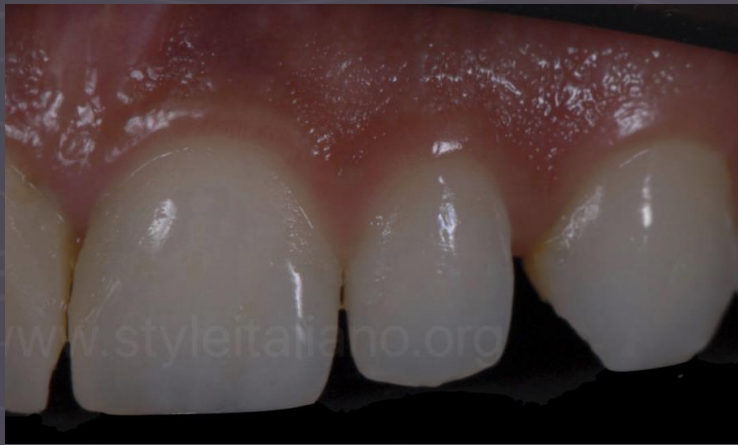- A **facial reduction of 0.5 mm with chamfered margins** & 1.0 mm of incisal reduction are preferable considering the conservative nature of PLV preparation
- However, no matter what the condition is, **cervical preparation is essential** to display the laminate's normal emergence and to prevent overcontouring
- If the **periphery of the preparation can be kept on intact enamel**, larger areas of dentin can be incorporated in the PLV restoration, such as is the case in traumatized or broken teeth



Factors affecting tooth preparation

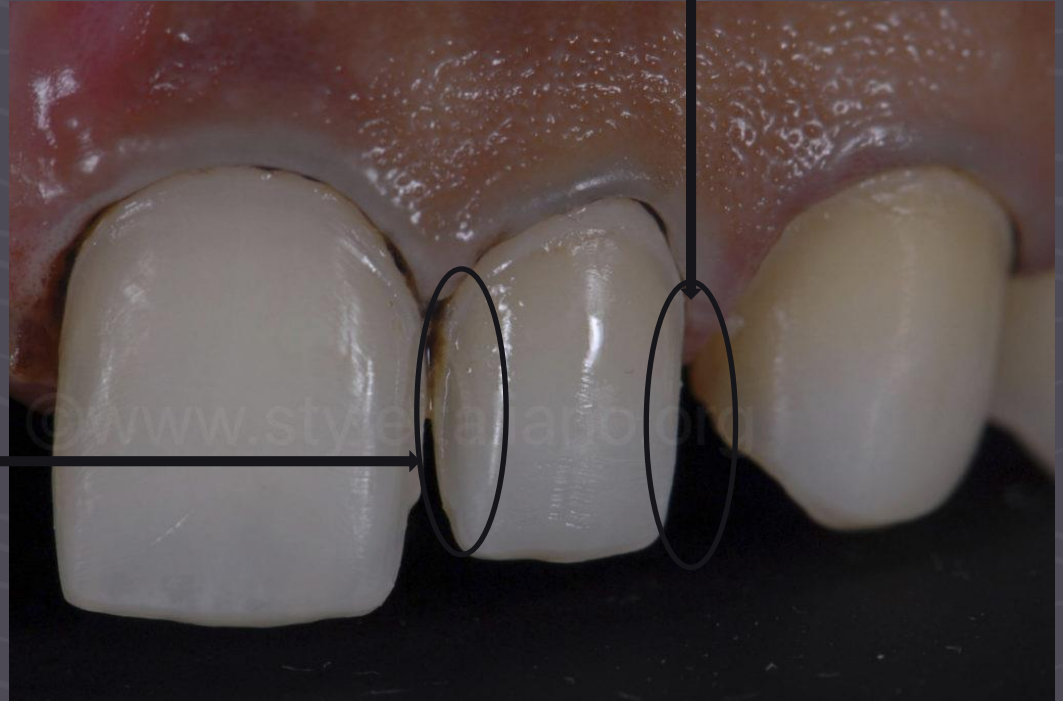
## *Labio/Lingual version of teeth*

- Most of the time, preparation of the lingually tilted tooth may be limited to creating a finish line on the proximal and the gingival regions and/or the removal of surface luster on the facial enamel
- Especially indicated to improve the appearance of Peg laterals
- Interproximal preparation should be extended as far as the facial aspect of the contact area to ensure that the margin between the veneer and the tooth is not visible



Where diastemas are to be closed, the proximal finish line was carried out as knife edge, all the way to the palatal side of the proximal wall.

Where no diastemas are to be closed, the finish lines should be carried 2/3rds into the inter proximal contact area

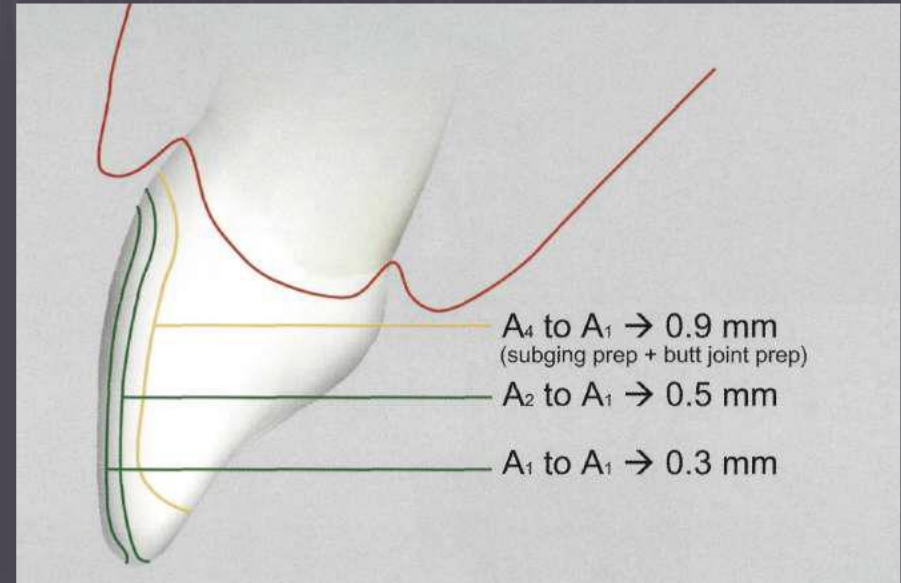


## *Increase in Incisal length*

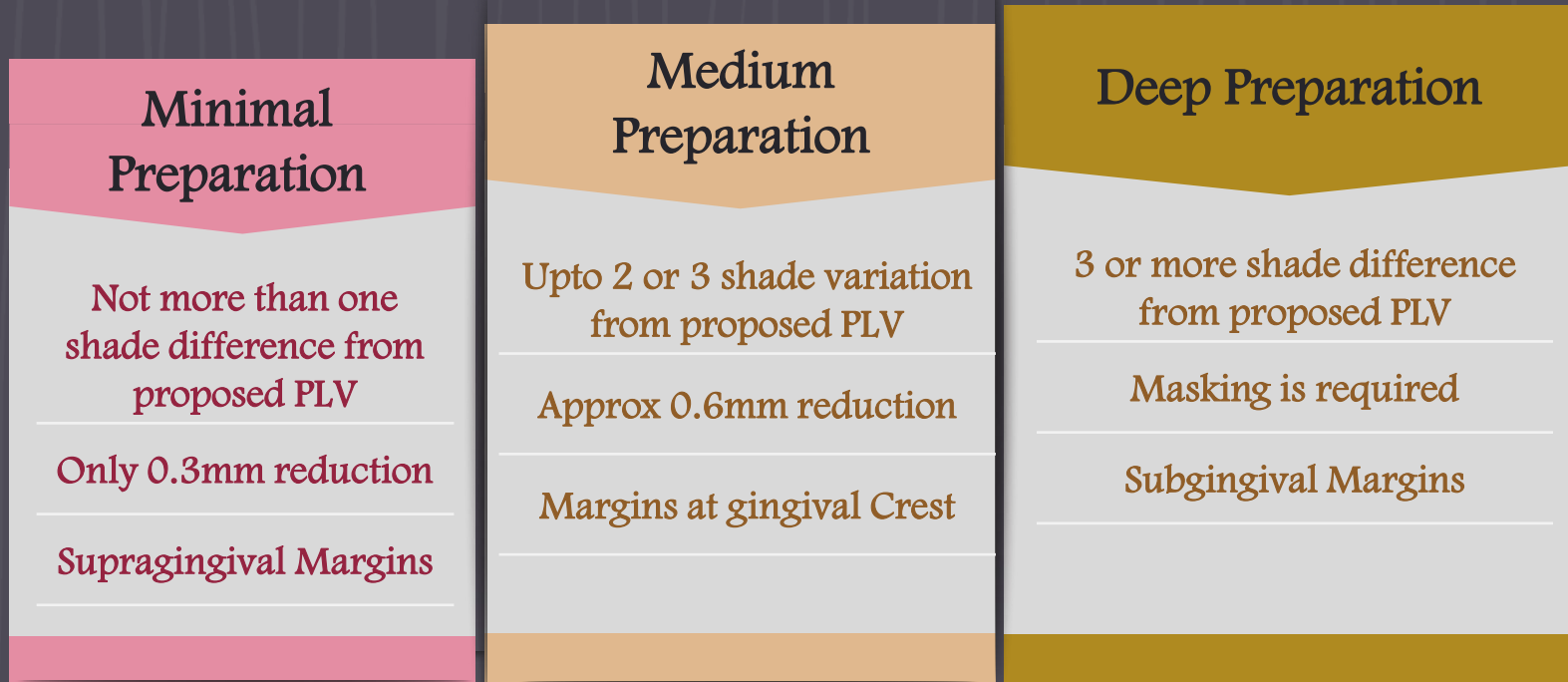
- *Careful evaluation of Occlusion especially the anterior guidance is indicated.*
- *If the anterior guidance needs to be altered with the help of the PLVs, then finishing lines should be extended palatally*
- *Facial-palatal thickness of the incisors should be taken into consideration*

## *Dynamics Of Color*

- ✓ A depth of **0.2 mm** is needed to **change the hue of the tooth by one shade**
- ✓ **Shallow, well-defined limits with chamfered finishing lines** are used to prepare teeth that do not need color alteration
- ✓ Slight discoloration must be approximately 0.3 mm in the cervical area and 0.5 mm at the middle third and incisal areas



To provide adequate depth for PLV to hide discoloration, Depending on the severity of the tooth discoloration:



Depths of Preparation

*When the tooth is dark and a shallow preparation must be done :*

- ✓ *A thin PLV lighter than the shade that it is expected, , the resulting shade can then be a combination of the existing tooth shade & lighter PLV*


*To create an A2 shade when the background is A3,5, the technician can use A1 shade in order to achieve the desired effect.*

## *Facial Reduction*

- The enamel thickness varies from the incisal edge to the **cervical margin (0.3-0.5 mm at the facial gingival 3rd, upto 0.6-1.0 mm at the middle 3rd & 1.0-2.1 mm at the incisal 3rd**
- Hence the preparation depth need to vary over the length of the tooth to avoid (if possible) exposing dentine
- Uniform removal of substrate can be achieved through the use of the bur, keeping it at three different angles.

## Depth Cutters

- They enable the dentist to guide, visualize and quantify enamel reduction



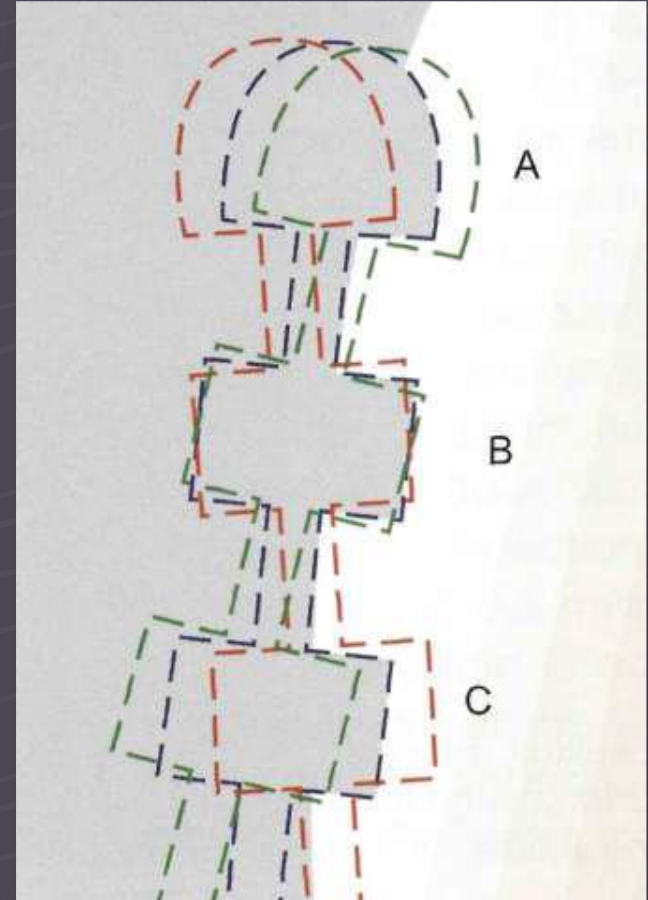
*Self-limiting depth cutter*  
cut to a depth limited to the  
radius of the wheel

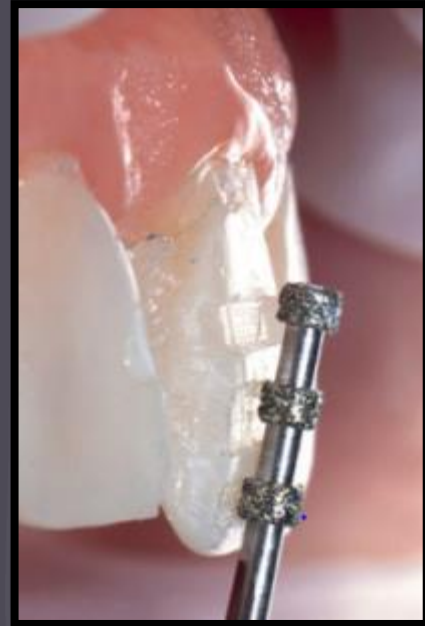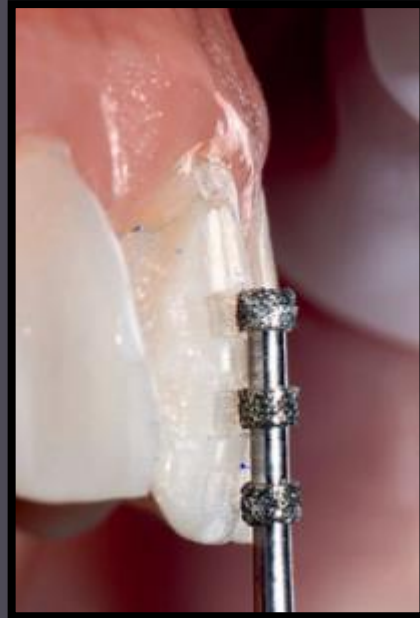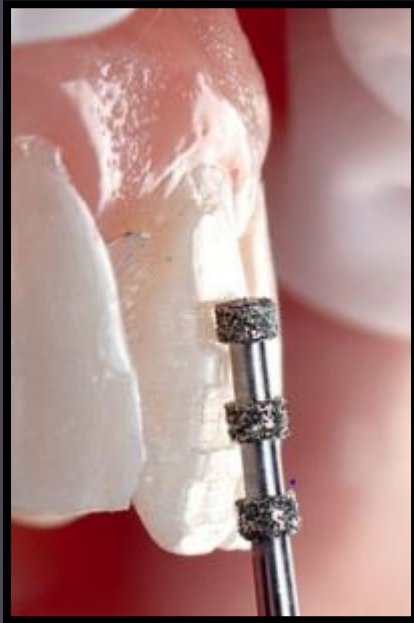*Different cutting depths within  
themselves*, relative to the  
enamel thicknesses of the facial  
surface of the incisors



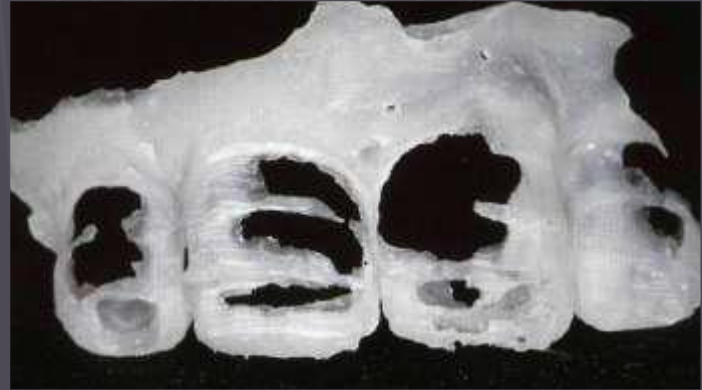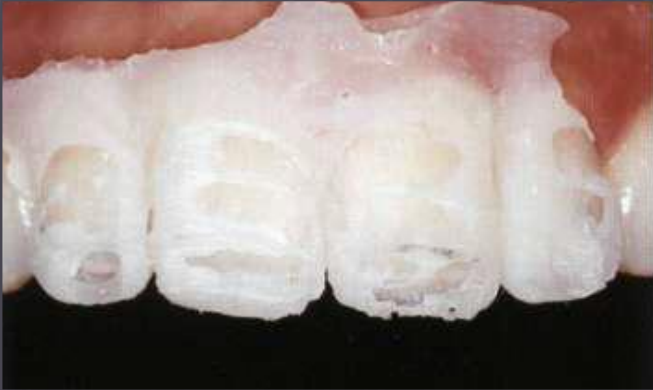- ✓ The most important thing here is to hold the depth cutter at three different angles so that all the diamond wheels will be able to reach the necessary depths

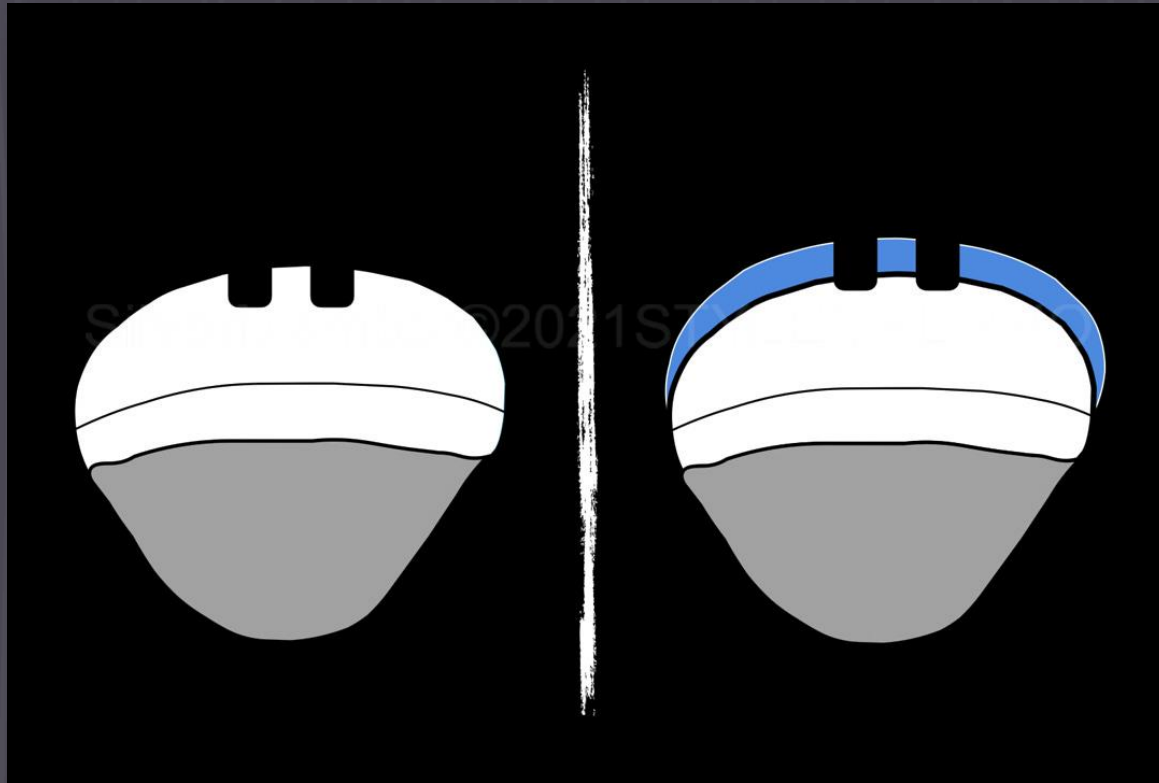
The surface after the depth cutter is used in only one angle. Note that the **only true depth is gained in the area of B (middle 1/3rd, black dots)**. To reach the necessary depth on **points A (gingival 1/3rd, green dots)** & **C (incisal 1/3rd, red dots)**



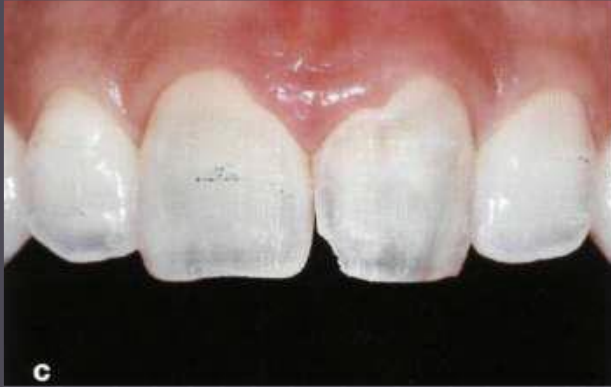

- ✓ *The depth cutters should be used through the APT. This will help in minimal invasive preparation*

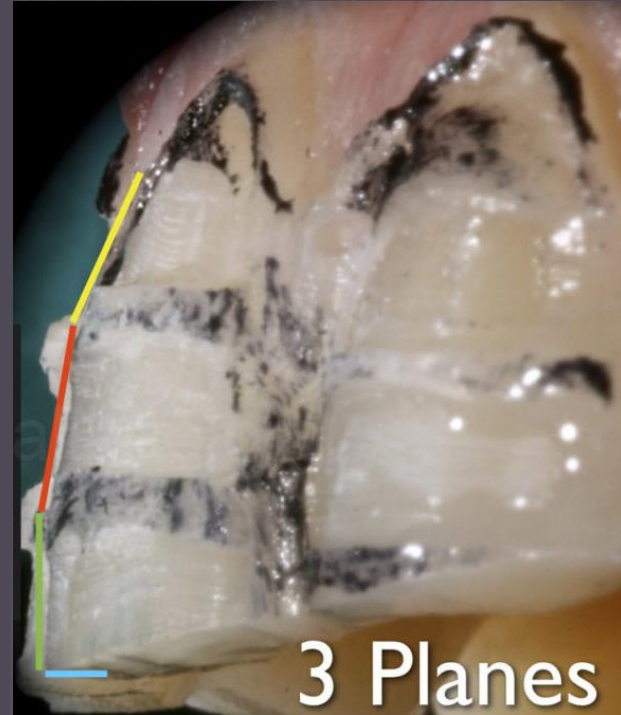




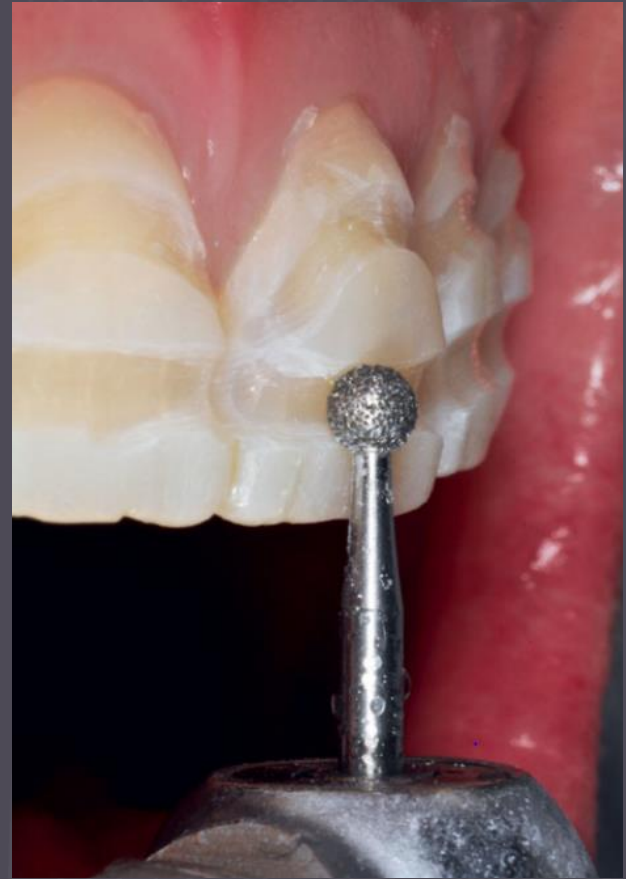*Appreciate the difference in the amount of tooth reduction  
without (left) and with (right) a mock-up*



The horizontal grooves produced through APT



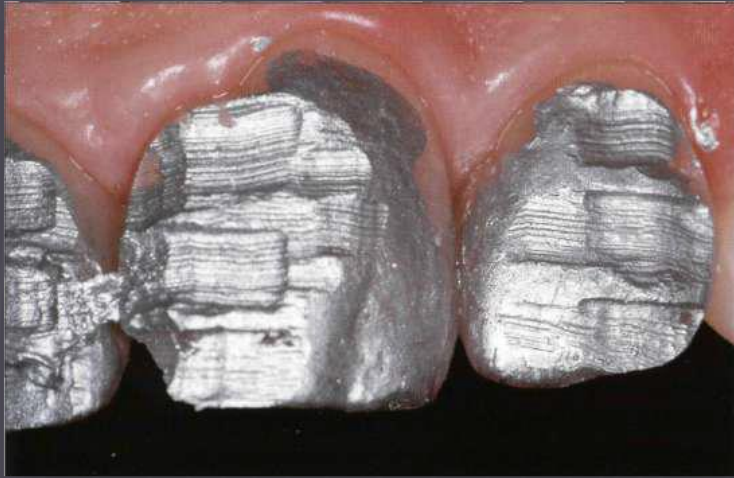- *Alternatively we can use depth pits prepared on the surface of the tooth using a 1 mm diameter round bur sunk to half its diameter*
- *The buccal surface reduction can then be undertaken to join the base of the pits*



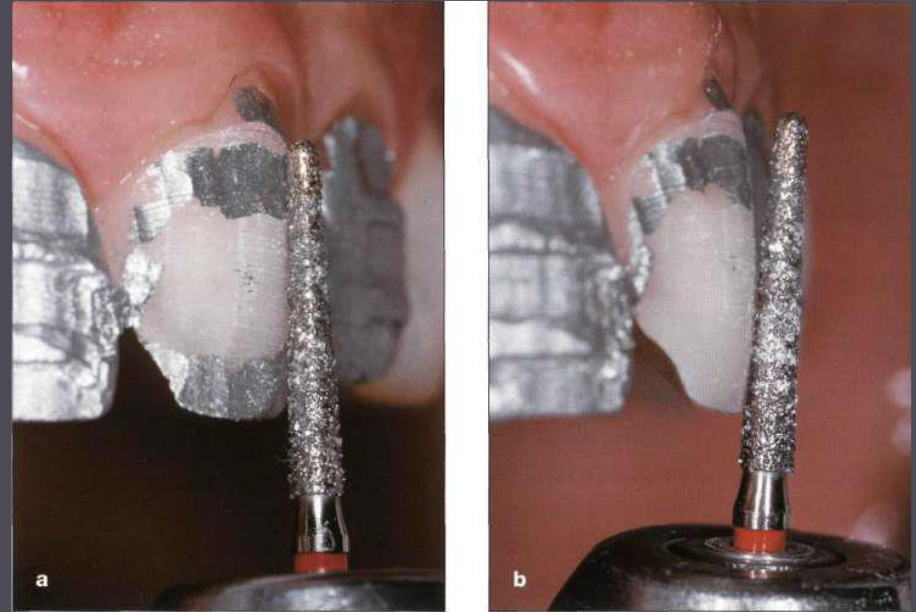
To further remove the remaining tooth structure found between the depth-orientation grooves, and to acquire the desired depths, a tapered rounded fissure diamond bur is used.

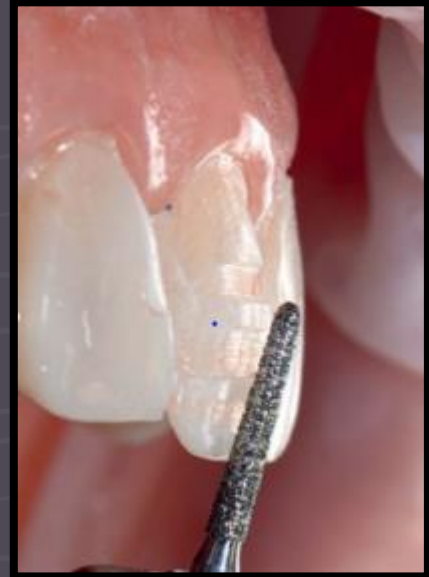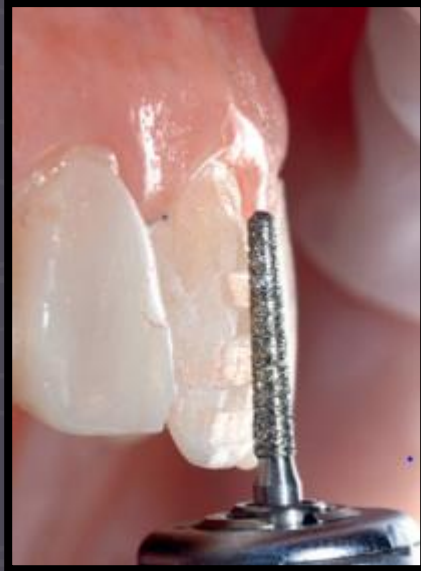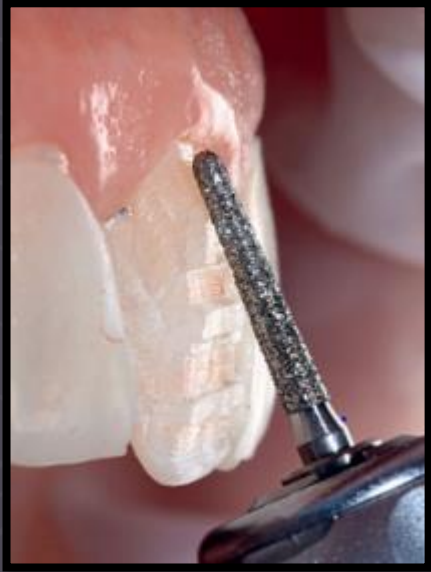The dentist should focus on the preparation design following some basic rules:

- **Respect buccal convexity**
- **Cervical margin located 0.5 supra gingival**
- **Proximal preparation margin at half the thickness of the contact area**



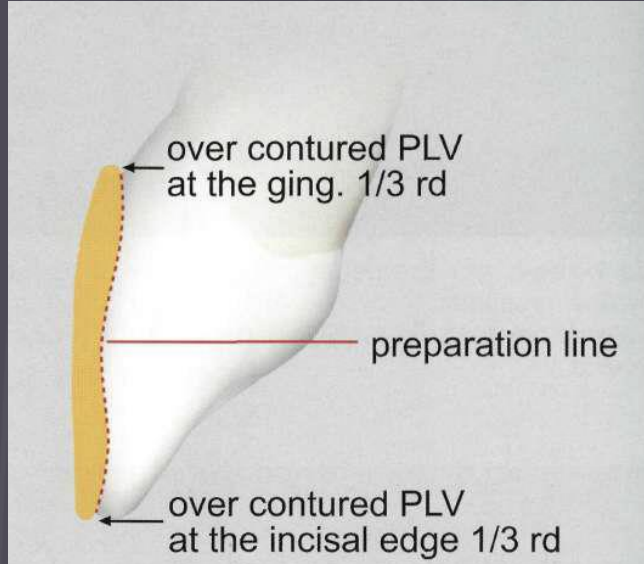
*The round ended fissure diamond bur is used in three different planes until all the color at the surfaces of the bottom of the grooves disappears. This will indicate that the true actual material preparation depth is fully achieved*



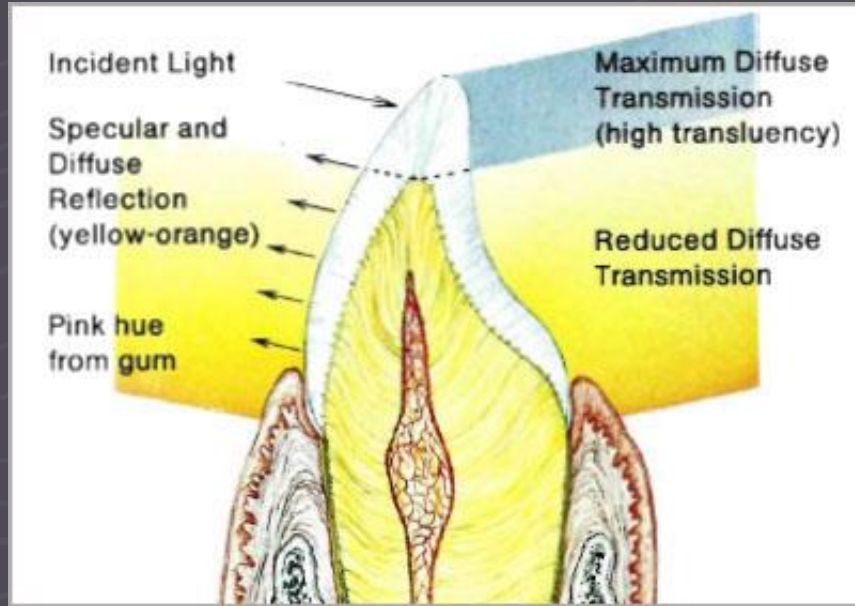


## *Preparing incisal 3rd*

- Provide a minimum reduction thickness of 0.7 at the junction of the middle and incisal thirds of the tooth

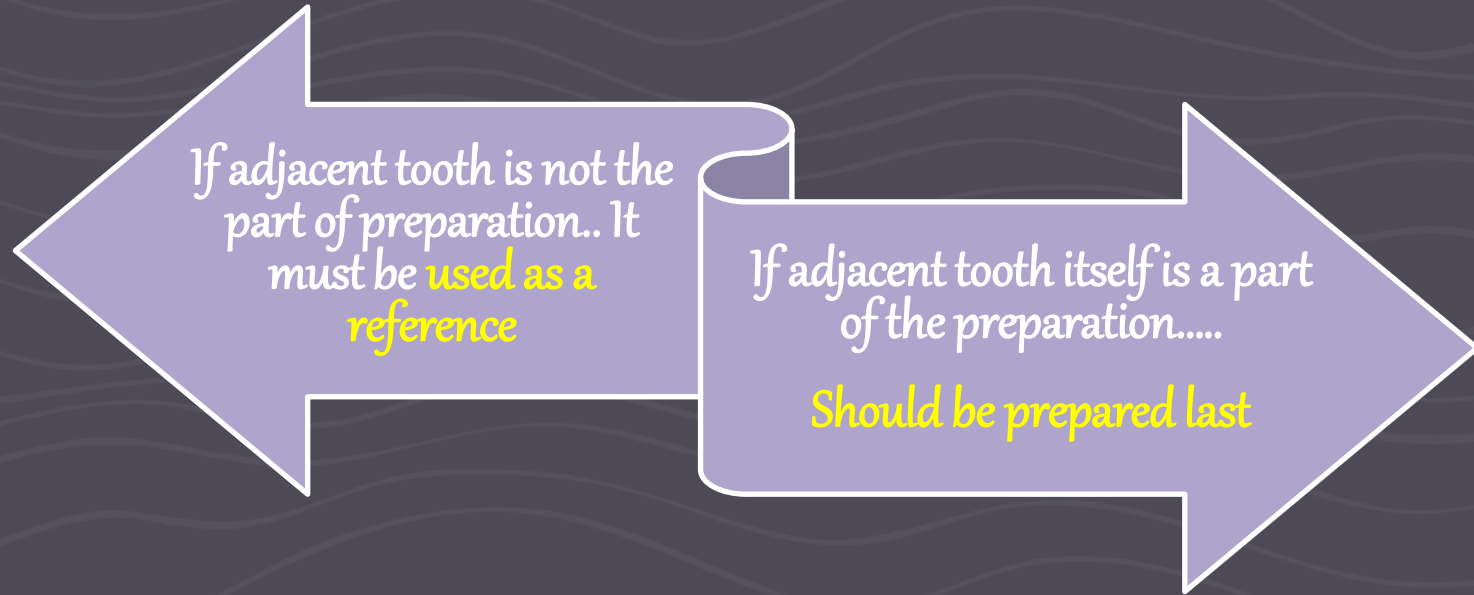


Leaving a sharp line angle not rounding off the incisal labial area, is the leading cause of over contouring of the incisal third of the restoration

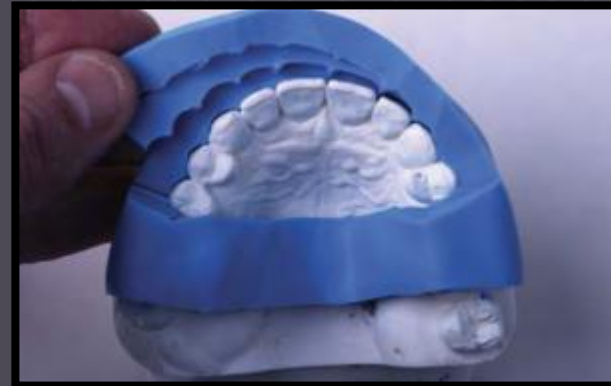
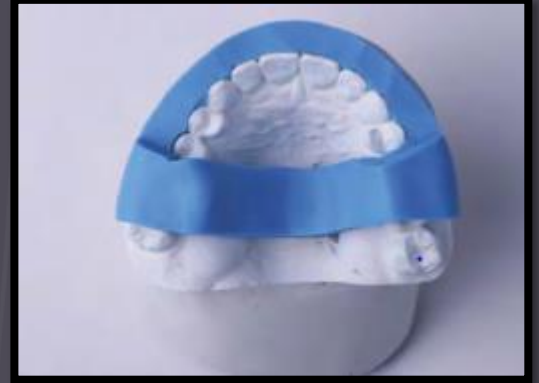
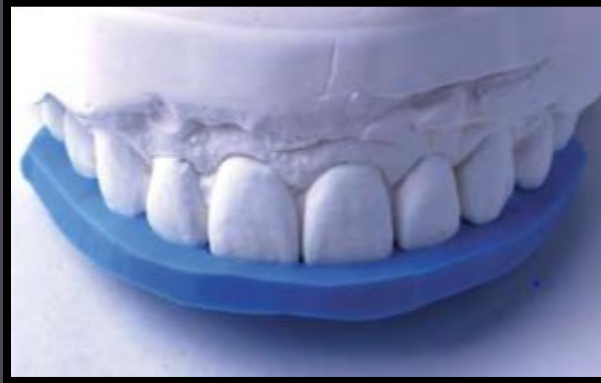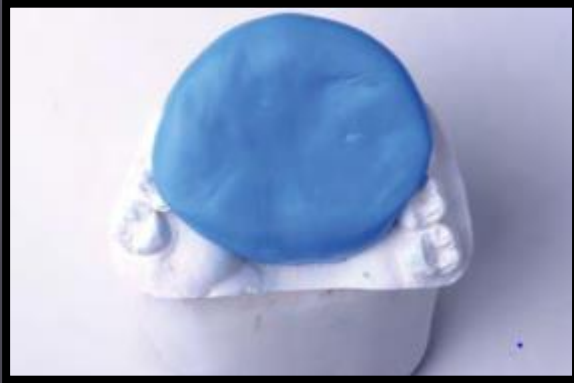*If the edge has a rounded surface at the incisal-labial, that reflected light is being diffused and yields an ideal transition of the shade from incisal color to body color*

A dentist needs a reference for the incisal edge preparation.

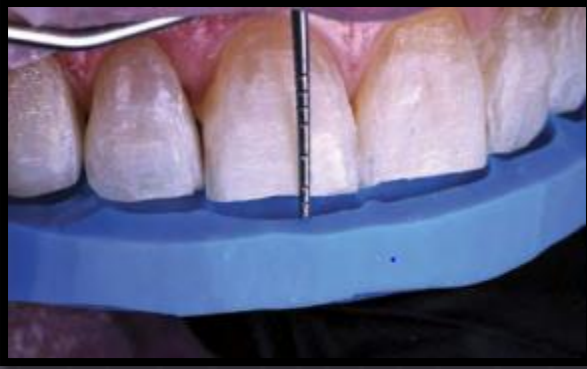

- ✓ Best way of estimating where the finished PLV margin will be is to use the APT in conjunction with the silicon index

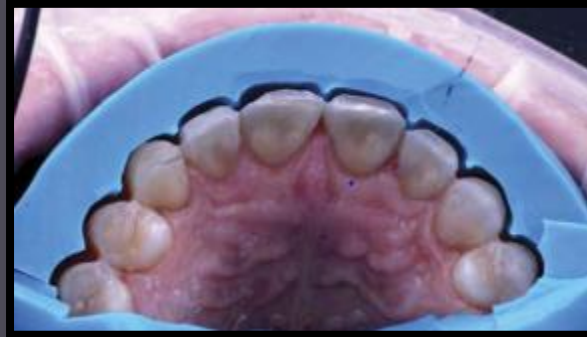

*Three horizontal slices and one vertical releasing incision on one side only*

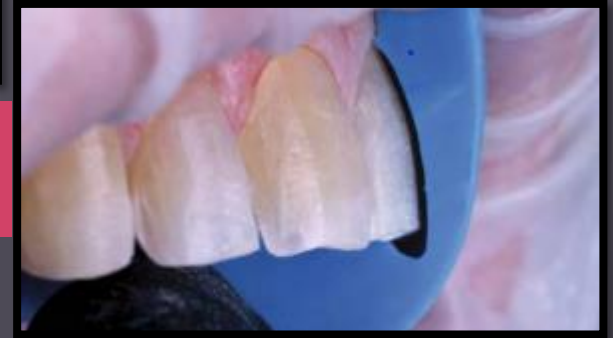*Occlusal view of the guide while peeling back three different planes of facial reuction*



*Incisal edge reduction guide check  
using periodontal probe*



*Facial reduction guide displaying  
appropriate reduction*



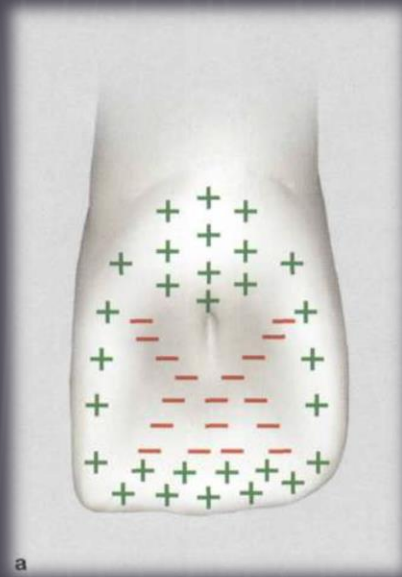
*Facial and lingual reduction check*

## *Palatal Preparation*

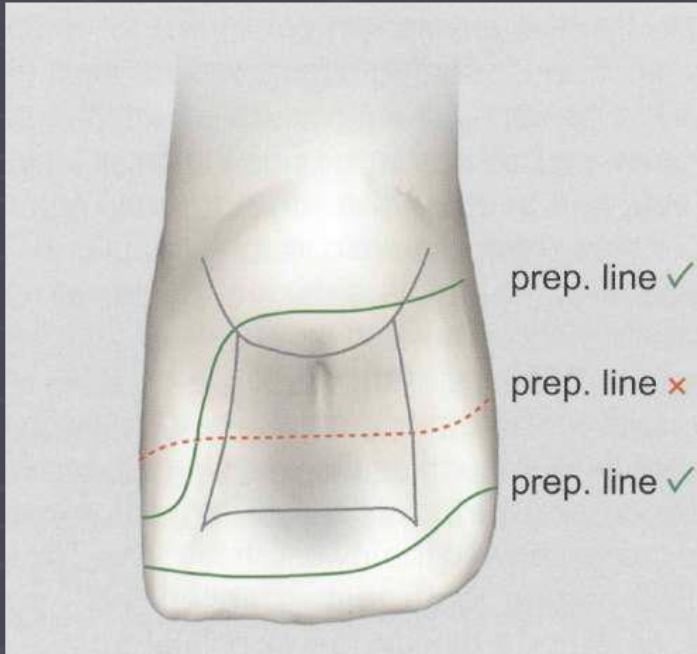
Concavities (that provides the incisor with its sharp incisal edge and cutting ability)

**“AN AREA OF STRESS CONCENTRATION**

With elevated tensile stresses during functional loading”



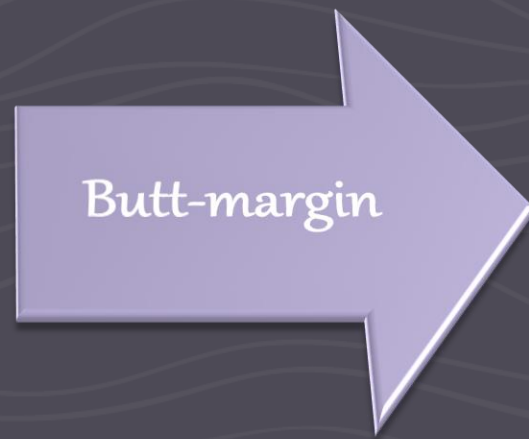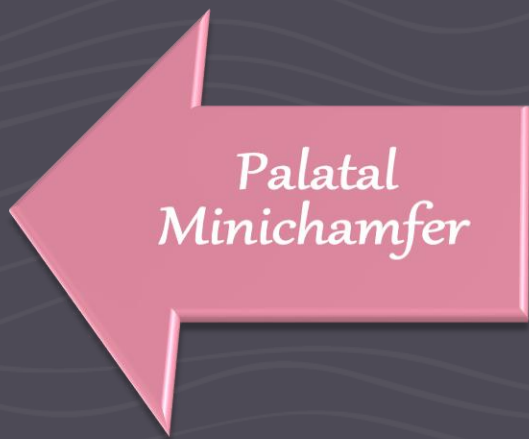Convexities with local enamel bulk such as the cingulum, the marginal ridges  
**SHOWS LOWEST STRESS LEVELS**



- ✓ The preparation should preferably :
- Not finish at the concavity
- Either above the concavity or below on the smooth convex area of the cingulum

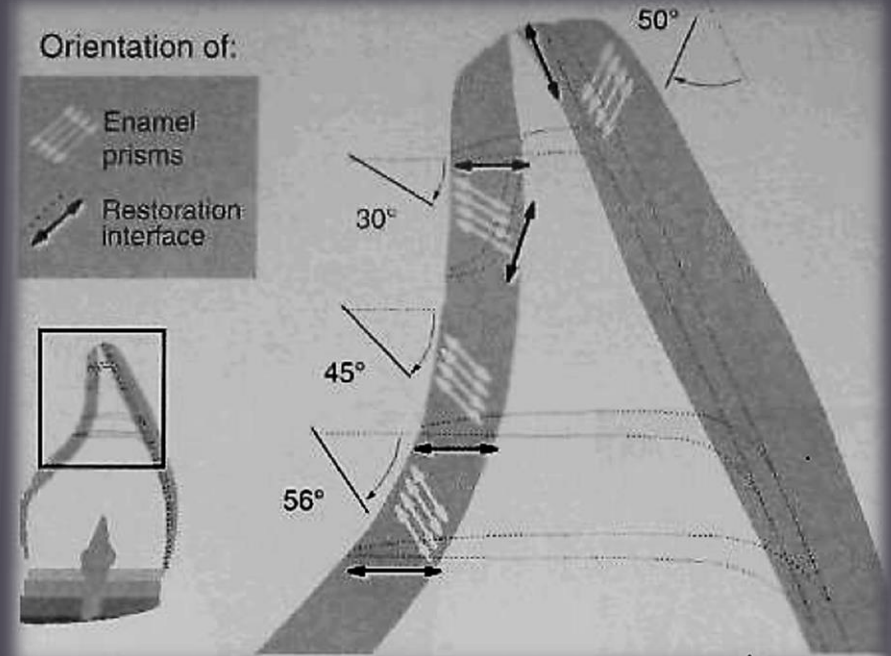
*So that they will be subject to low tensile forces*

*The finish line on the lingual aspect should not end on a wear facet and/or on the central contact points*

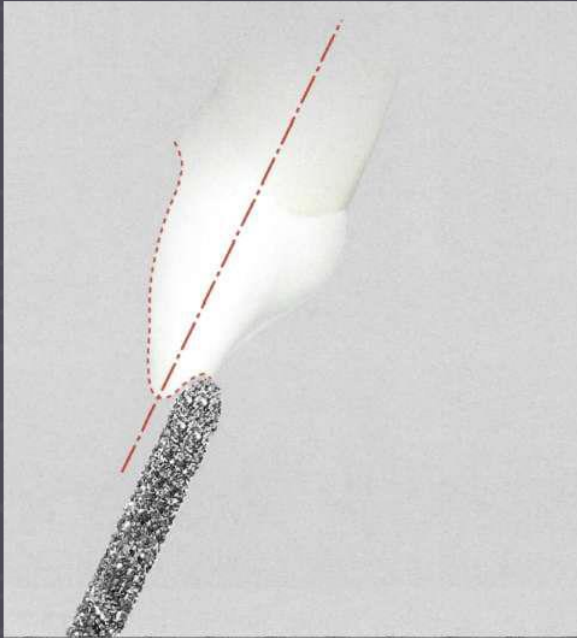


*Incisal third - A minichamfer recommended because it will section enamel rods at an angle close to 90 degrees*

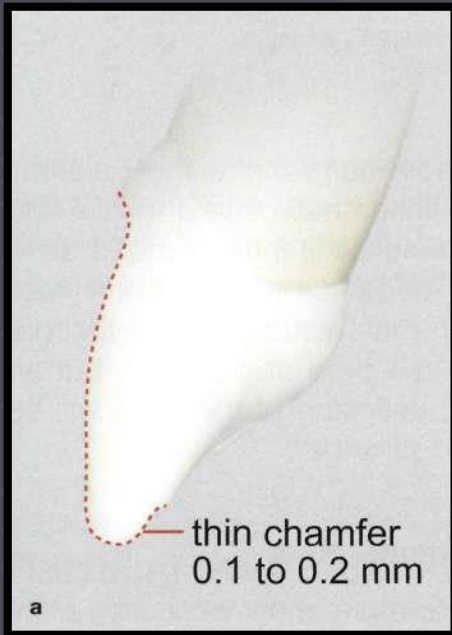
*Middle third (Fractured tooth)  
Horizontal Butt Margin - section the enamel prisms obliquely at an angle greater than 50 degrees.*



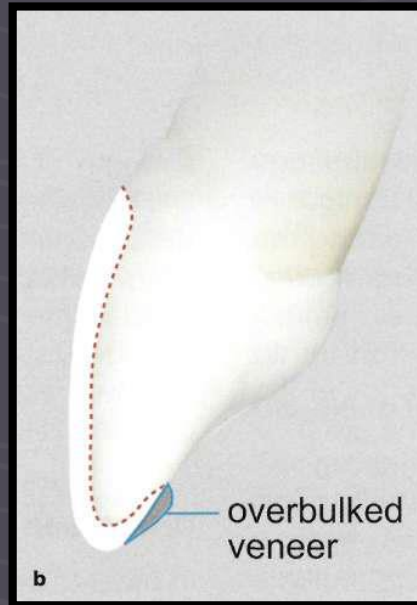
- ✓ The finish line should preferably be about **one-fourth the way down the lingual surface** about **1.0mm from the centric contacts** while connecting two proximal finish lines



Round-end tapered diamond bur held parallel to the lingual surface to create a chamfer of 0.5mm depth




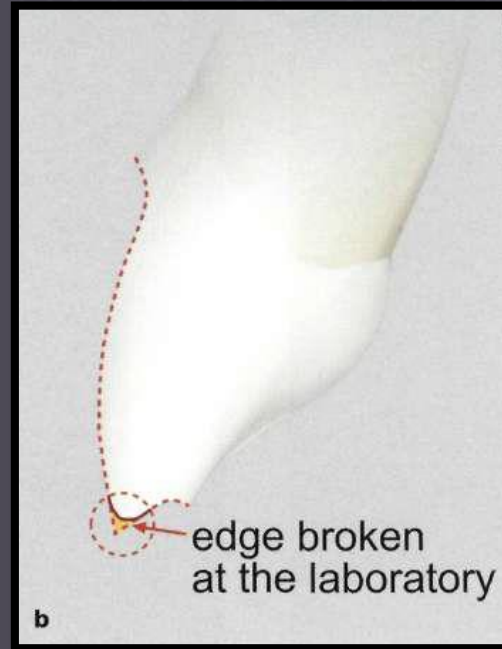
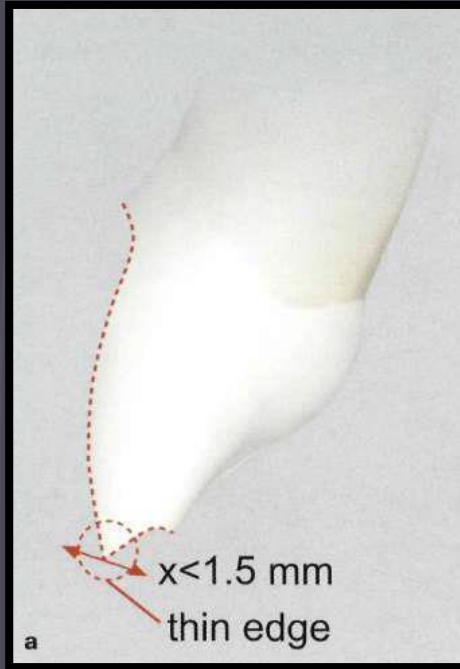
- Porcelain veneer requires a minimum thickness of 0.5mm so the end result will be a joint with a ledge of porcelain beyond the normal contour of the tooth



- Patient will experience a uncomfortable feeling at tongue

## Incisal notch

Placement of the lingual finish line for a laminate veneer will also depend on the thickness of the tooth and the patient's occlusion



## *Gingival Preparation*

- ✓ *Smooth margins that are fully exposed and readily cleansable generally provide the best results.*
  - *Kept clean by the patient*
  - *Properly finished by the dentist*
  - *Can be duplicated by the impression,*
  - *Removed without tearing*

*Chameleon effect of the PLV on the cervical margin enables the dentist to place the gingival margins of the PLV supra-gingivally as the porcelain blends in with the underlying composite resin in a harmonious finish*

“

▷ *HOW TO SELECT MARGIN???*

Tooth  
Discoloration

Nature of lip-  
line

The teeth are **free from discoloration** or presenting "Discrete color alteration", the **gingival margin must not be placed in the gingival sulcus.**

- **Supra or equi-gingival** placement is preferred for a **Low Lip-line**
- If there is **gingival exposure while smiling**, **Subgingival placement** may be necessary

## *Supra-gingival*

- Non-esthetic areas
- Patients with low smile line

Eliminates chances of injury to gingival tissue

Risks of undue exposure of dentin in cervical region

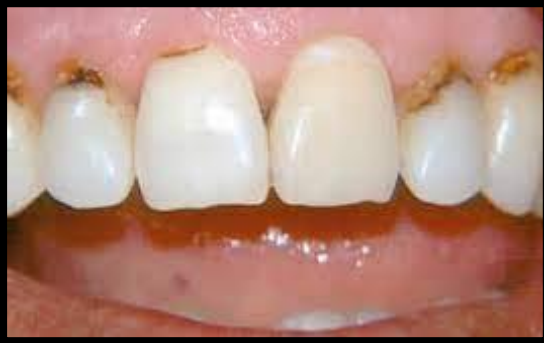Easy impression taking

Microleakage is minimal or none

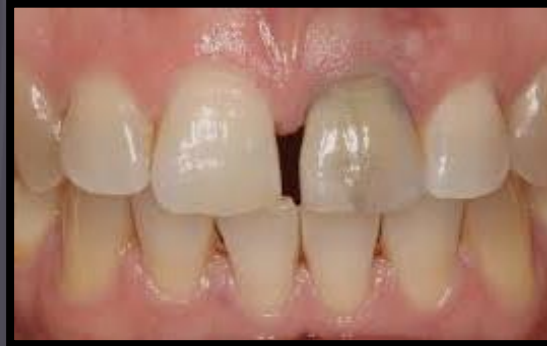Post operatively eliminates impingement of biological width

## *Subgingival*

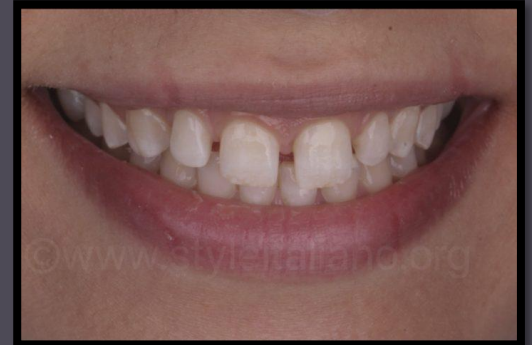Subgingival margins are unavoidable, such as in



Caries or old fillings that extend under the gingiva



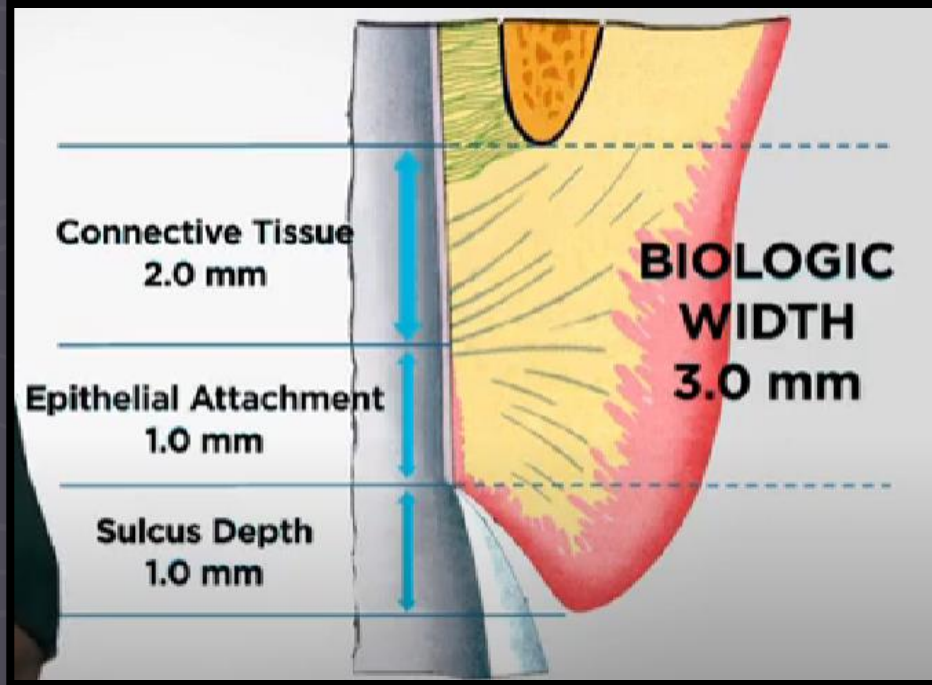
Masking the discoloration



High lip line

- ✓ *Allows the technician to preserve the existing height of the papilla as well as to make certain that all interproximal spaces and/or diastemas will be closed while permitting control over the emergence profiles.*

*Risk of violating the biological width  
Difficulty of visually following the cervical margins*



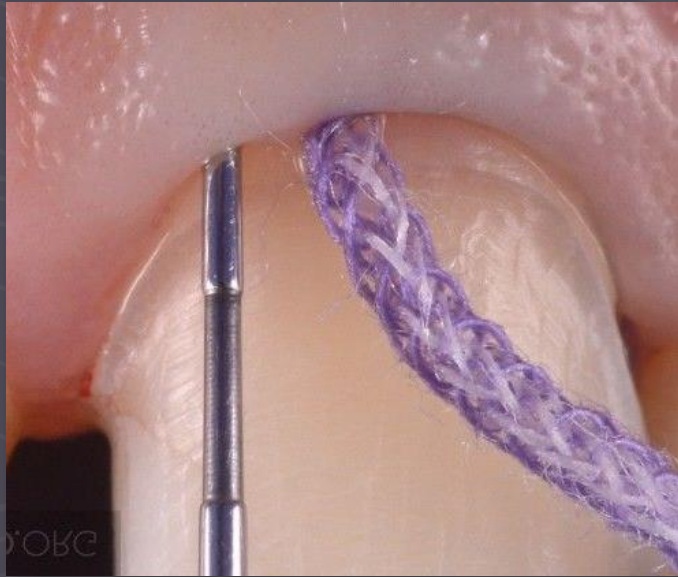
Probing Depth

Depth of margin  
of restoration

<1.5mm → 0.5-0.7mm below gingiva

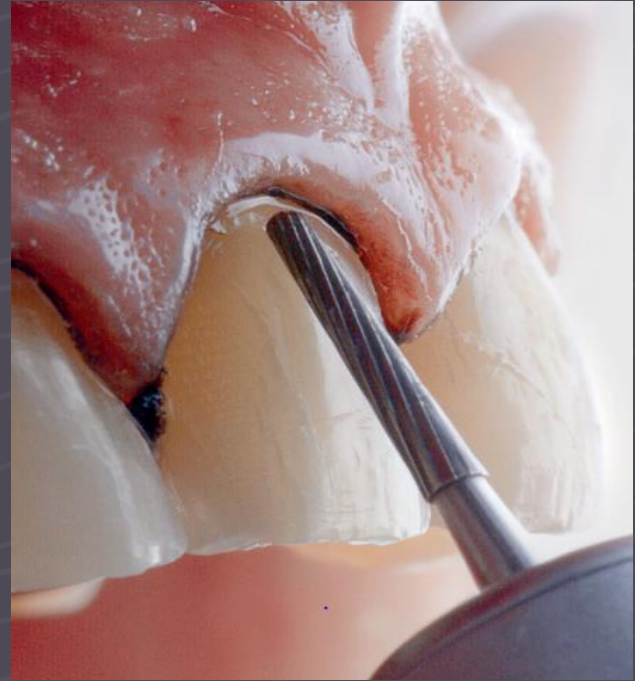
>1.5mm → Half the depth of sulcus

- ✓ Some leeway preventing encroaching of the epithelial attachment of the biologic width



To create a *buffer zone* between the epithelial attachment & the bur

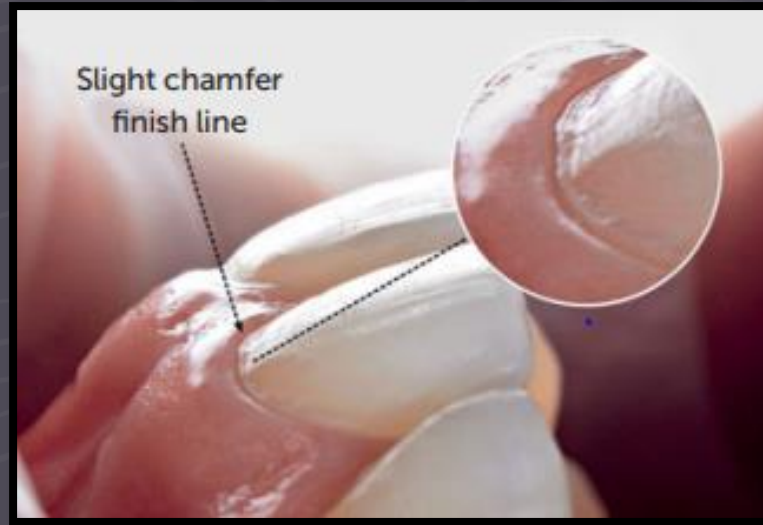Place the first cord that retracts half of the sulcus. This cord makes a **VERTICAL RETRACTION**



“

▷ *Chamfer or shoulder??*

- ✓ *A chamfer is preferred for all the gingival margins preserves more natural tooth*

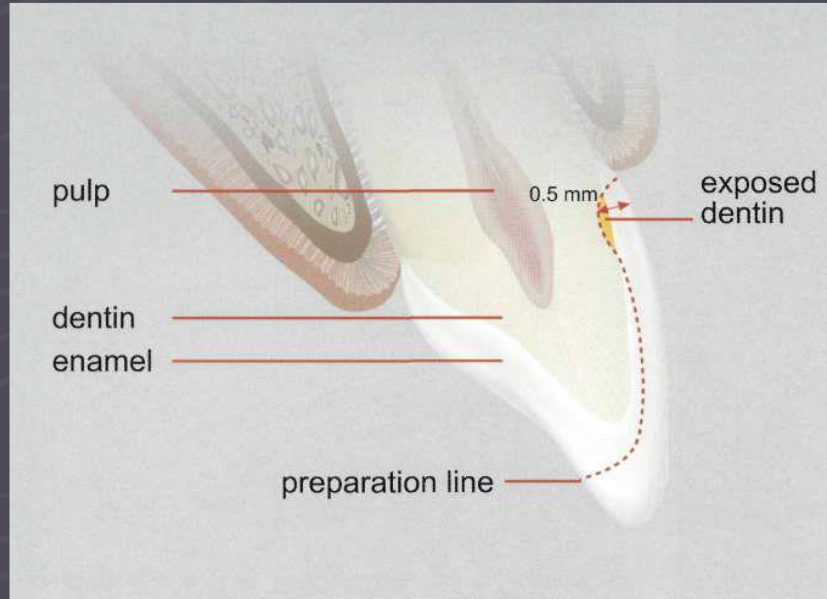


- *Gradual color transition between restoration and tooth substrate, thereby avoiding the sudden delineation between tooth and crown*

- *Easy to record, identify and reproduce in the laboratory*
- *Ideal continuation of the emergence profile, without any ledge at the junction of the veneer and enamel*
- *Easier insertion of veneer during try-in & final cementation*
- *Provides a higher fracture resistance & avoidance of fractures at the edges of the PLV*

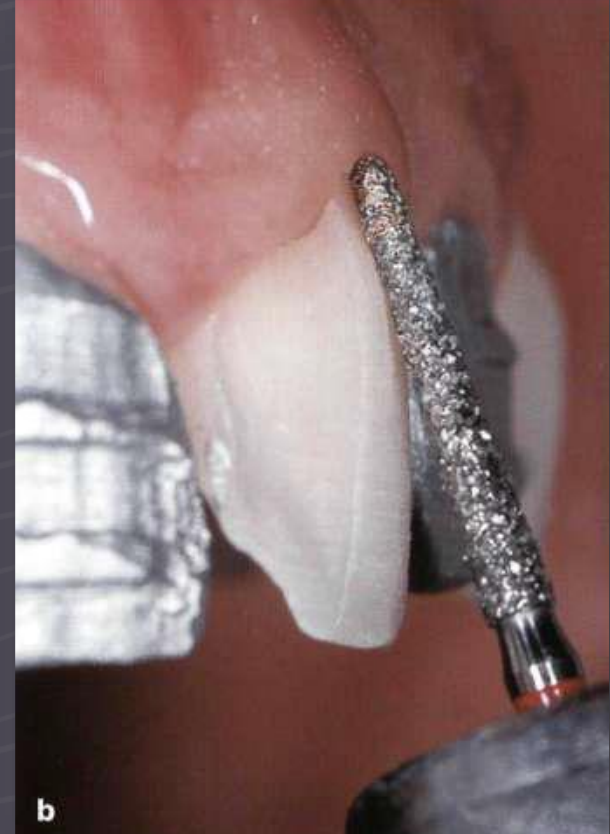## Depth of preparation

- ✓ Ideally should not exceed the depth of 0.3 mm labio-lingually, which is the minimum recommended thickness for the PLV during fabrication.



## Technique

- *The round end of the fissure diamond bur is held almost parallel to the inclination of the cervical 1/3rd of the labial preparation surface*
- *Moved from the apical end of the distal proximal surface towards the apical end of the mesial interproximal surface, delicately following the gingival contour.*



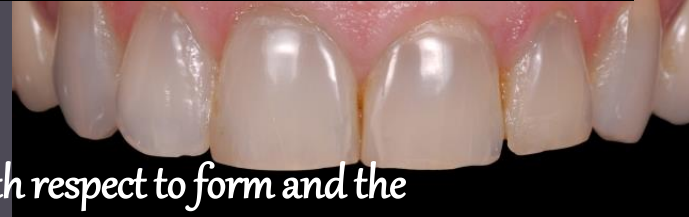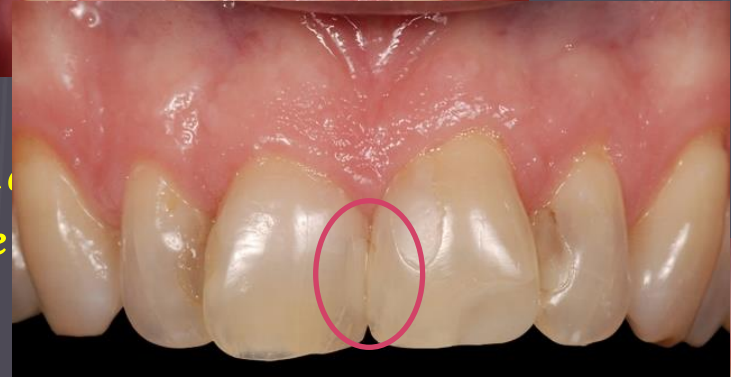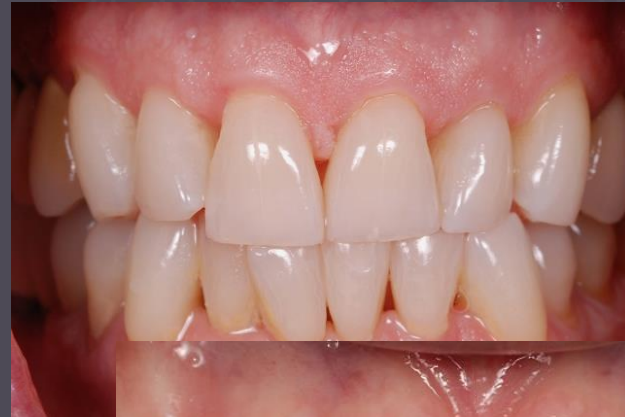## *Proximal Preparation*

- ✓ Place the margins beyond the visible area
- ✓ Preserve the contact area

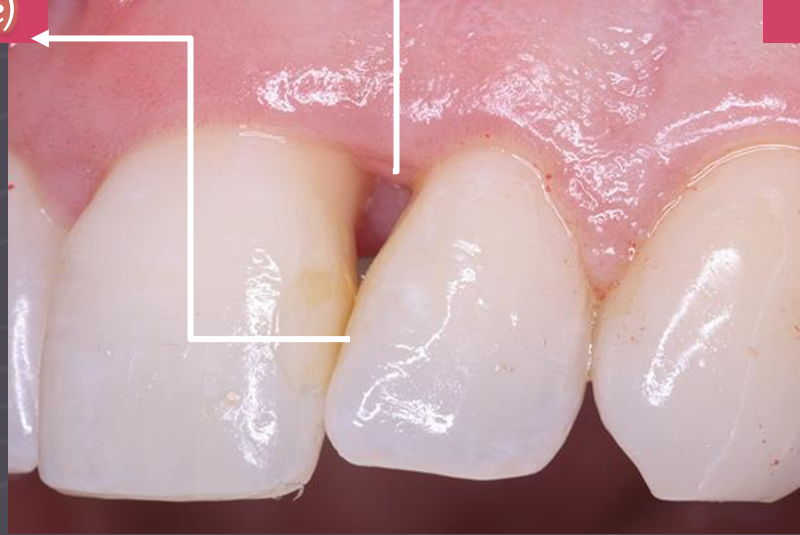The margin can be drawn back *even more in the lingual*

- If the natural contact area has already been lost due
- Restoring a broken angle
- To encompass a proximal composite
- If a significant color change is desired

Allows the dental ceramist the maximum level of creativity with respect to form and the emergence profile of the future restoration



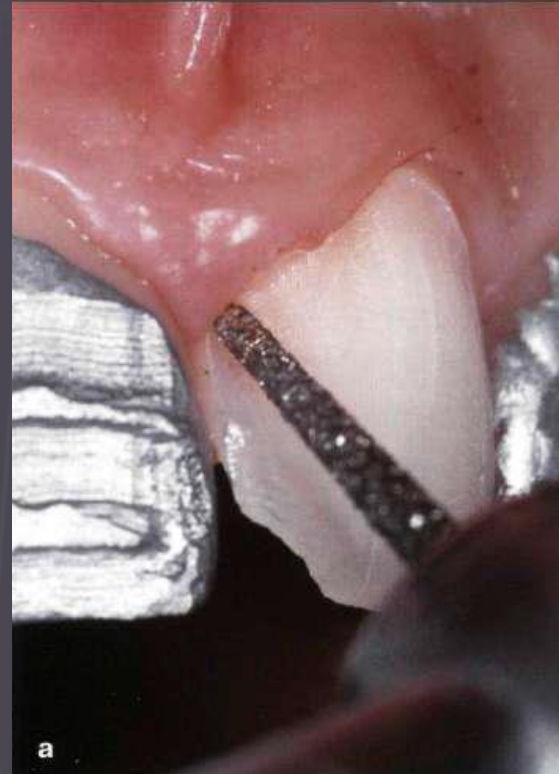Proximal Contact Area  
(Incisal 2/3<sup>rd</sup> of proximal surface)

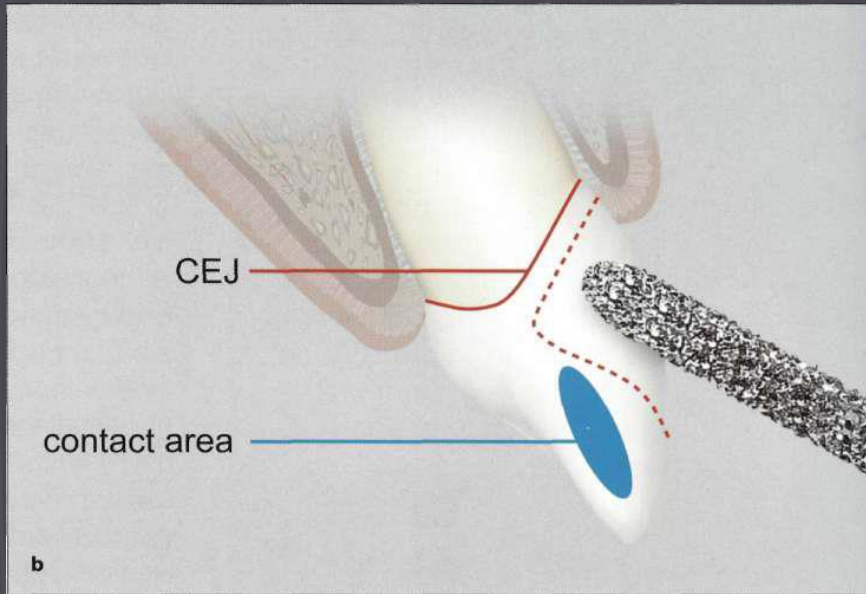


Gingivo-proximal Area/  
Gingival Embrasure

## Gingivo-Proximal Preparation

- Round-end tapered fissure diamond is held at an almost 60-degree angle, and follows the gingival prep towards the palatal, from both the mesial and then the distal.
- Usually kept supragingival





When viewed from the mesiofacial aspect, a **concavity is created** in the shape of **an interproximal elbow or dogleg form**

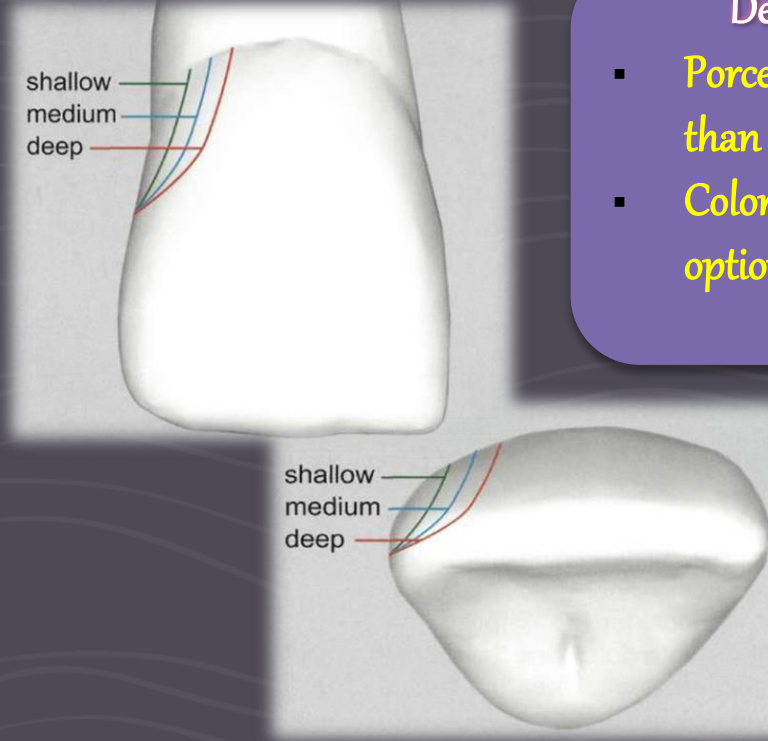
- ✓ In the cervical and proximal areas, **the creation of a light chamfer without internal line angles is universally accepted.**

## Depth of chamfer margin

### Light Chamfer

- Improved color control
- Preservation of enamel  
So prevents microleakage
- Thin porcelain margin  
making it vulnerable

Affect the thickness of the porcelain in that area

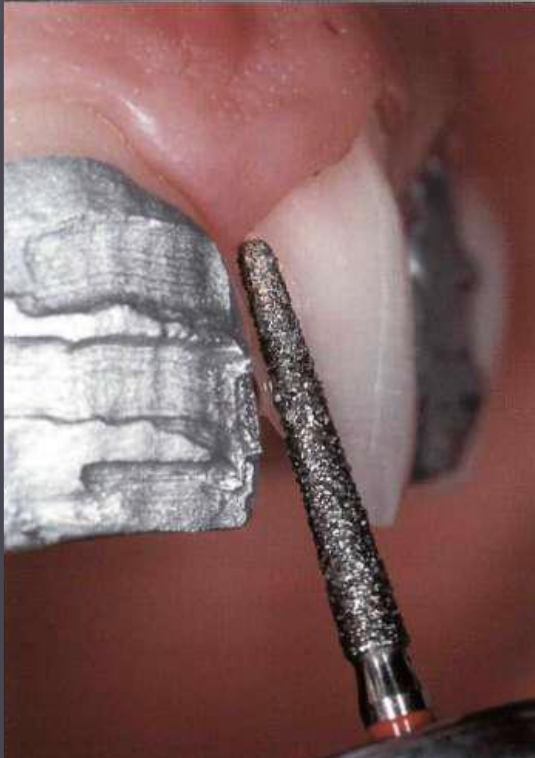

### Deep Chamfer

- Porcelain will be thicker  
than it should be
- Color-adjustment  
options will be limited

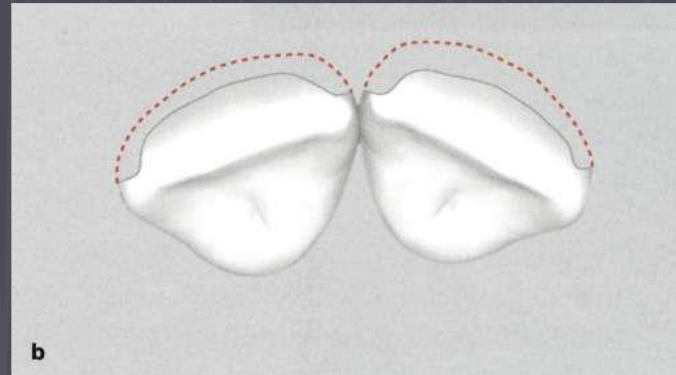
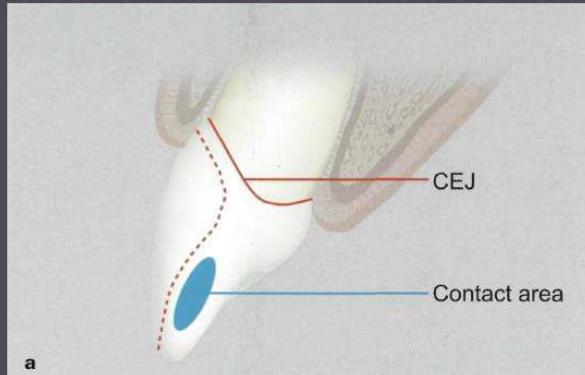
Medium Chamfer allows color adjustments and yet has a porcelain margin of adequate thickness

## Inter-Proximal Preparation



- The fissure diamond bur is **uprighted vertically** into the proximal area, making sure to **maintain adequate reduction, especially at the line angle**
- Diamond is parallel with the long axis of the tooth and parallel to the mid-line

Under normal circumstances this preparation should stop just short of breaking the contact

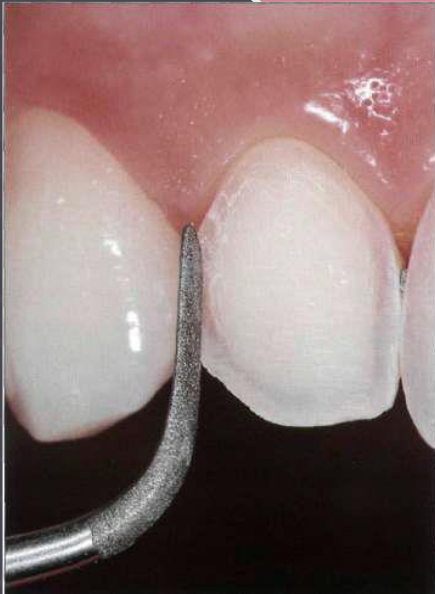

In some instances, Only 1 or two teeth are to be prepared, **additional care has to be taken not to scratch the adjacent intact tooth.**

## SHOW RESPECT FOR THE NEIGHBOURS!!

Place a metal matrix  
band in between

Oscillating Instruments



Oscillating working tips that are diamond-coated allow very precise apposition of the instrument to be worked on, while the uncoated side can be exposed to the adjacent tooth surface without damaging it.



**INSTRUMENT  
SONIQUES**

**KAVO  
(Sonicflex®)**

N° **SF979.000.014**

(gros grains)

N° **SF8979.000.014**

(grains fins)

N° **SF979.000.016**

(gros grains)

N° **SF8979.000.016**

(grains fins)

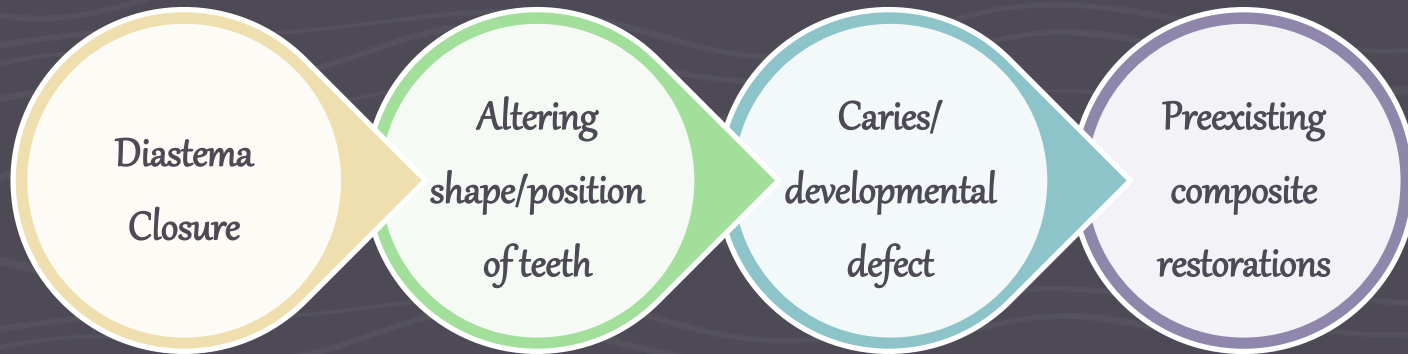


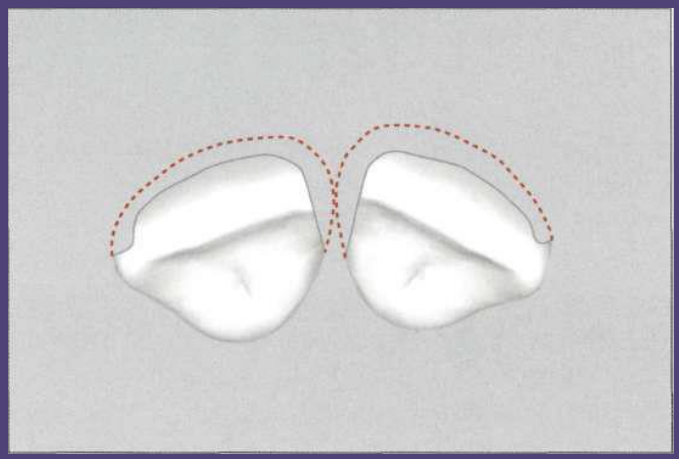
“

▷ *WHETHER TO BREAK THE  
CONTACT OR NOT?*

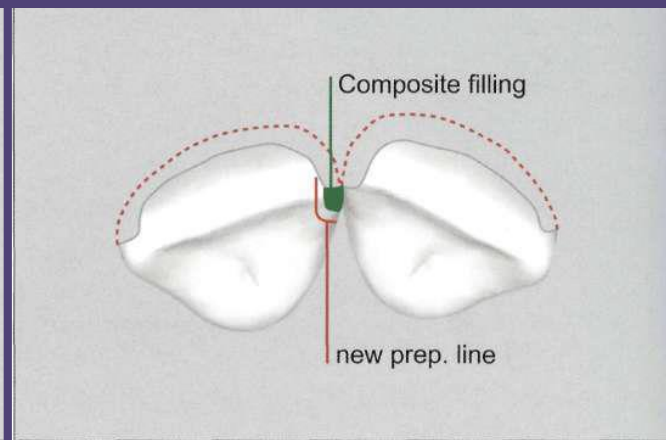
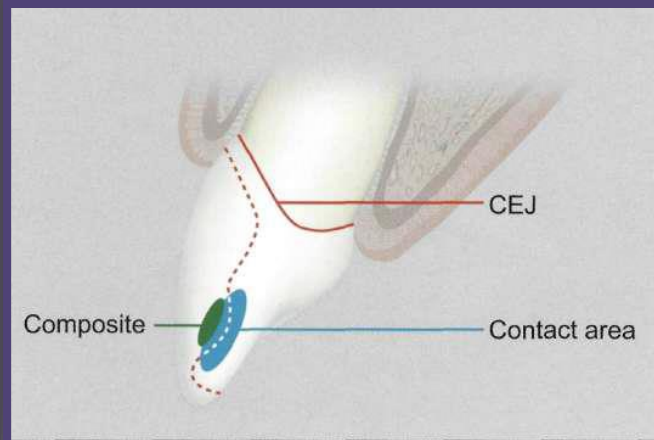
- ✓ Whenever possible, it is best to preserve the contact area, as it is an anatomical feature that is difficult to reproduce

However certain clinical situations necessitates breaking the contact :

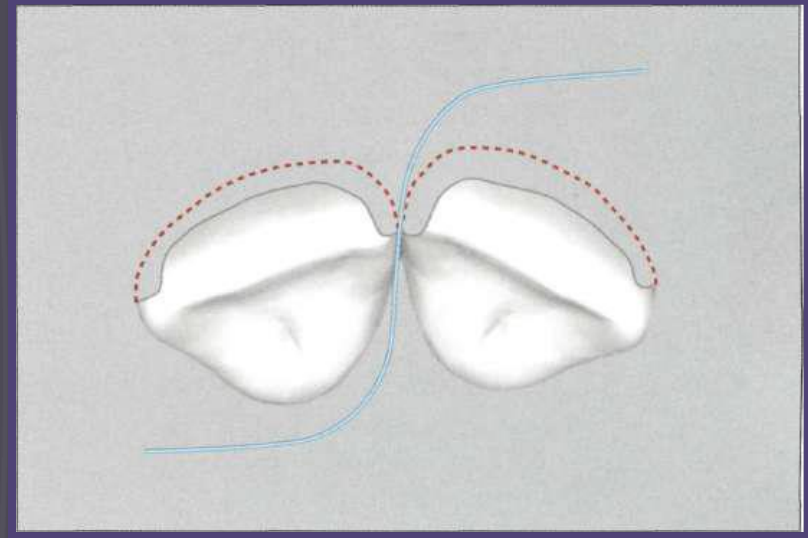
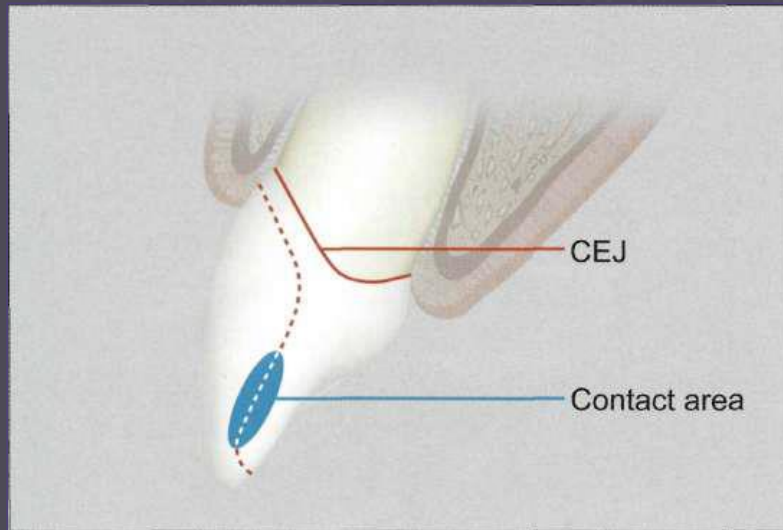




Contact area has to be sliced fully from buccally to palatally



However, if for some reason the preparation must finish on the proximal contact area instead of extending the preparation more palatally, which will cause the loss of intact enamel in the contact area, it can be stripped to achieve a clear interproximal margin.



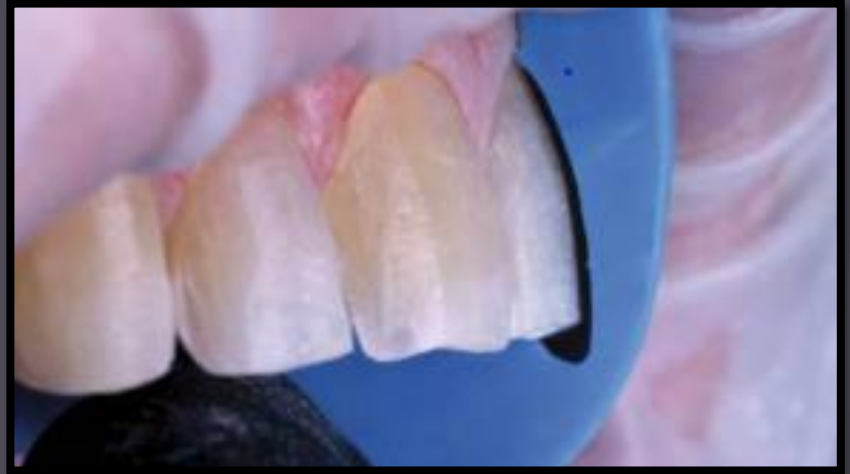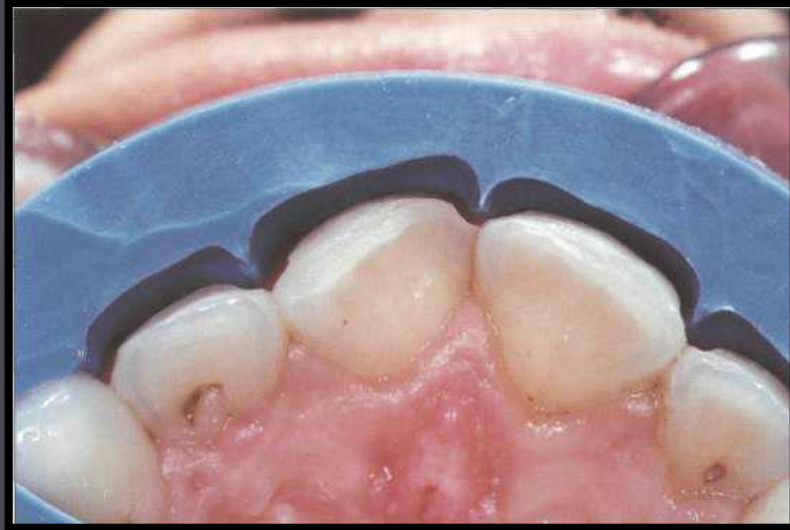*A diamond strip should be used to create a definite, crisp marginal edge*



# *Finishing The Preparation*

- *Any sharp lines angles formed at the junction of facial, proximal and lingual planes of the final preparation should be rounded off.*
- *Check for the gingival embrasures if they are carved to create a healthy gingival papilla.*
- *With the help of magnification, check for any scratches on underprepared areas.*

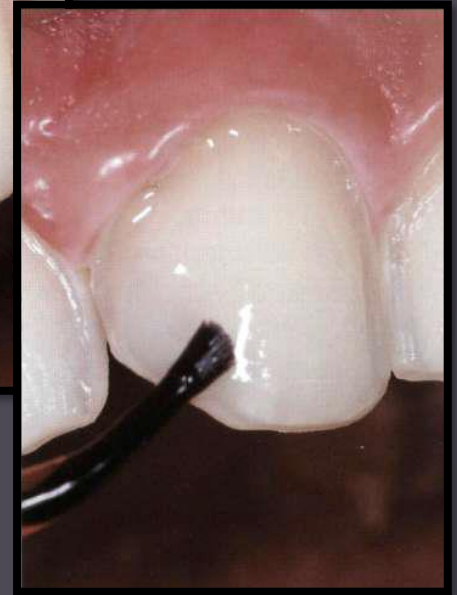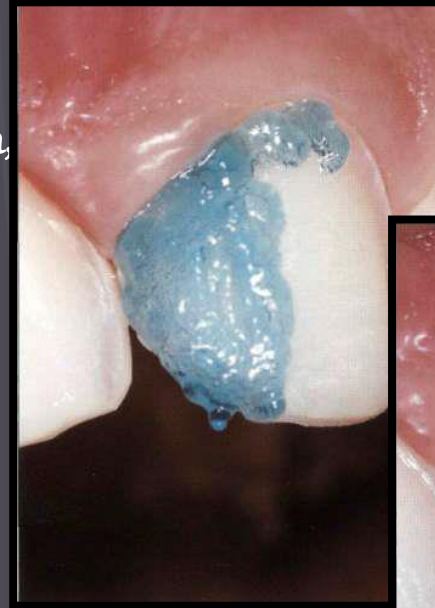✓ *One final check to be made with prepared silicone index from both occlusal view and lateral view.*



## *Pre-sealing the Exposed Dentin*

*“Just after the preparation and before the impression making”*

- Right after the completion of the tooth preparation, etching and a dentin bonding agent should be applied immediately
- To prevent post-operative sensitivity and bacterial invasion of the exposed dentin



# Porcelain Veneer Series

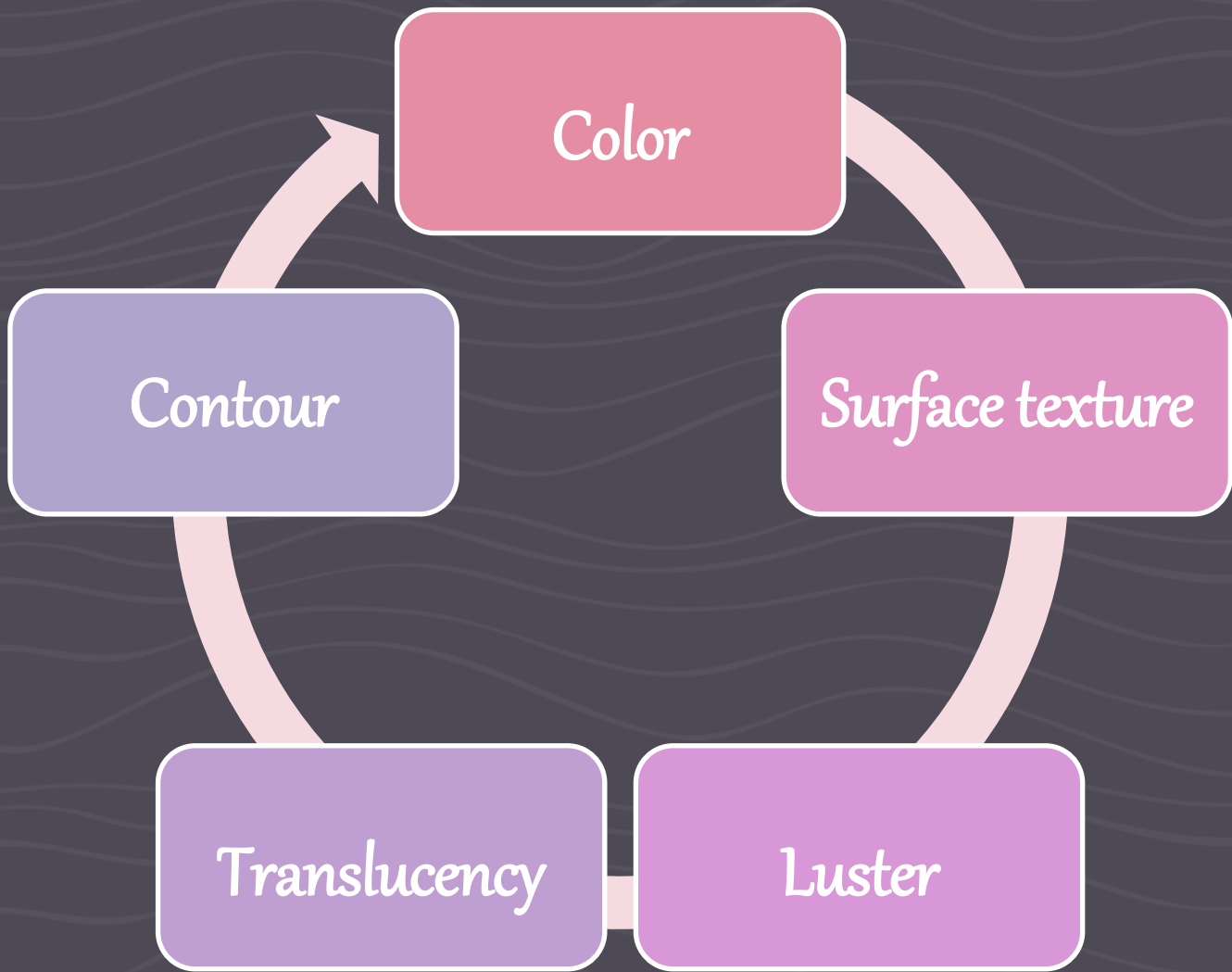
## Preparation Techniques

### Controlling Facial Reduction

[EstheticProfessionals.com](http://EstheticProfessionals.com)



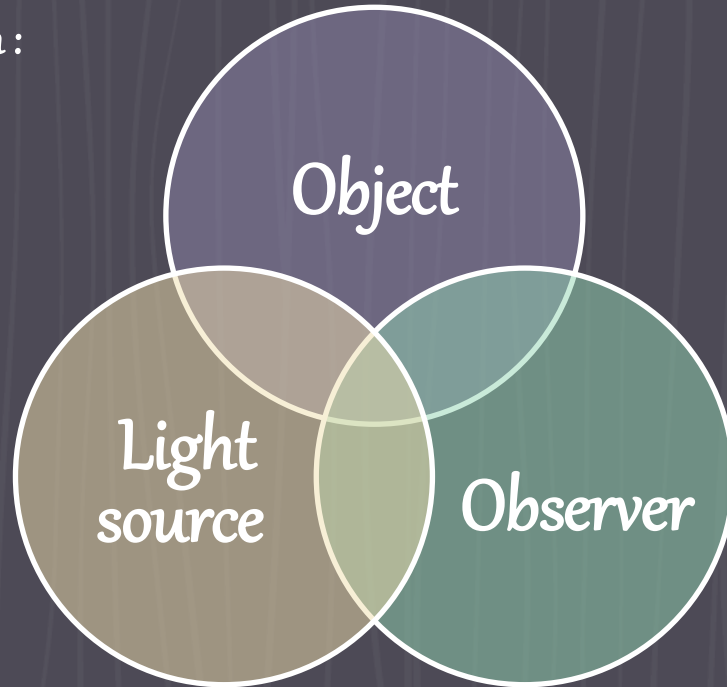
# *Shade Selection*



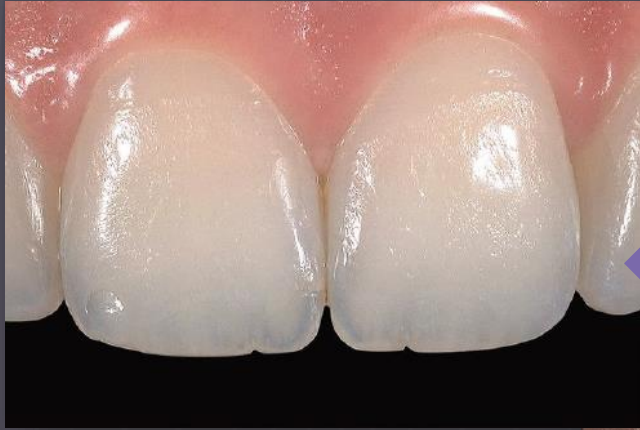## *Color Selection*

Color is actually a phenomenon of light and a matter of visual perception that allows us to differentiate between similar objects

The perception of color depends on :

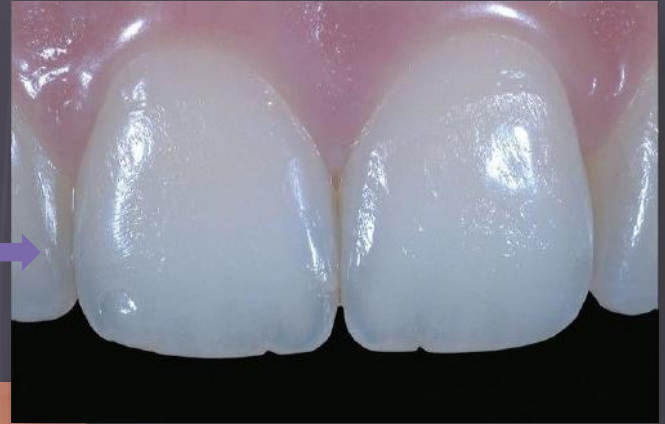

Light source conditions

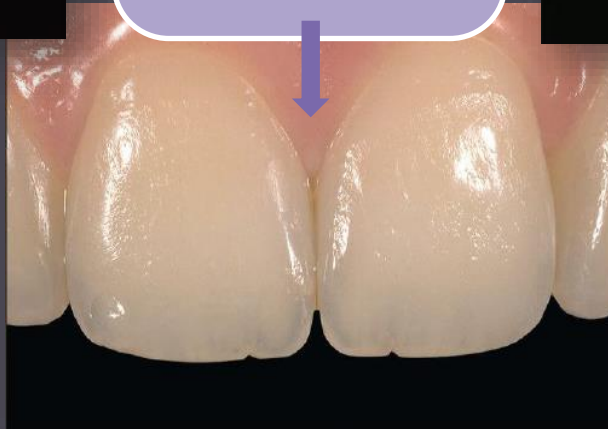

Sunny daylight

Porcelain veneer  
viewed under  
different light  
conditions

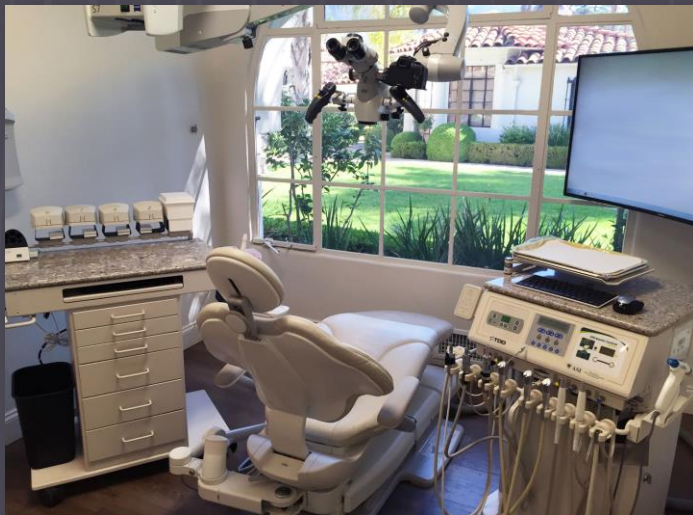

Fluorescent light



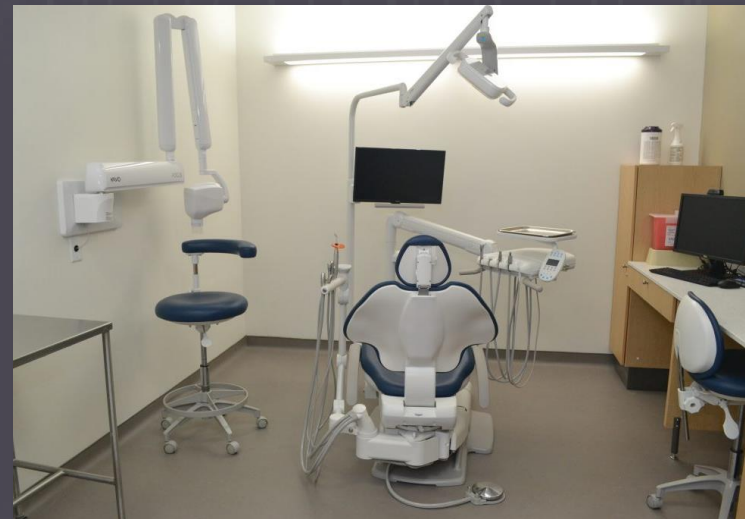Tungsten Lighting

## Clinical tips to determine an accurate shade match in dental operator



**Dental clinic with natural light**

Perform shade matching at 10 am  
or 2 pm on a clear, bright day

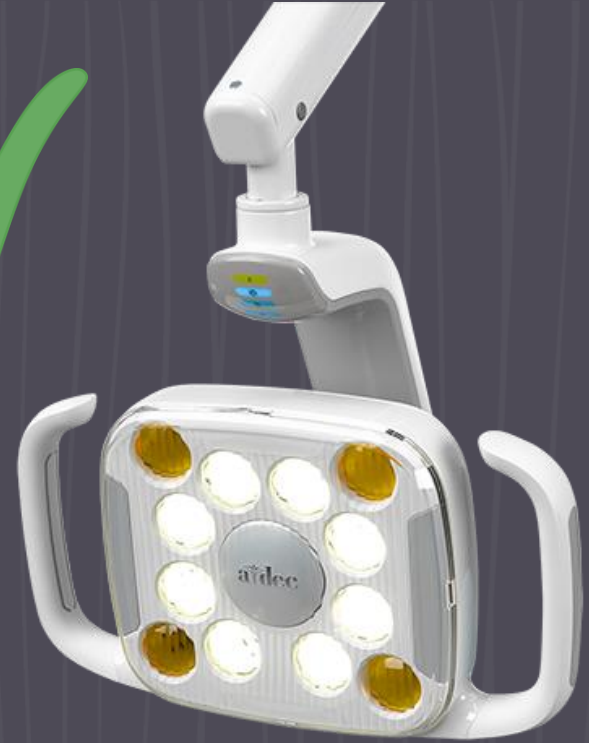

**Dental clinic with no natural light**

Color corrected LED Lights should  
be installed



Dental Halogen Operator Light.



Color corrected LED Operator lights

*Shade comparisons should be made under different lighting conditions. Initial shade may be taken under a color corrected fluorescent light and then confirmed in natural daylight (taking patient to an operator window).*

## *Object*

*No discoloration  
to be masked by  
veneer*

Discolored teeth  
to be masked

- The shade selection should be done even **before the tooth preparation** begins.
- **To avoid any value alteration** during the preparation period due to dehydration.
- Can **take upto two hours** for the dehydrated tooth's shade to return to normal

- **Remove slightly more tooth** structure
- The shade selection should be done **after tooth preparation** i.e. **'STUMP SHADE TECHNIQUE'**
- As soon as possible to avoid dehydration

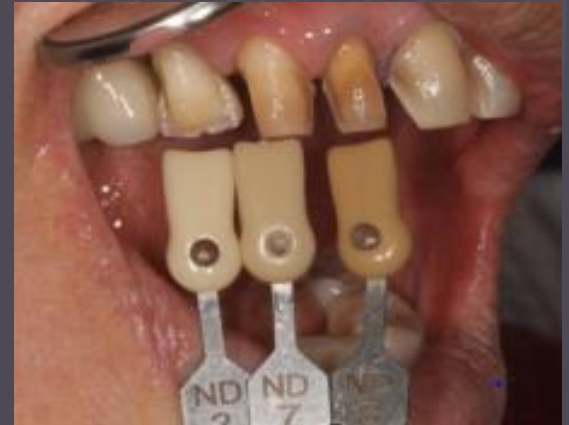## *Stump Shade Technique*

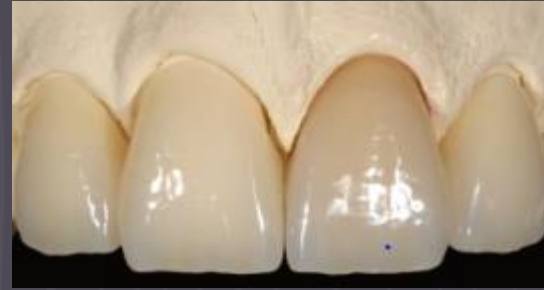
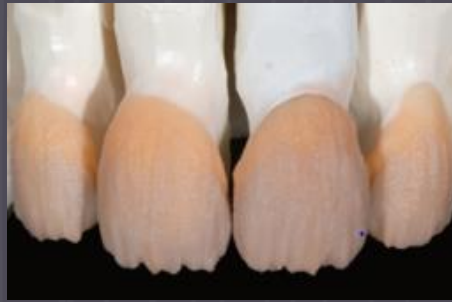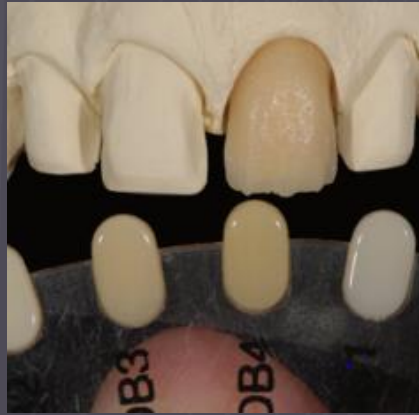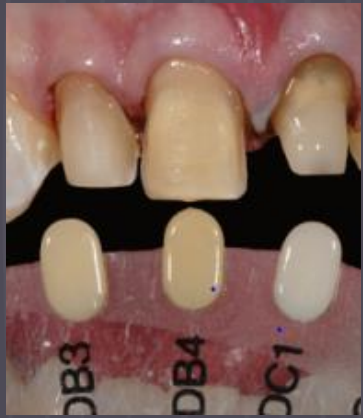When All porcelain restoration has been planned after preparing a discolored tooth/teeth with different shades.

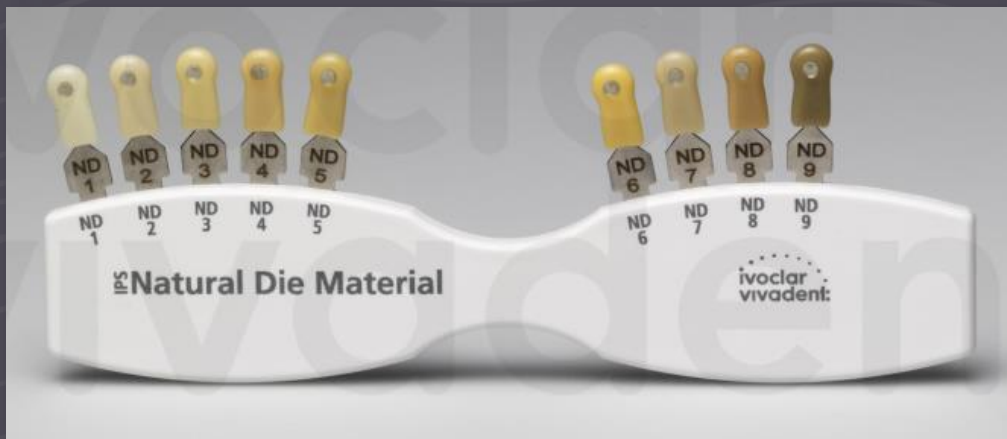
A critical piece of esthetic information for the lab is the stump shade and a stump shade photograph



The lab technician can use this information to make a model die that is the same shade as the preparation and make sure there is no show-through or shade change to the ceramic from the underlying tooth structure.





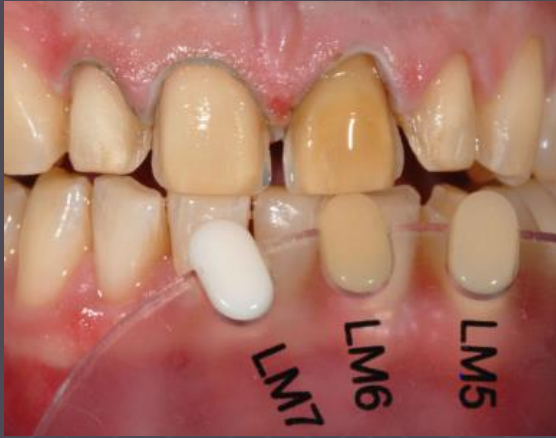

*Technician can actually fabricate the die from the stone that matches the stump shade you chose*

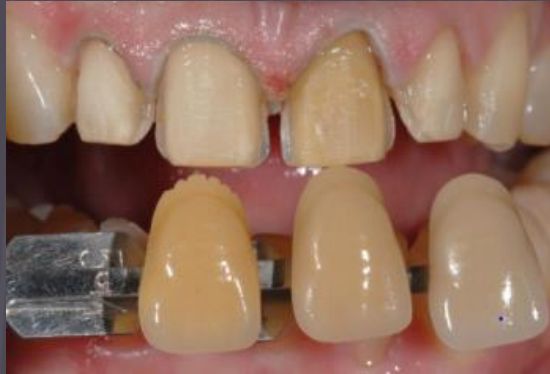

*Allows the technician to see a similar color and light effect that you will see with the restoration in the mouth*

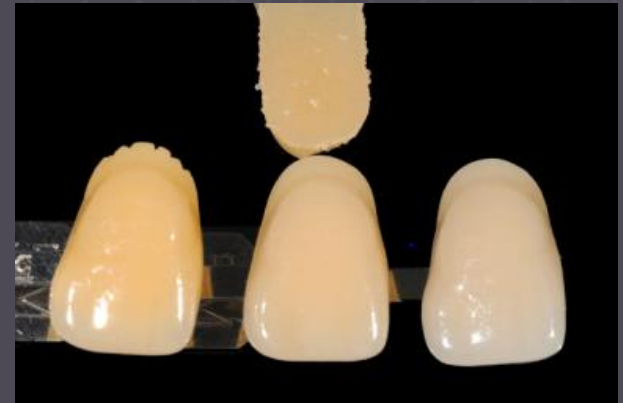- ✓ Use your traditional shade guide and take a separate shade for the stump



Laboratory Ceramic shade guide



Classical Clinical shade guide

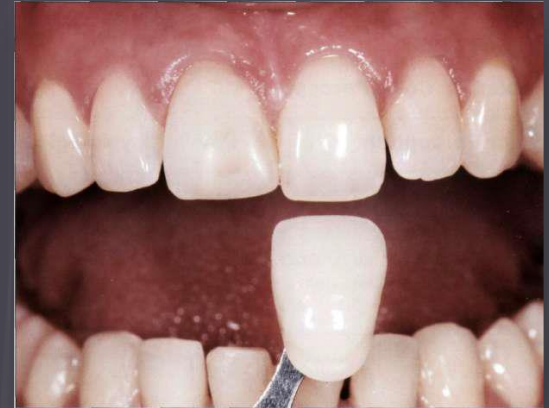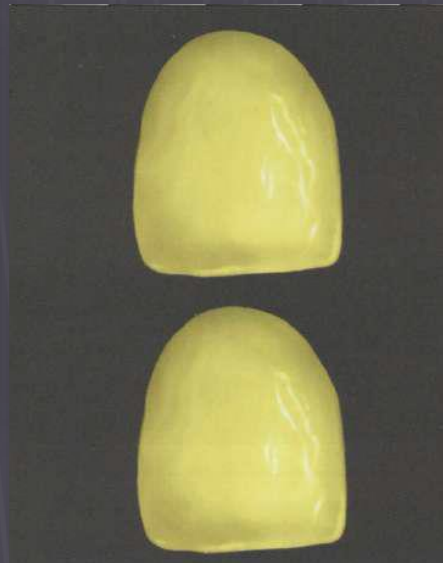
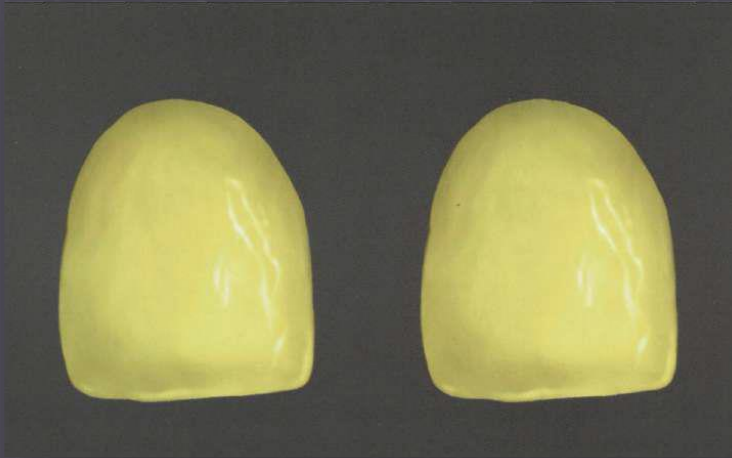


Custom made shade guide

## *Observer*

*Color is a matter of visual perception that might differ among different individuals*

*Binocular color perception : It is a perception variance between the right eye and the left eye.*





The diagram features two large, light pink arrows with white outlines, pointing in opposite directions. The left arrow points left and contains the text 'Manual Shade matching'. The right arrow points right and contains the text 'Digital shade matching'. The arrows are positioned horizontally and overlap slightly in the center.

*Manual Shade  
matching*

*Digital shade matching*




## Hue Based Shade Guides

This is especially true for lighter shades. With lighter shades, there is very little saturation of hue (low chroma), therefore, hue is not apparent, nor is it a factor in the shade selection process.



Value Based Shade Guides are more accurate as our eyes are more sensitive to changes in lightness/darkness & chroma than the subtle changes in hue.



If value and chroma are correct, the restoration will be clinically acceptable, even if the hue is slightly off the optimal.

## Hue Based Shade Guides




Sequence of shade matching:

1<sup>st</sup> Hue


2<sup>nd</sup> Chroma

3<sup>rd</sup> Value



## *Value Based Shade Guides*

The only commercially available Value-Based Shade Guide



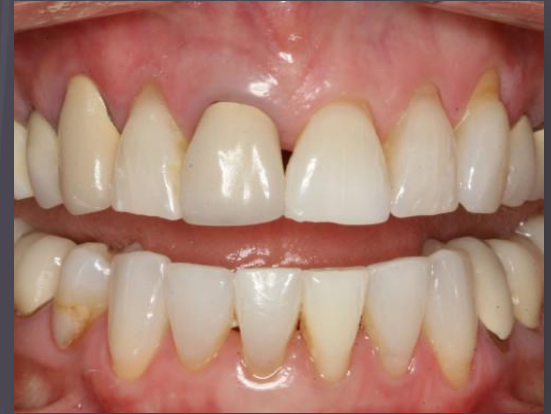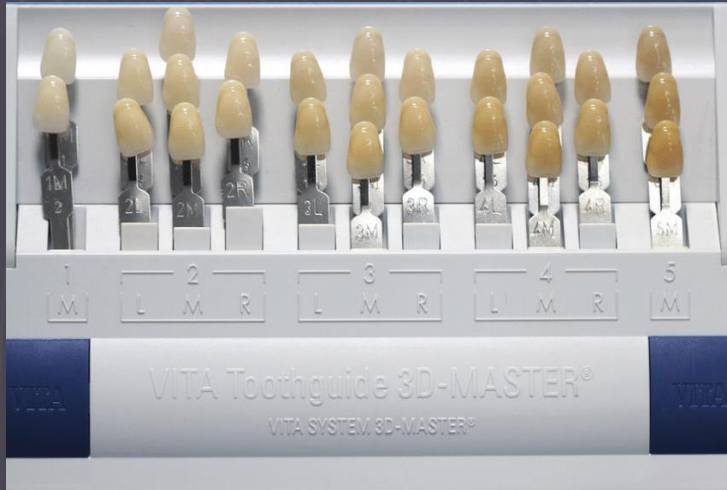Vitapan 3D Master Shade Guide (Vita)

It consists of 26 shade tabs having 6 Value based group i.e. 0, 1, 2, 3, 4 and 5

Within each Value, there are three Hue variations, which are denoted as M (Standard Hue), L (Yellow Hue) and R (Red Hue).

Within each variations, there are 2-3 Chroma variation.

Clinical representation of shade selection using vita 3D shade guide.



Selected shade: 2M2.

Sequence of  
shade  
matching

Value

Hue

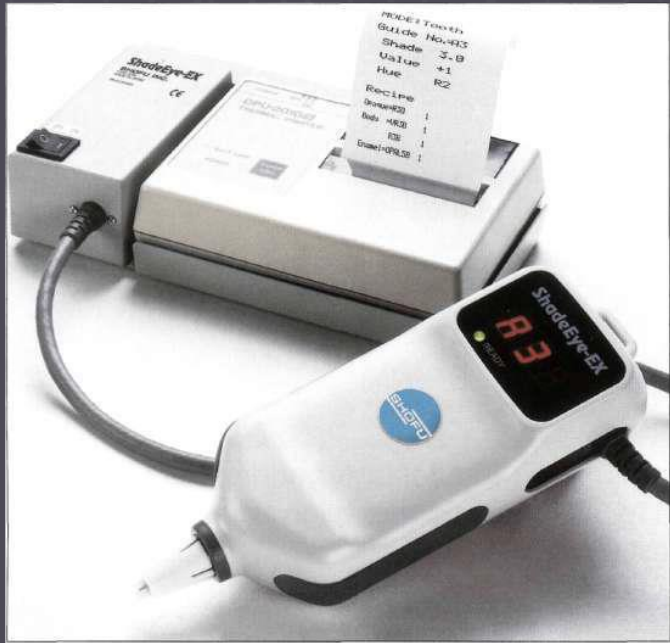chroma

*If the dentist has hesitations about the final color :*

*It may be more advantageous to finish the PLV lighter in color (high value), so that its value can therefore be more easily lowered by the underlying composite. In contrast, it will always be more difficult to lighten a darker colored PLV*

- *In comparison to the thin veneer ceramic restorations, the guides are made of a much thicker porcelain & therefore the porcelain used for the shade tab is quite different from the porcelain used for fabricating the restorations*
- *A commercial color guide with 16 selections cannot possibly cover the variations exhibited in natural teeth*

## Digital Shade Selection



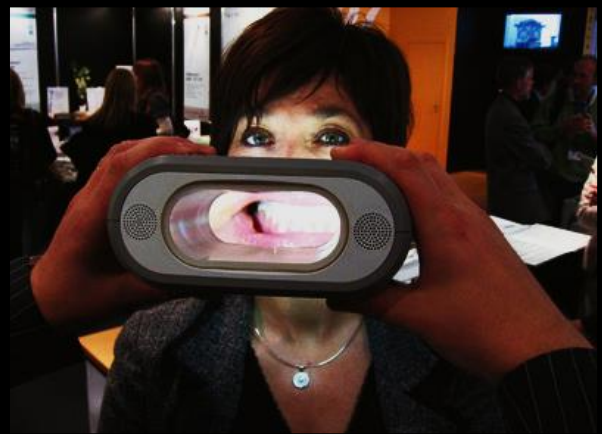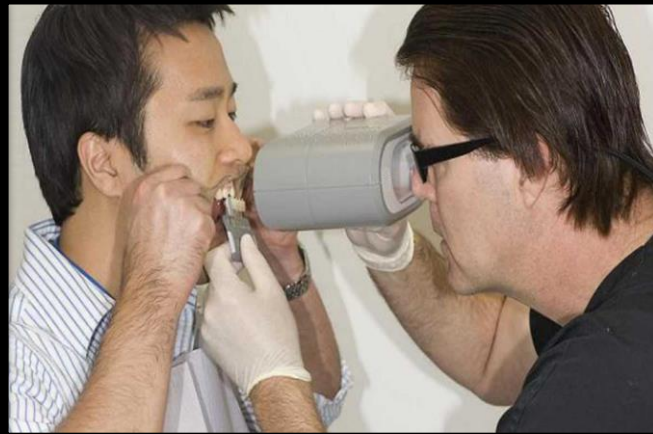The Shofu ShadeEye-EX Chroma Meter (Shofu, Menlo Park, CA)



VITA Easyshade® V



Shade star, Dentsply

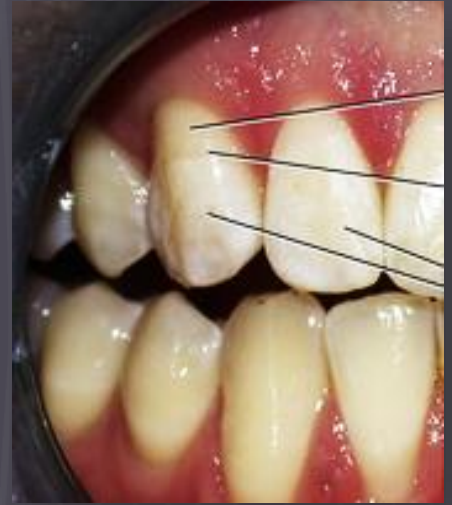

### *“The Optilume Trueshade,”*

*A new device that eliminates the variability of different light sources, “the optilume trueshade,” uses full-spectrum LED light and shows a color spectrum similar to mid-day light.*

## *Clinical tips for Shade selection*

- ✓ Select the final shade of the veneers, based upon the patient's preference as well as the **tone of hair, eyes, and skin**
- ✓ Select the **original shade of the hydrated unprepared tooth** structure as a reference point
- ✓ Because eyes usually tire after 5 -7 seconds, it is recommended to make a selection quickly and to accept the first decision.
- ✓ **Avoid bright colors** in the shade-taking environment, i.e. no lipstick, tinted eyeglasses, no bright-colored clothes.
- ✓ Select the stump shade after the final tooth preparation

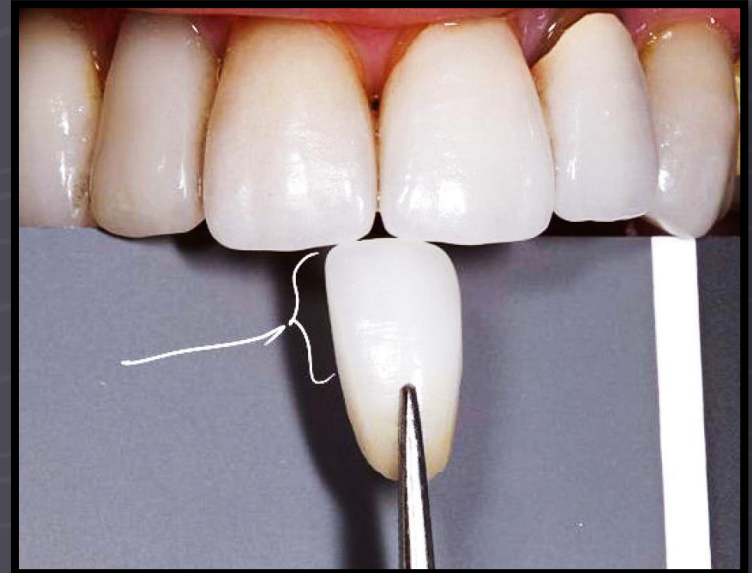


One should **stare at a tooth for less than 5sec**. Prolonged viewing of a color for 15-30 seconds strains the cones and causes depletion of photopigments

Gray is an excellent color for the environment in order to accurately evaluate the shade of the restorations, as it is a combination of primary and secondary colors and does not have a contrasting complementary color.



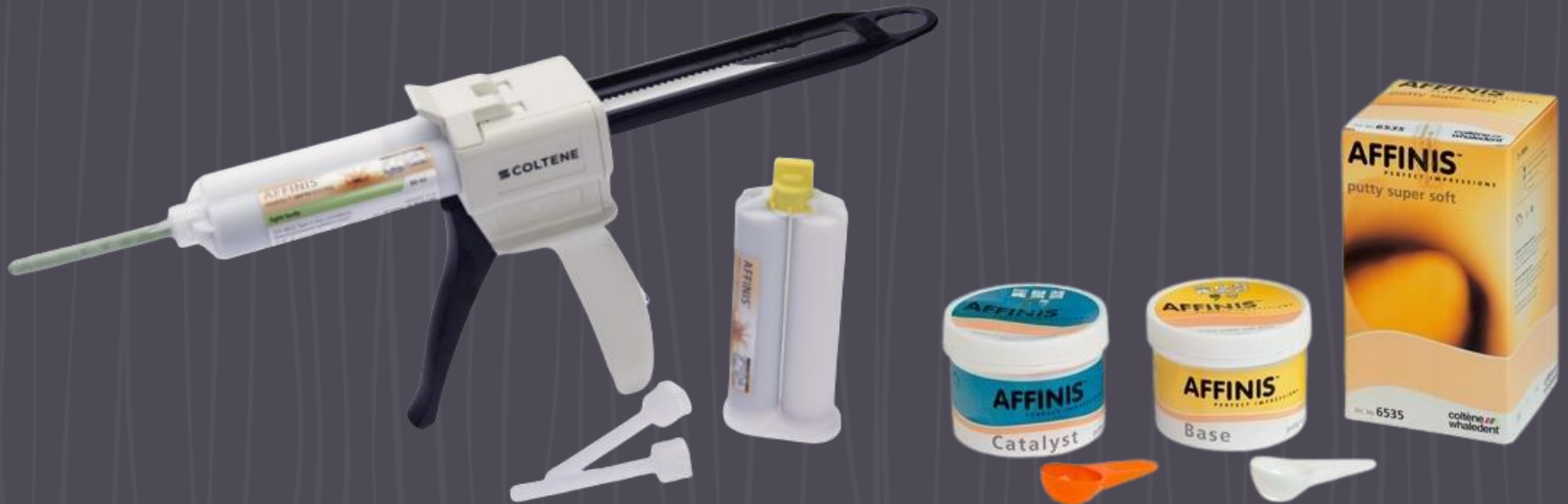**The after-image & the strain in eyes that occurs when looking continuously at an object of one color can be minimized by looking at a grey object between assessing different shade tabs**





# *Impression Making*

- ✓ High viscosity polyvinyl siloxane putty is the most rigid impression material
- ✓ Should never used alone but with the low polyvinyl siloxane (wash), with low rigidity.

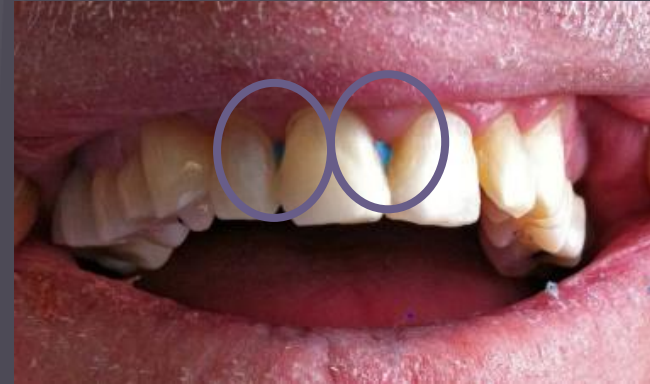

## *Retraction cord Placement*

*If the margin is placed sub-gingivally, retraction cords can be used.*

*If there is too much tissue fluid coming out of the sulcus & if it is suspected that this may distort the impression, then a double cord technique can be used.*

- If there are *big undercuts* at the *palatal surface*
- If *larger gingival embrasures* exist



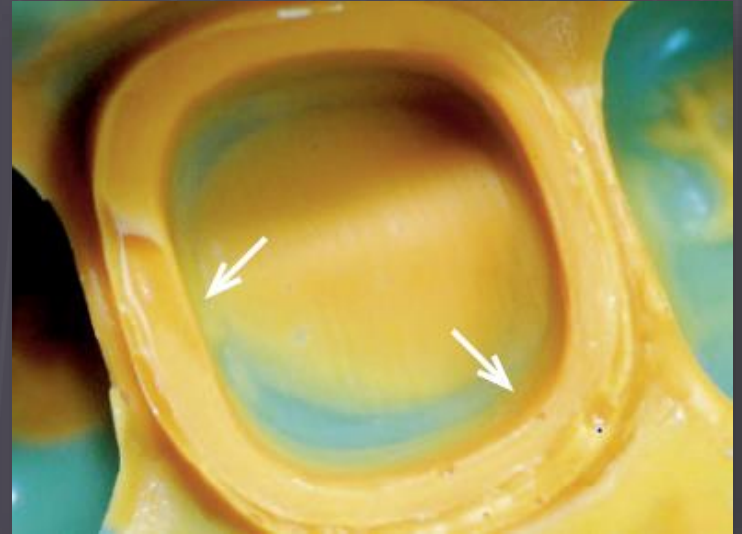
✓ Blocking these sites is indicated before impression making

✓ Once set impression must be removed as quickly and as straight as possible to prevent distortion

These hydrophobic materials have **missing surface affinity** for moist tooth surface .

**Cannot displace any moisture or hemorrhage** that is not removed prior to placement of the impression material


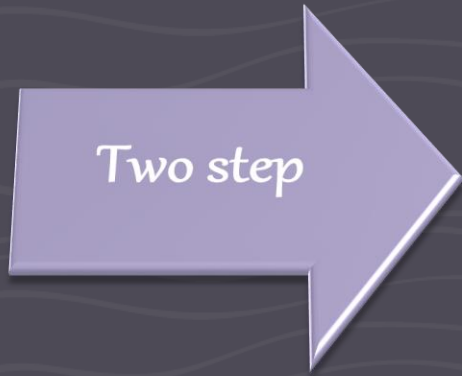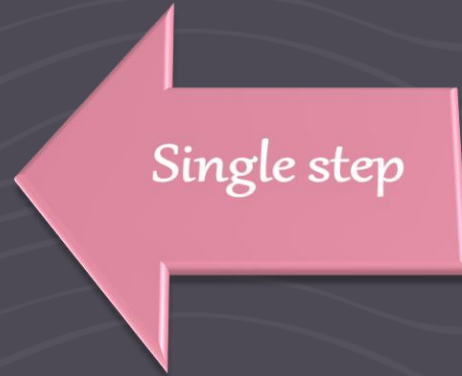
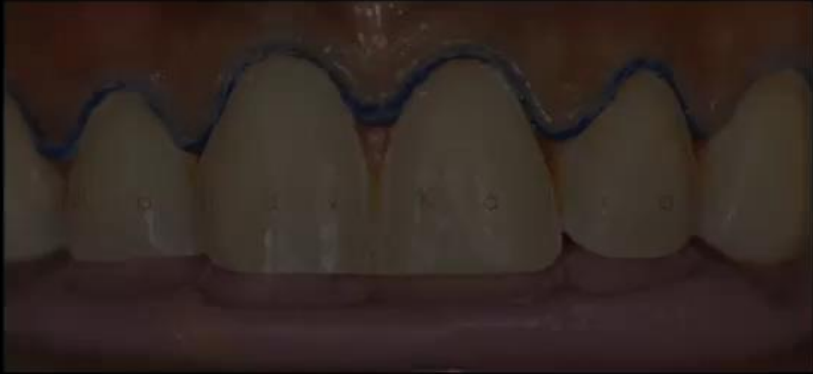**Can result in cavities, defective points, margin distortions or distortions in the impression**



- **Modified polyvinyl silicones** contain a surface activated substances that not only improves the wetting properties, but also restricts the flow.
- Avoid using LATEX gloves while making an impression with addition silicone.

Even if the impression material comes in contact with a tooth that has been touched by a latex glove (not even directly the glove itself), it may cause polymerization retardation

- ✓ To avoid this vinyl gloves can be used during impression making while handling the impression material



Impression is rinsed, blowed, dried,  
and then inspected.

Placed in a disinfectant solution  
before pouring it.

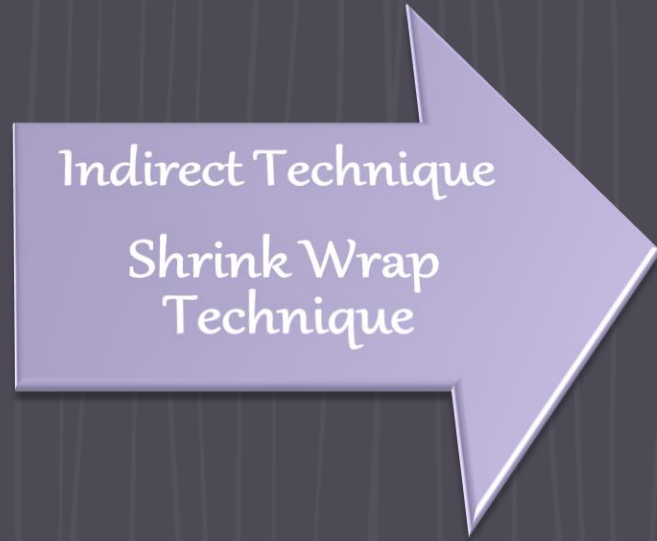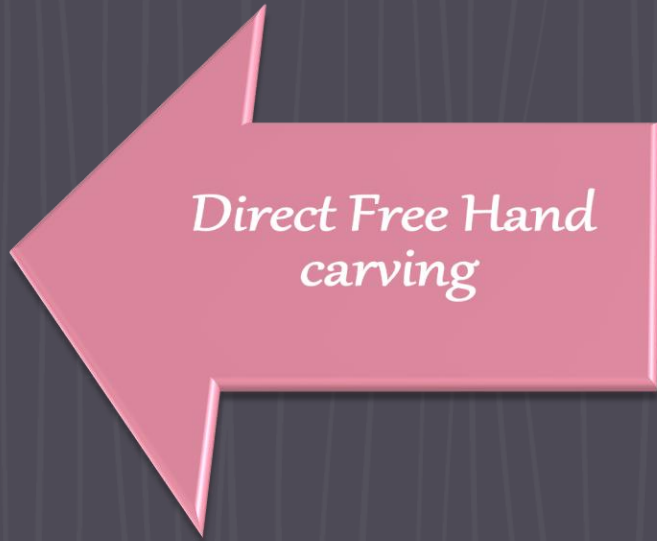Immersion in iodophors or sodium  
hypochlorite can be used to  
disinfect the alginate hydrocolloids



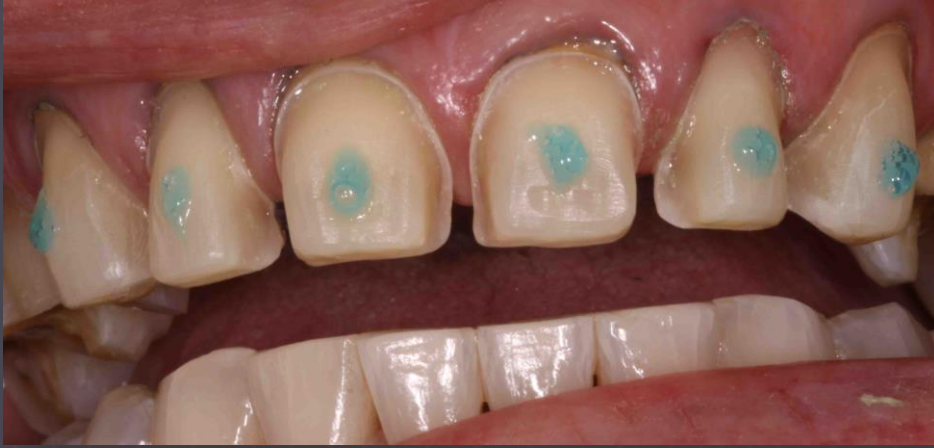These materials may release hydrogen gas on setting pouring should be delayed for a short time of 15 to 30 minutes



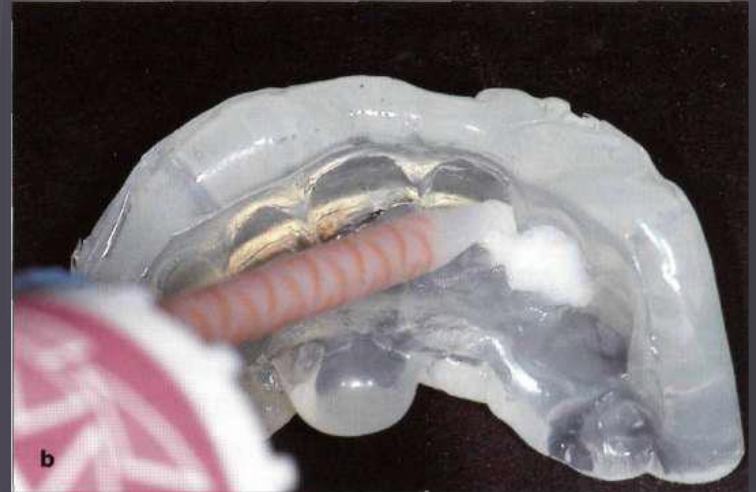# *Temporization*



## Indirect Technique



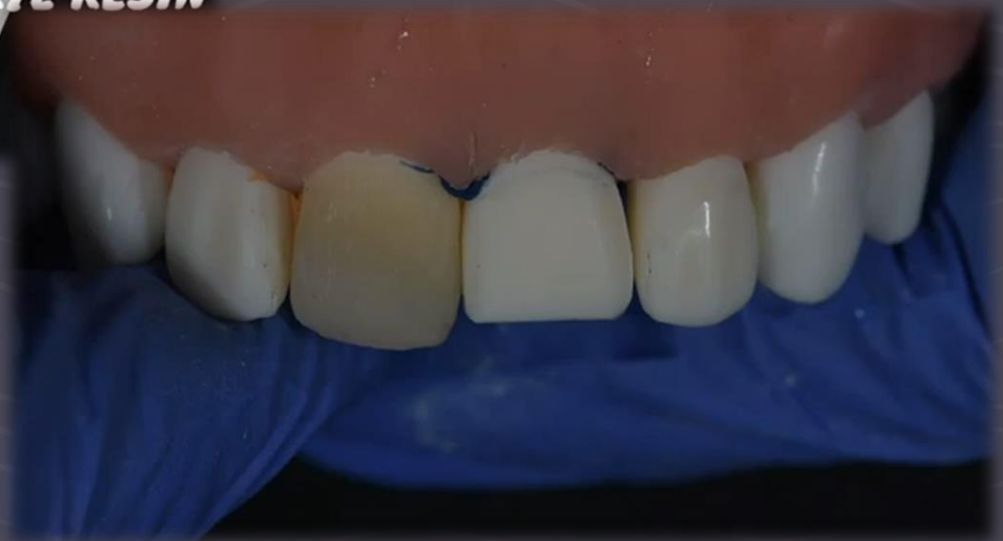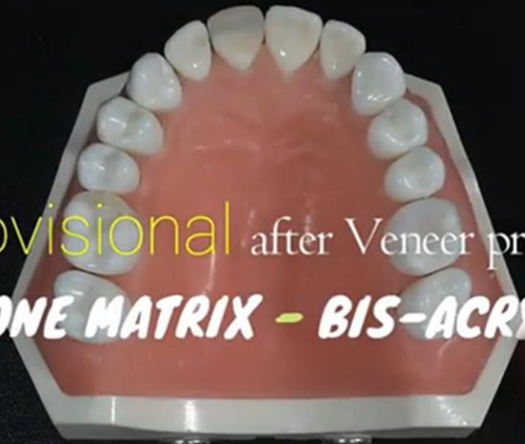- *Keep the spots on the same horizontal level*
- *This will ease the cleansing of the bonded area just before actual bonding*



*A flowable composite is then loaded into the translucent silicone template and placed over the prepared teeth*

Provisional after Veneer prep

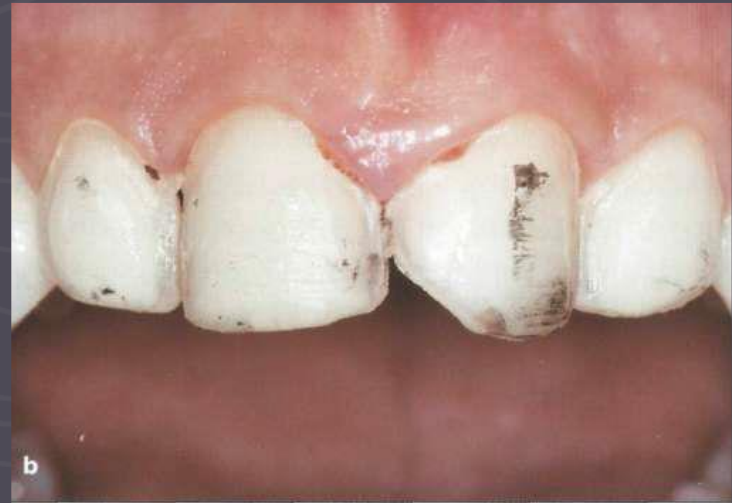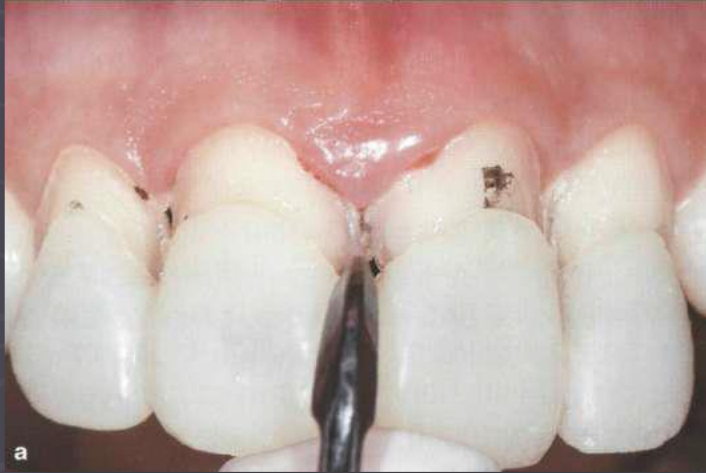Using **SILICONE MATRIX - BIS-ACRYL RESIN**



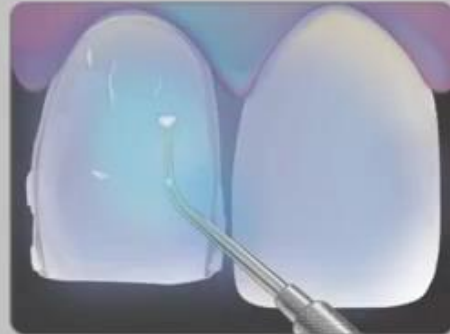
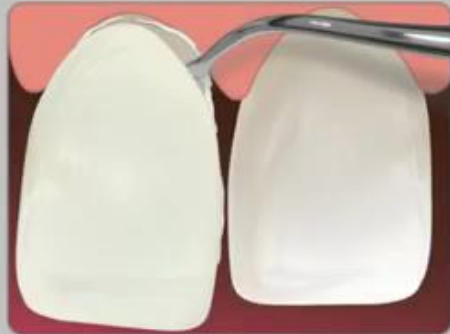

*Try-In*

*The provisional veneers have to first be debonded*



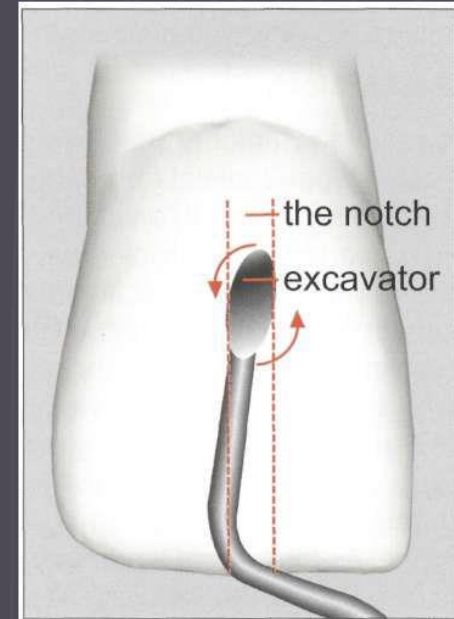
## Part 2: Removal



*If the provisional resists dislodgment, then the facial surface can be vertically cut with a tapered fissure diamond bur*

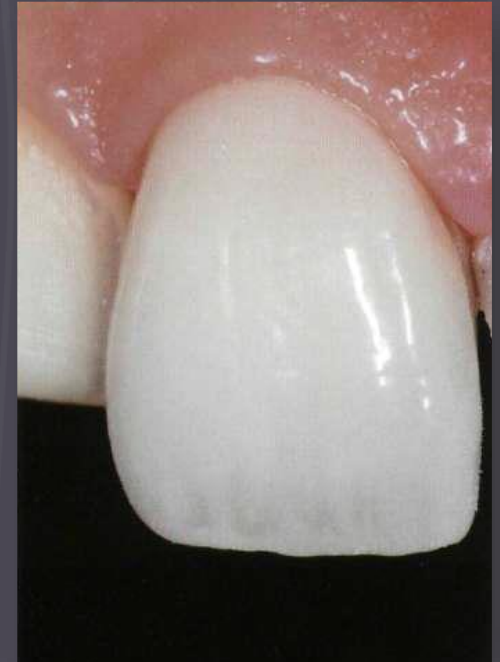*The spot etched area can be slightly entered into with the diamond bur to enhance debonding.*

*After that, the spoon excavator can be placed into the vertical notch with a torsion movement and the provisional can be broken into two fragments and easily removed*



## *Try-In*

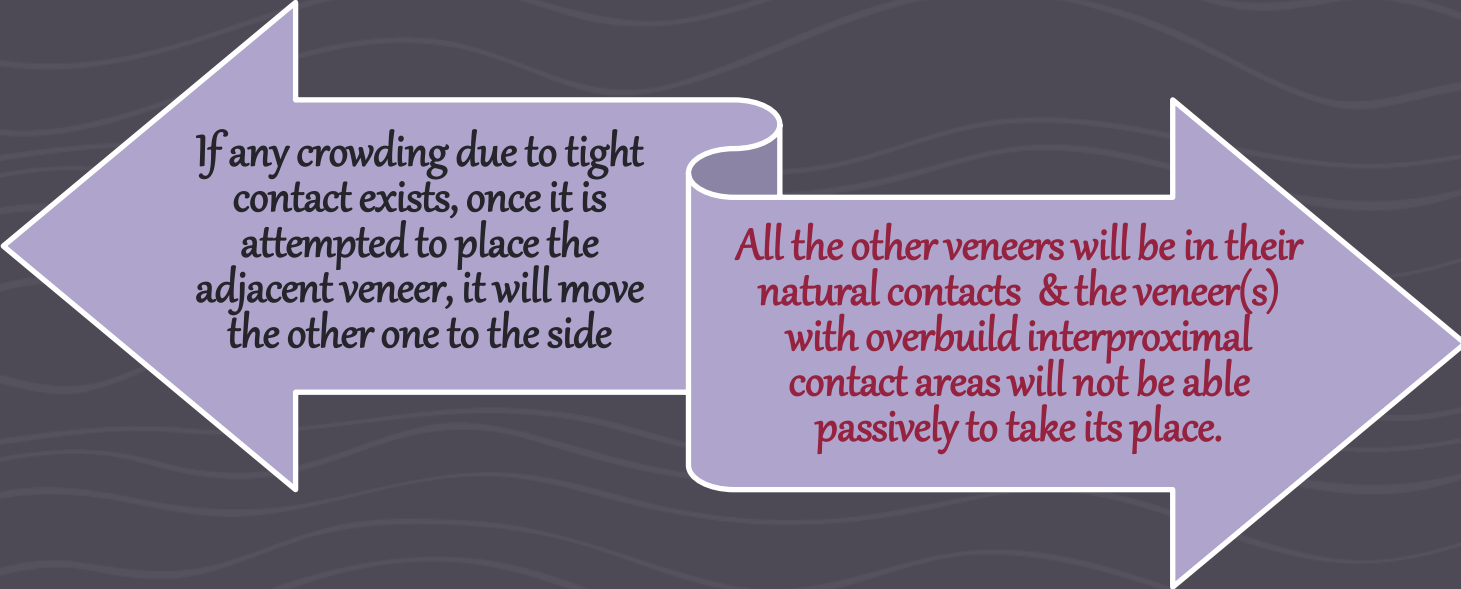
- Each veneer has to be **tried in individually** to evaluate their biologic integration relative to tooth and gingival harmony
- **Pressure should never be exerted** at this stage since the porcelain are very brittle before being bonded.
- **Check for marginal discrepancy, if any.**



Results in an unaesthetic outcome in cases of supragingival placement or cause periodontal problems in cases of subgingival placement

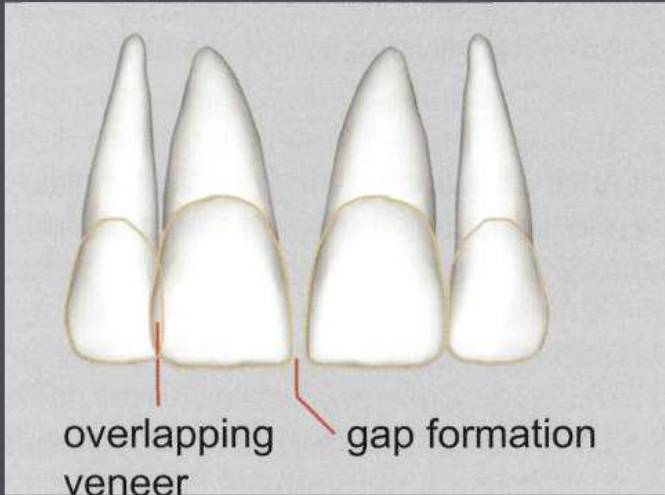
Once they are individually checked, all PLVs should be collectively tried-in to evaluate the proximal contacts and contours

Under normal circumstances, the veneers should be passively seated on the teeth without any interproximal tightening

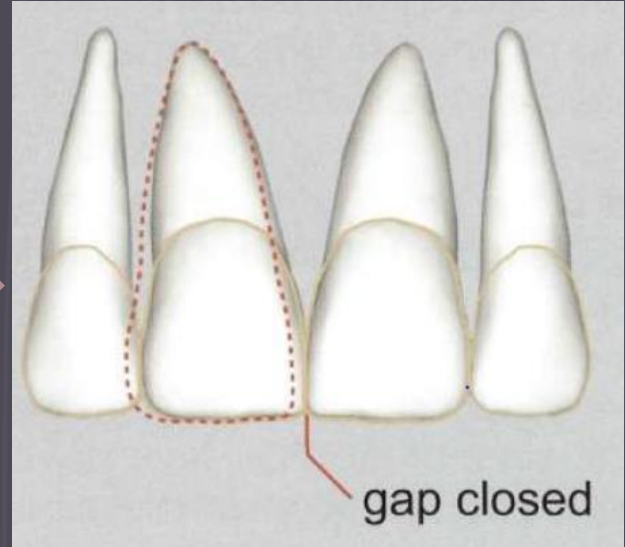


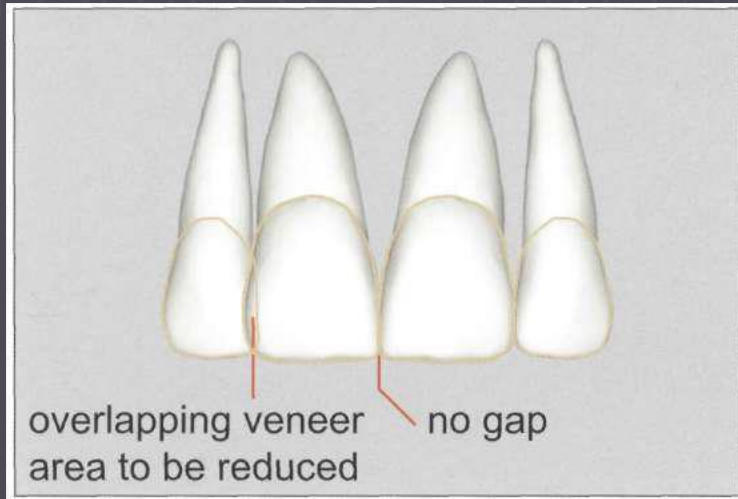
*If any crowding due to tight contact exists, once it is attempted to place the adjacent veneer, it will move the other one to the side*

*All the other veneers will be in their natural contacts & the veneer(s) with overbuild interproximal contact areas will not be able passively to take its place.*



*Finger pressure can be applied to  
realign the position of the tooth*



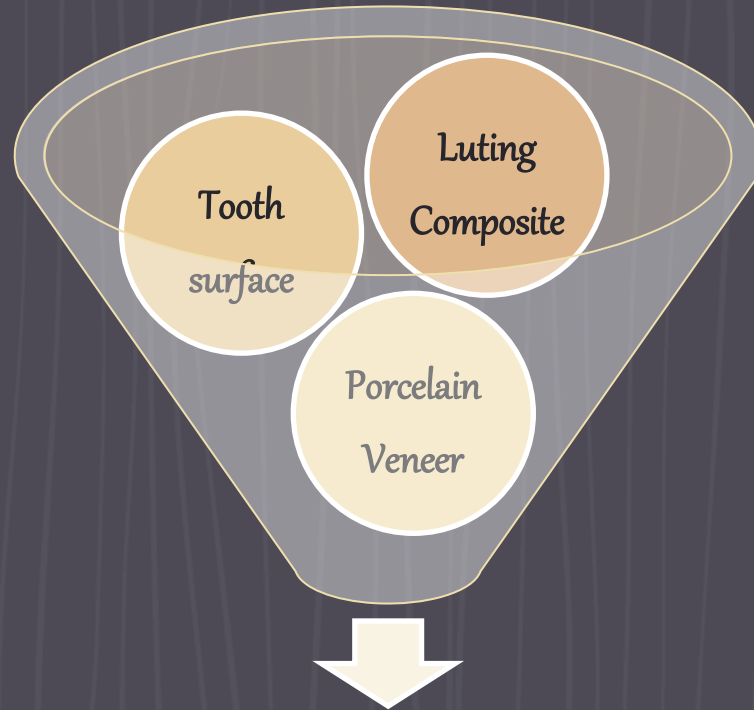


*The mesial or distal marginal ridge must be adjusted to obtain that passive fit*

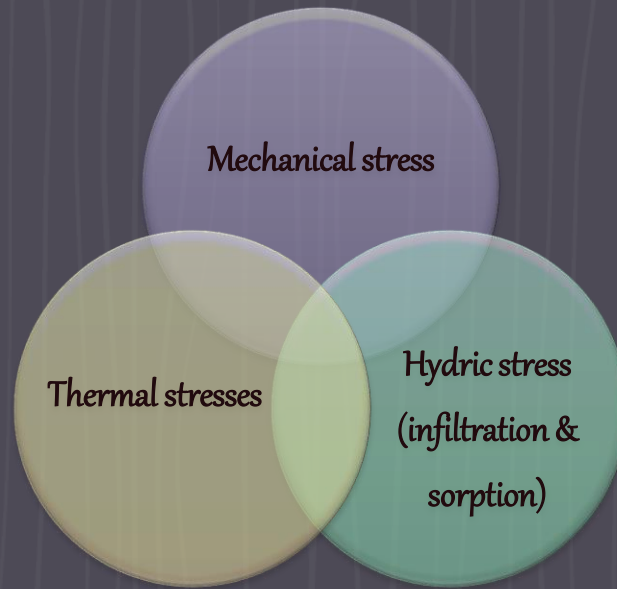


# *Bonding*

The strength and durability of the bond between the tooth, the veneer and the luting composite is what actually determines the success of the PLV treatment



Components of a Ceramic Restoration



*The bond strength to etched & silanated ceramics is even as high as 45 Mpa*


*These bond strength values are high enough to resist tensile and shear forces that are generated by thermal expansion or by shrinkage during the polymerization of composites*

## *Treating the PLV*

No bond formed between the glazed porcelain and composite resin, even with silane unless the surface was first roughened.

The inside of the veneers should be sand blasted & **acid etched with a 10% hydrofluoric acid for 1- 4 min** and then sent to the clinic.

- Selective silicate compounds are dissolved from the surface
- Surface activation of ceramic materials.
- Strength doesn't diminish over extended periods of time.



*Bond strength of a luting composite to the etched porcelain surface*



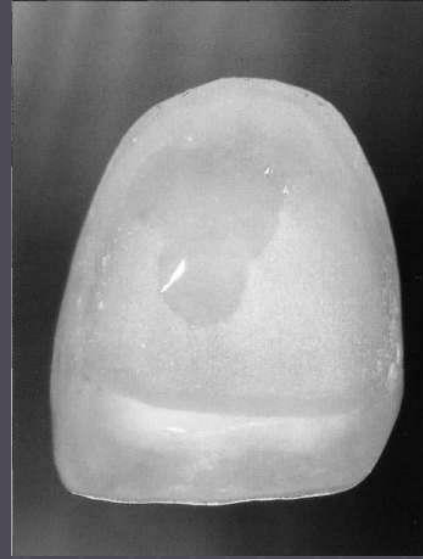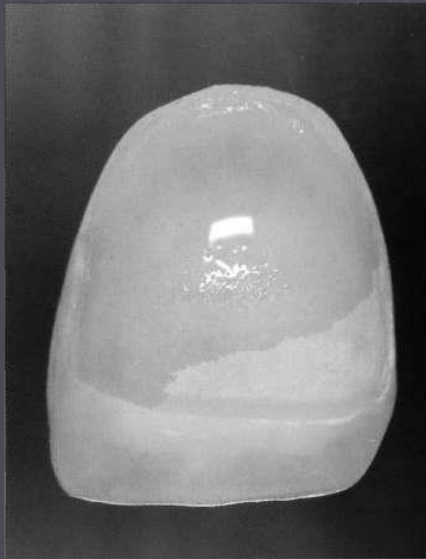*Cohesive strength of the porcelain itself/  
That of the bond strength of a luting composite to etched enamel*

*The display of the inside of the PLV should be opaque over the entire surface.*

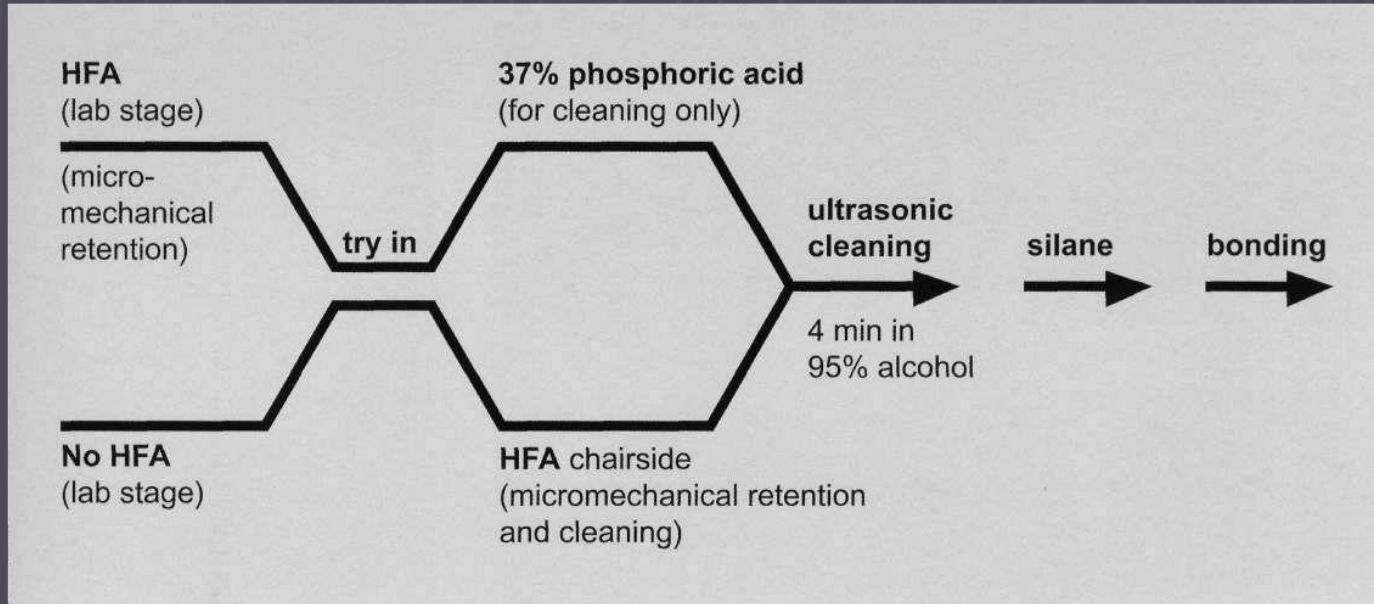
*If there is, any place that displays a less opaque appearance, than that area should be etched again and the same check should be repeated in that area*

## *Checking the etched surface*

Place a drop of water into the etched surface. If the surface is etched completely, the water will spread all over the internal surface. The cleaning process of the porcelain is aided by the increased wettability of the etched surface



A great number of acid crystals still stay deposited on the etched surface that may affect the bonding strength. In order to eliminate this, the veneers should be placed into the ultrasonic cleaning in 95% alcohol for 4 minutes, or acetone or distilled water



## Silane Application

- *Increases wettability*
- *Bi-functional agent provides chemically bonding to the silica. The silane group bonds to the hydrolyzed silicone dioxide copolymerising with the adhesive resin.*

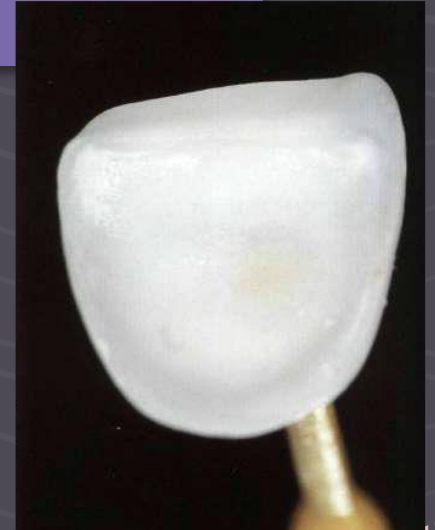*A fine layer of a silane coupling agent is painted over the internal surface of the laminate veneer*



*Allowed to remain in contact with the etched porcelain for one minute*



- Dried with an air syringe by blowing the air parallel to & slightly above the veneer
- Allows the solvent to evaporate completely
- "warm air" (possibly with a small hair dryer) will enhance the effect of the silane



*A salty-looking appearance after drying*

Single component systems that contain silane in alcohol or acetone are the simplest ways to silanate

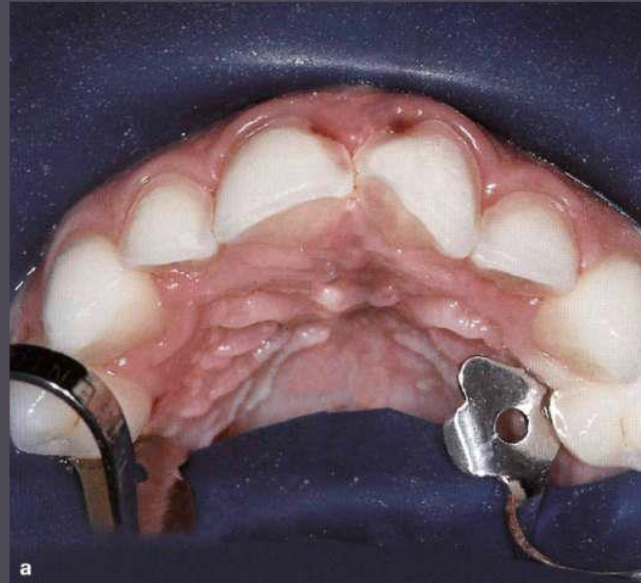

The adhesive compatible with the luting composite to be used is applied over the whole interior surface, but NOT LIGHT CURED, but kept in the dark

## *Treating the tooth surface*

The area should definitely be kept clean and purified of blood, saliva or oral contaminants

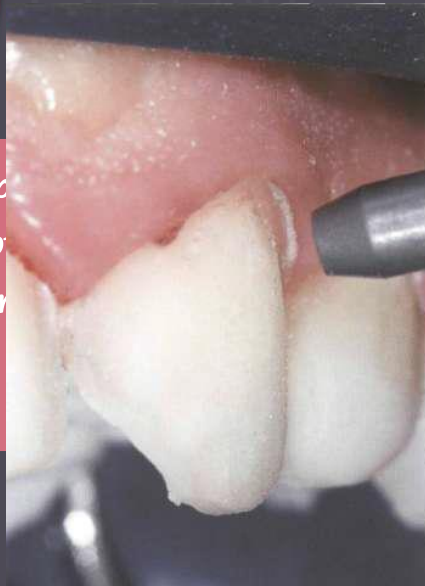A partially sectioned rubber dam application is preferred while bonding the veneers



*Dentin not sealed*

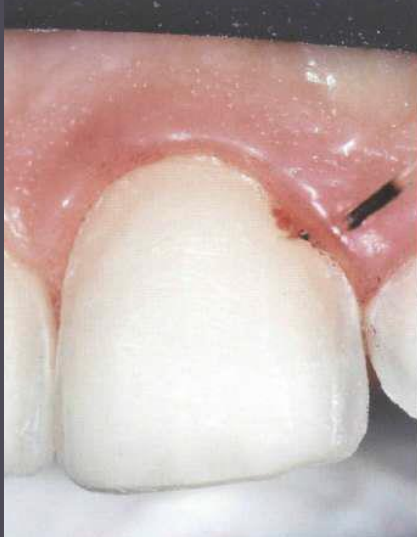*Sealed dentin  
Preparing  
Hybridized Surface*

- Pumice slurry in a p cleaning the teeth p
- Aggressively with br pumice
- Air-abrasion

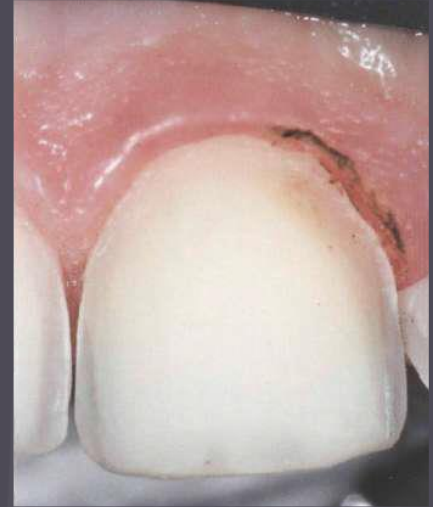

- *Either be gently cleansed and roughened with a diamond fissure bur or sand blasted with air abrasion*
- *The remaining bonding agent on this spot of enamel should be very gently removed with the help of a diamond bur in order to obtain a clean surface for enamel etching*

- *Sometimes the tissue may bleed shortly after the sandblasting*
- *The tissue might have grown over the prepared margin due to a small gap left on the provisional.*



*Stop the bleeding with a diode laser (Biolaze). This will immediately stop the bleeding with a highly accurate control of the soft tissue contours*



## *Etching the tooth surface*

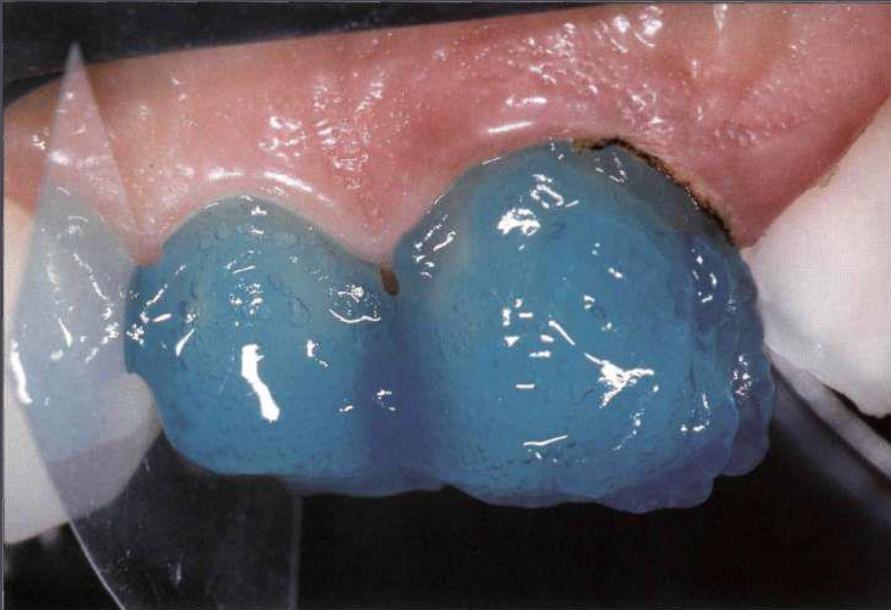
**37% phosphoric acid as a standard procedure**

10% maleic acid

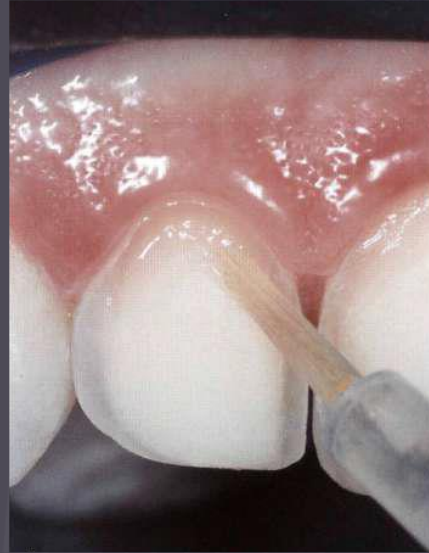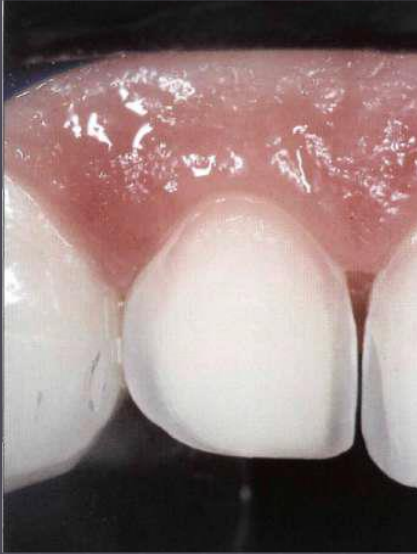1.6 % oxalic acid

2.6% aluminum nitrate

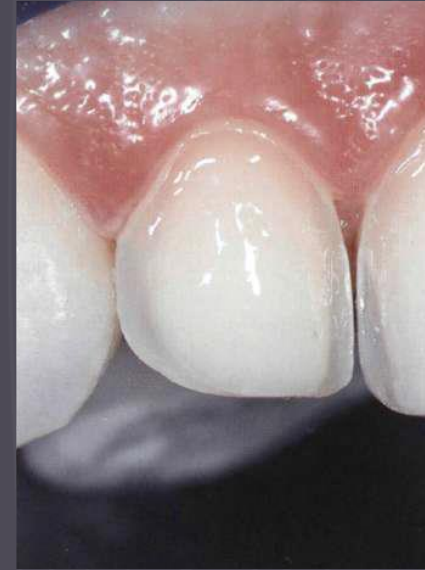10% citric acid.



- **Should not exceed 15 seconds on the dentin** in order to prevent collagen collapse, and thus decreasing the penetrability
- **Dentin should only be blot dried** with the help of a cotton pellet, in order to achieve "wet bonding"



*Primer is painted on the exposed dentin area only.*



*Adhesive is placed over the whole prepared surface with a brush, giving it a shiny appearance*

## *Bonding*

A **light-curing luting composite** is preferred for cementation of porcelain Veneers :

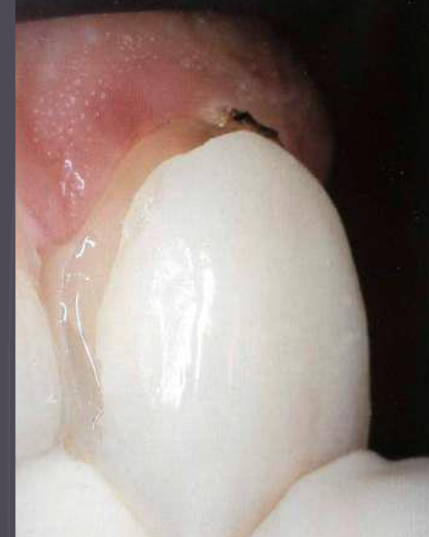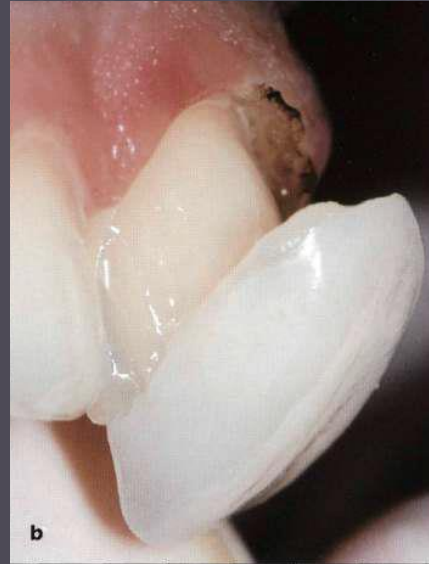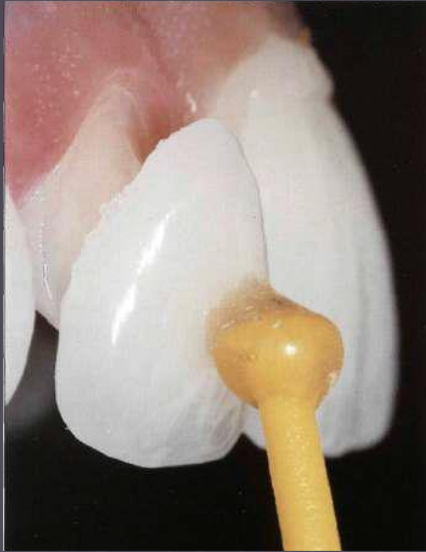- A longer working time can remove excess composite prior to curing
- their color stability is superior

If no color adjustments are needed, a transparent luting composite should be used

It is always better to place the luting resin inside the veneer to ease the control

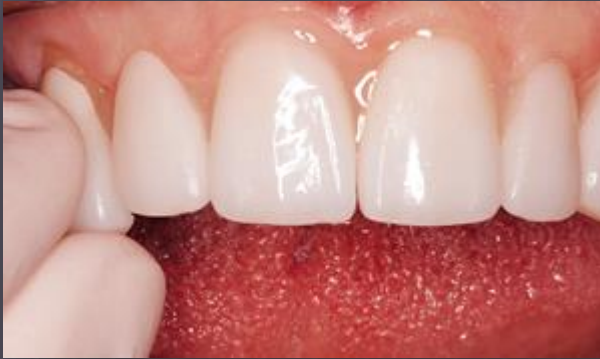## *Seating the veneer*

Starting from the incisal edge & progressively pushing the veneer towards the gingivo-apical direction is the best way of avoiding the formation of voids



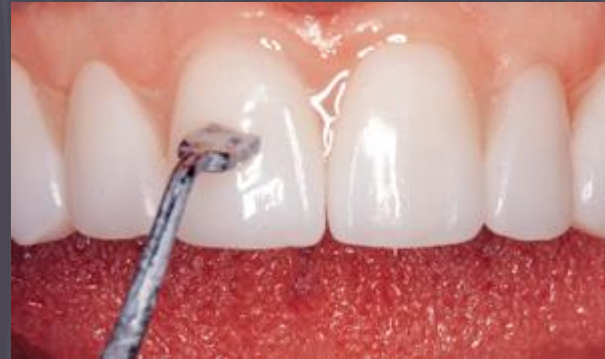Pushed apically and palatally with gentle finger pressure. The excess luting resin luting resin flash coming out from all the margins on all the margins, confirming that enough material is used

- *Keep the veneer seated on the tooth with some sort of gentle pressure,*

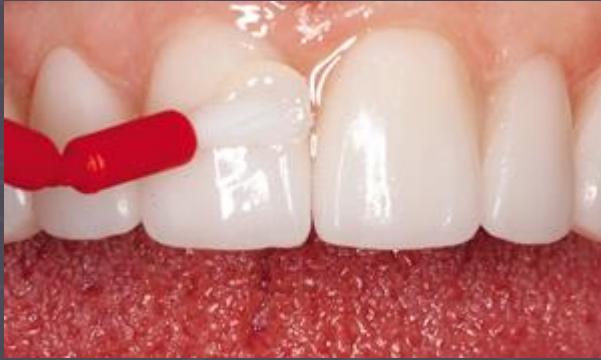

Finger Pressure

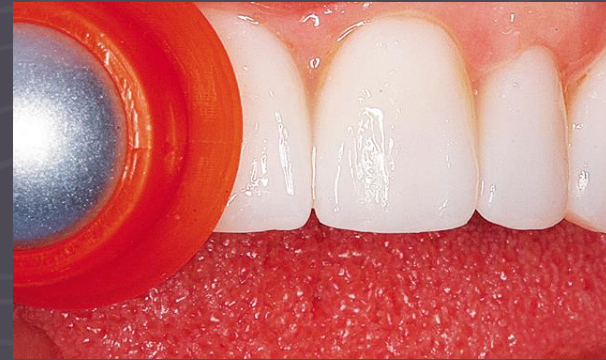
*Special tips placed centrally at the middle third of the crown*



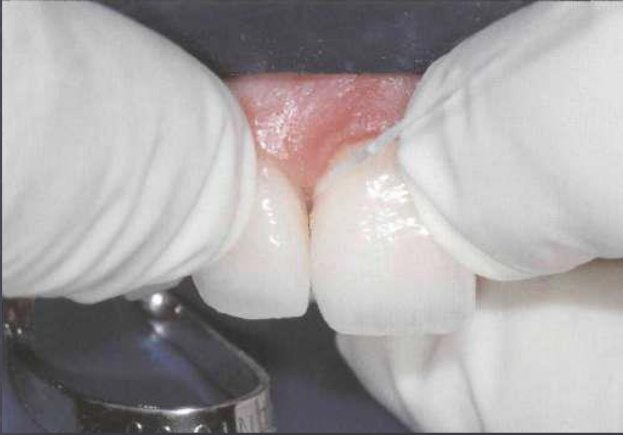- *Composite flash that came out from the margins*



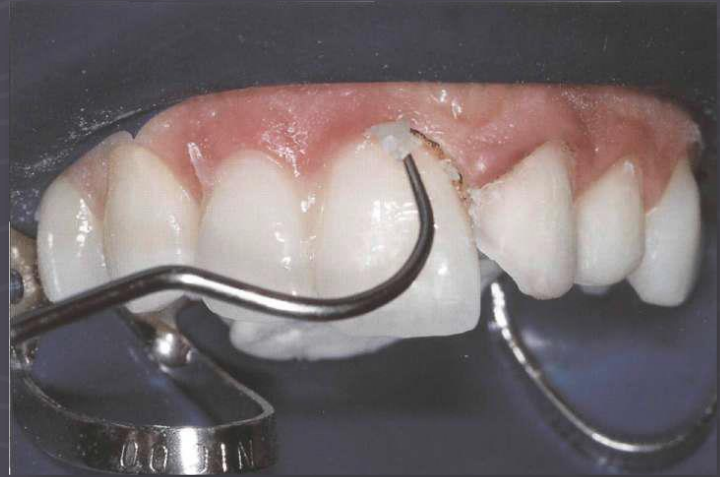*A brush was used to remove excess luting composite at the marginal areas*



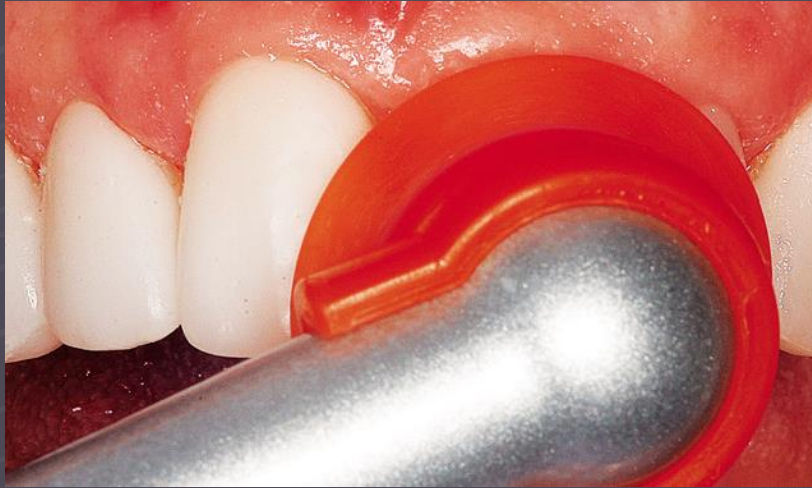*“Tack” cure for two second.  
“Tack” the laminates to place with a quick two second burst of ligh*



*Floss is used to remove excess proximal composite at this stage*



*No. 12 surgical blade/Explorer was used to aid in removing interproximal excess*



*The luting agent is completely polymerized  
from both palatal and facial 60 seconds each*

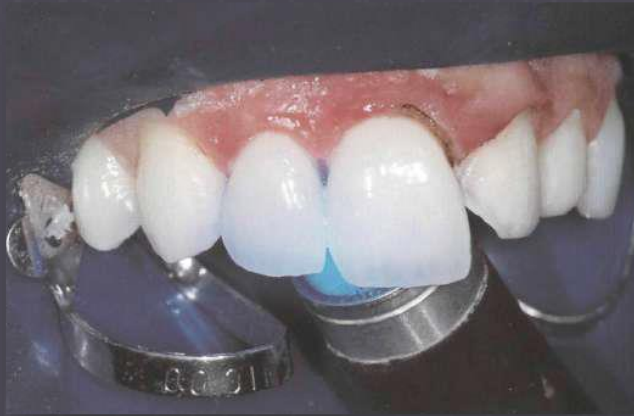The porcelain veneer absorbs between 40-50% of the emitted light

The thickness & the opacity of the ceramic affect the transmission of light

Consequent micro hardness of the luting composite

Light cured resin composites do not reach their maximum hardness, in the case of porcelain with a thickness of more than 0.7mm or when the surface is opaqued excessively

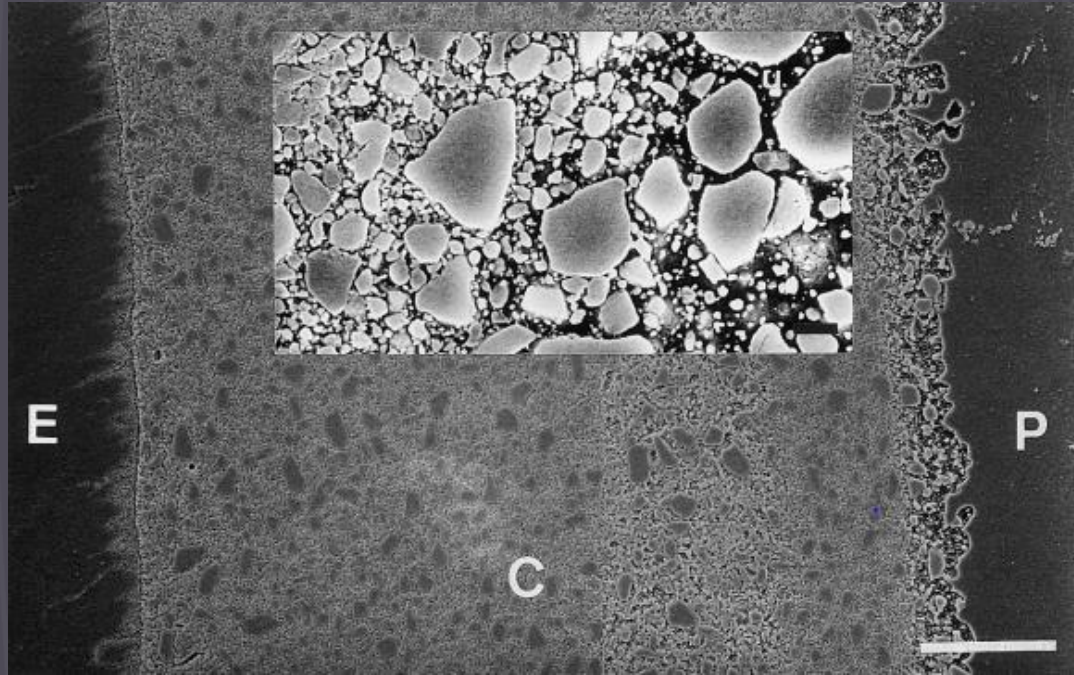
- ✓ Use a dual-cured luting composite, which contains the initiation systems for both chemically and light-cured composites



- ✓ *The light should be applied to different areas from different angles to avoid overheating of the tooth, thus preventing postoperative pulpal sensitivity*

“

*The adhesion complex: tooth/luting  
composite/ porcelain*



*FE-SEM photographs showed a strong micro-mechanical interlocking of the luting composite in the micro-retentive pits of the acid etched tooth surface at one side and in the etch pits of the acid-etched porcelain surface at the other side*

The strength of the combined porcelain/luting composite/enamel bond (63 MPa) was significantly higher than the separate composite/etched enamel (31 MPa) and luting composite/etched-and-silanized porcelain (33 MPa) bond strengths.

*Magne and Douglas* also demonstrated that:

Porcelain veneers restore the mechanical behaviour and microstructure of the intact tooth in vitro even when they are bonded to an extensive dentin surface using an optimised application mode of dentine adhesives

- *A sufficient and even thickness of ceramic*
- *Minimal thickness of luting composite*
- *A ceramic and luting composite thickness ratio above 3*



- ✓ *Favorable configuration with regard to crack propensity,*
- ✓ *Uniform stress distribution namely,*

## Wavelength of normal LED & Color Corrected LED lights?

Normal LED lights

Each LED emits a specific color which corresponds to the amount of energy emitted when the electrons are 'liberated' and enter the electron holes within the semiconductor material

Contains three separate diodes within the same bulb casing. Each of these diodes emits its own, specific color – red, green, or blue. When all three diodes are switched on at full capacity, white light is produced

Color Corrected LED lights

## Disinfectant solution for impression

**Table 1** Impression materials and disinfection choices

| Impression material | Disinfectant agent   | Duration |
|---------------------|--|----------|
| Alginate            | Iodophors and diluted sodium hypochlorite                    | 10 min   |
| Compound            | Iodophors and diluted sodium hypochlorite                    | 10 min   |
| Polyether           | Iodophors and diluted sodium hypochlorite, complex phenolics | 10 min   |
| Polysulphide        | Iodophors and diluted sodium hypochlorite, complex phenolics | 10 min   |
| Silicone            | Iodophors and diluted sodium hypochlorite, complex phenolics | 10 min   |
| Agar                | Iodophors and diluted sodium hypochlorite                    | 10 min   |
| Zinc-oxide eugenol  | Iodophors  | 10 min   |

The American Dental Association's revised guidelines recommend chemical agents that are virucidal, bactericidal and sporicidal. These chemical agents are chlorine compounds, phenols, iodophors, formaldehyde and gluteraldehyde. Immersion in NaOCl at concentration of 1:10 (0.525%) is advised for 10 minutes. Samra and Neiman investigated the effects of gluteraldehyde, phenol, iodophors and chlorine compound immersion disinfection procedure on set stone cast. The results of this study showed that a 0.525% Naocl least affected the cast with regard to compressive strength, surface changes, surface hardness and chemical reactivity.<sup>32</sup>

## Removal of retraction cord during impression making

This single cord technique is usually described as follows. A single cord is carefully placed in the sulcus, left in situ for a period of time usually no less than five minutes and finally removed before making the impression. Once the cord is removed, gingival displacement of about the width of the cord used is achieved. In cases where there is a deep sulcus, the tissue may collapse when removed or it can collapse on top of the cord. In these clinical circumstances, the single cord technique is less effective and alternative methods of tissue retraction should be considered.

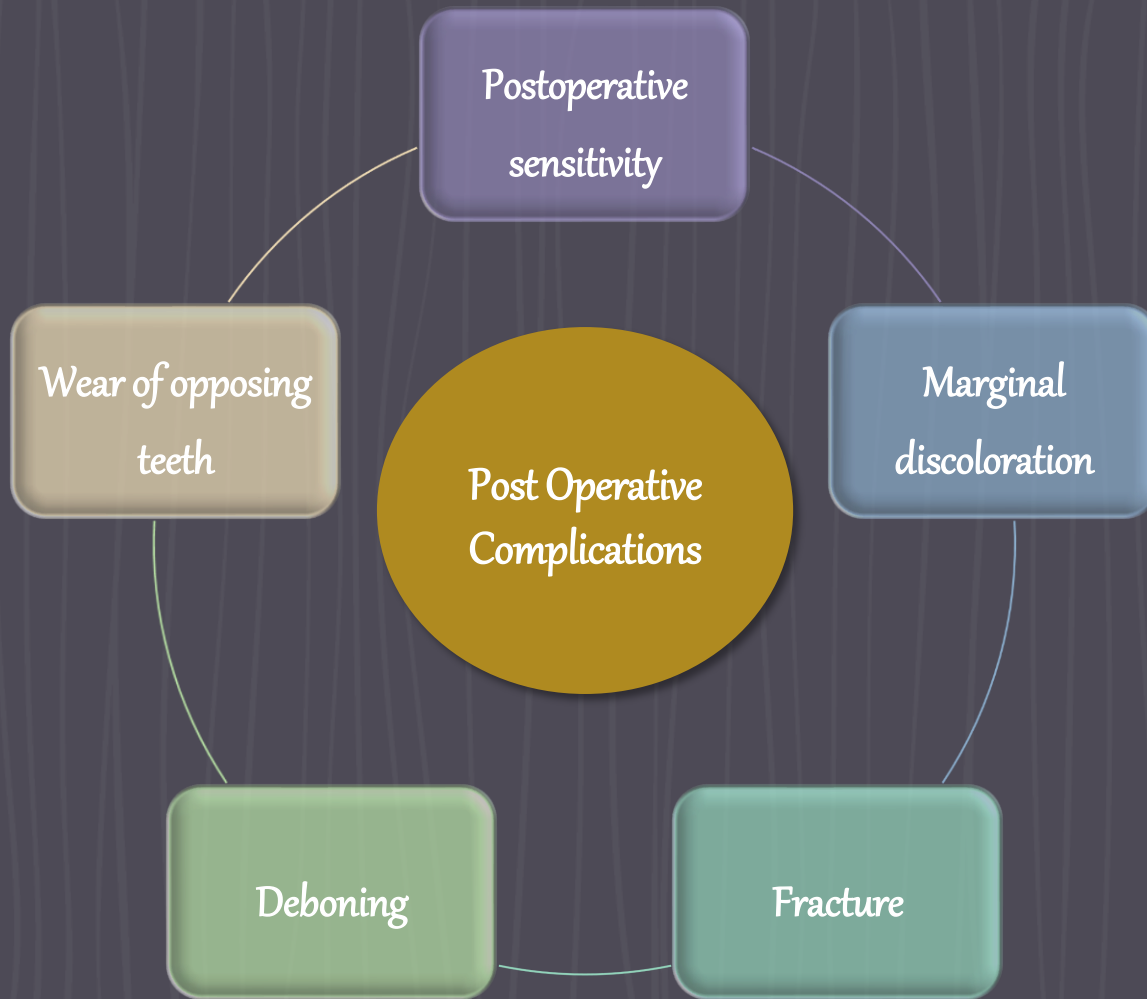largest part of its diameter level with the sulcus tip. The cord is left in the sulcus for a couple of minutes and then gently removed, keeping the first one in the sulcus, which will help to stop the tissue fluid flow. The impression should be made as soon as possible, before the deflected gingival margin collapses back to its original position. In addition, if there are big undercuts at the palatal surface or if larger gingival embrasures exist, it may be beneficial to block these sites out before making the impression, as the material will most likely tear away from these areas and at times distort the impression.

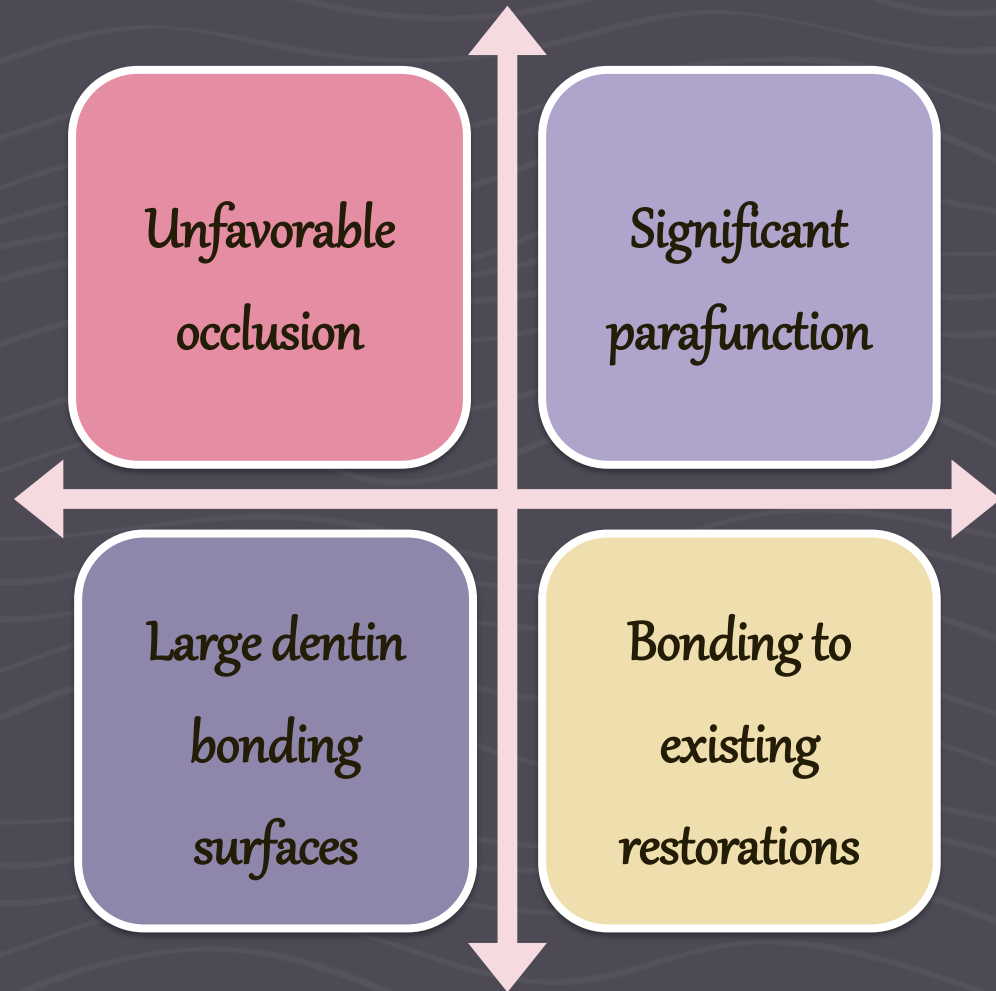
## Sequence of veneer cementation?

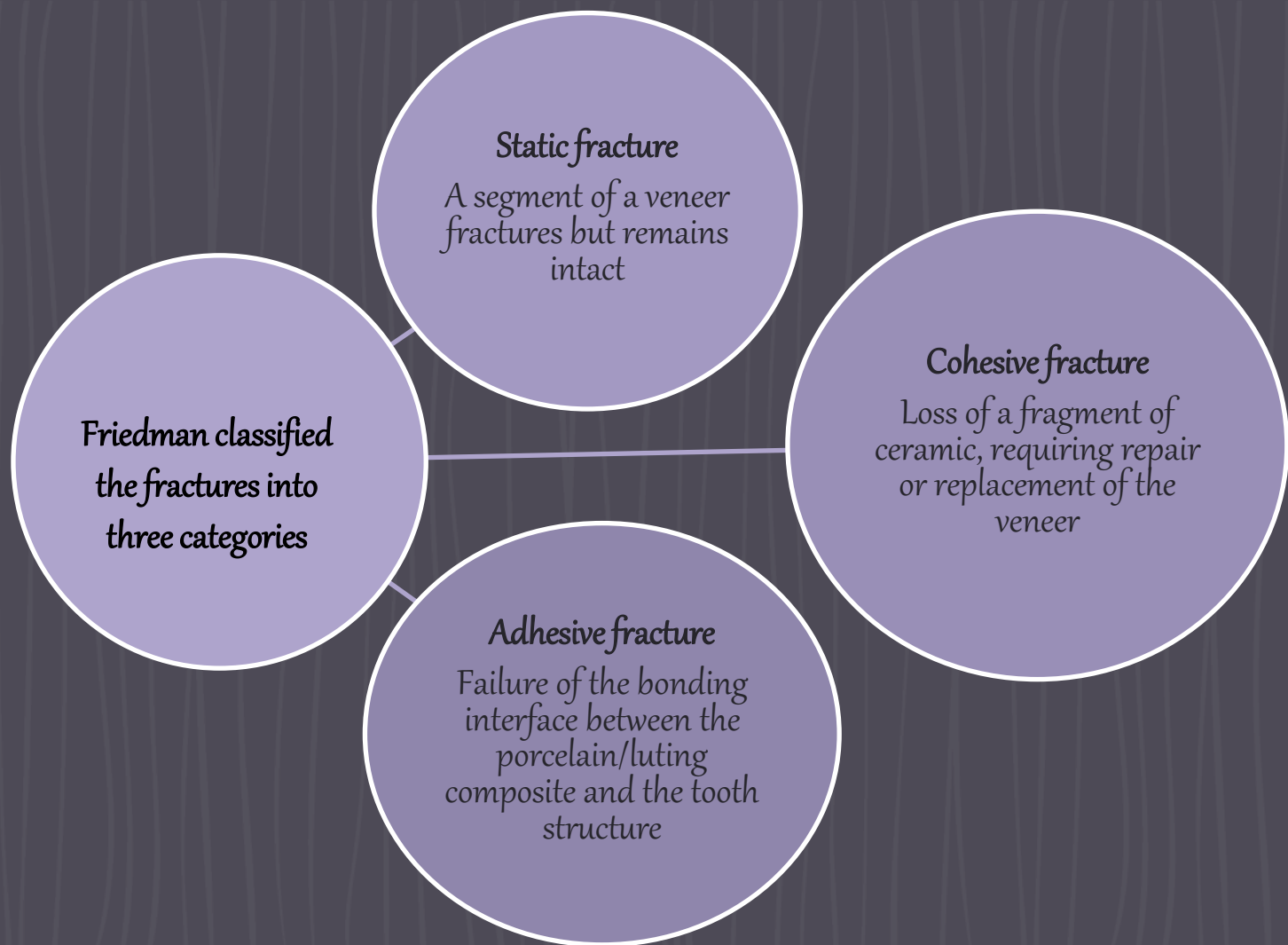
*If we are putting all at the same time... they lie on each other up and they orient the adjacent veneers. Because if we are putting individually then we will have to deal with bleeding. Plus if a veneer is moved even a little bit while cementation it wont allow proper seating of adjacent veneer*



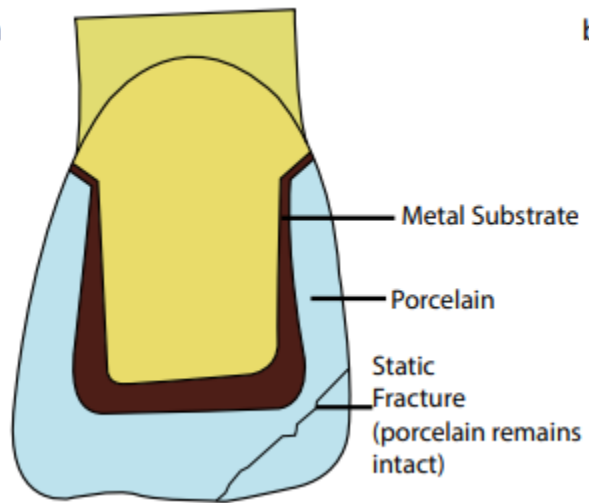
# *Failures of Veneers*



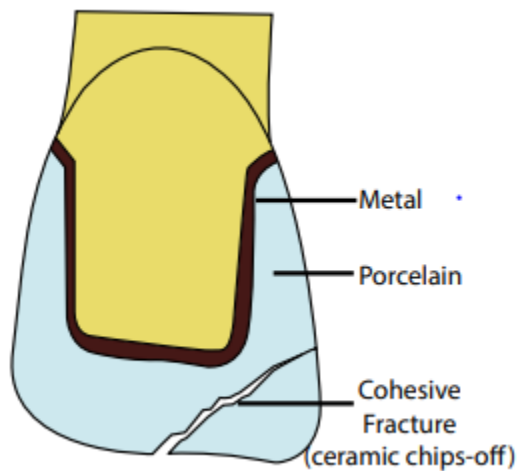




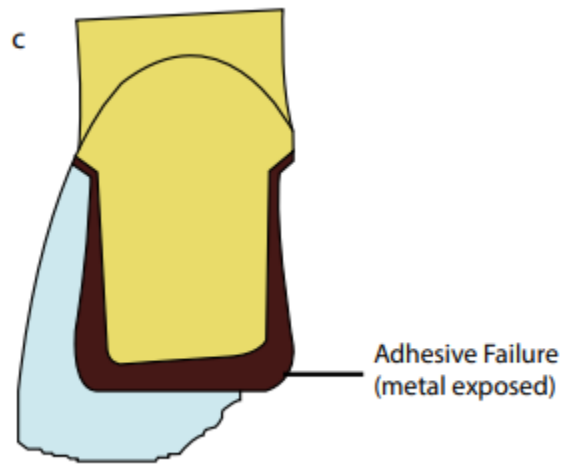
a



b



c



## *Clinical Classification Of Fractures Of Ceramic Restorations*

### *Non-Critical Flaw*

- *Can be amended*

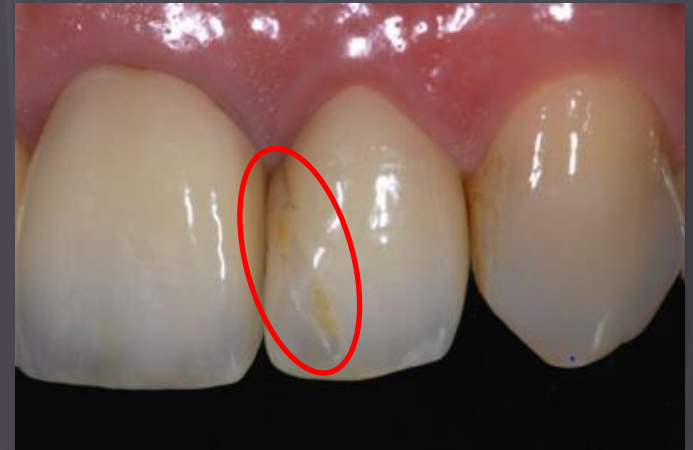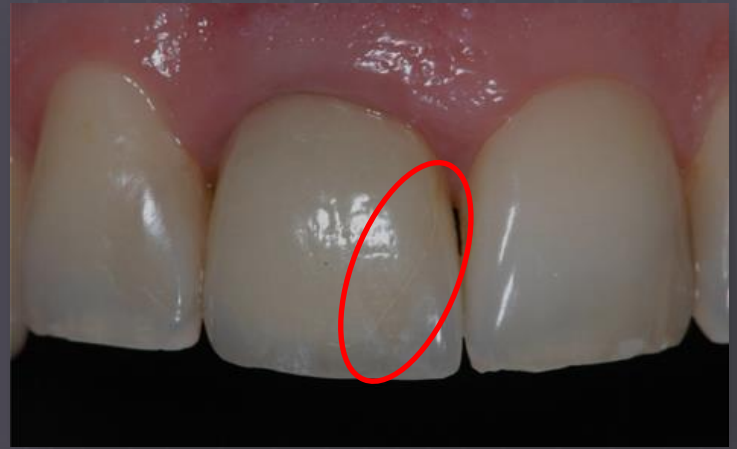### *Critical Flaws*

- *The restoration must be replaced*

*Static(Crack) & Cohesive(Chipping) failures are divided into this category*

## *Static Fracture*

- Caused by excessive loading or polymerization shrinkage.
- The crack propensity is inversely proportional to the internal fit of the veneer.
- An internal fit discrepancy of 100  $\mu\text{m}$  or less will minimize internal stress and prevent static fracture!



## *Cohesive fracture*

Occur within the body of porcelain due to tensile loads from excessive functional or parafunctional loading

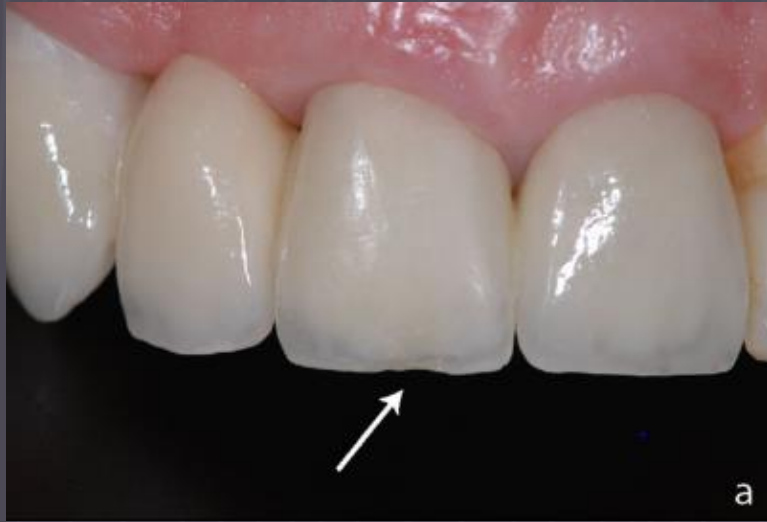↓ Thickness of enamel



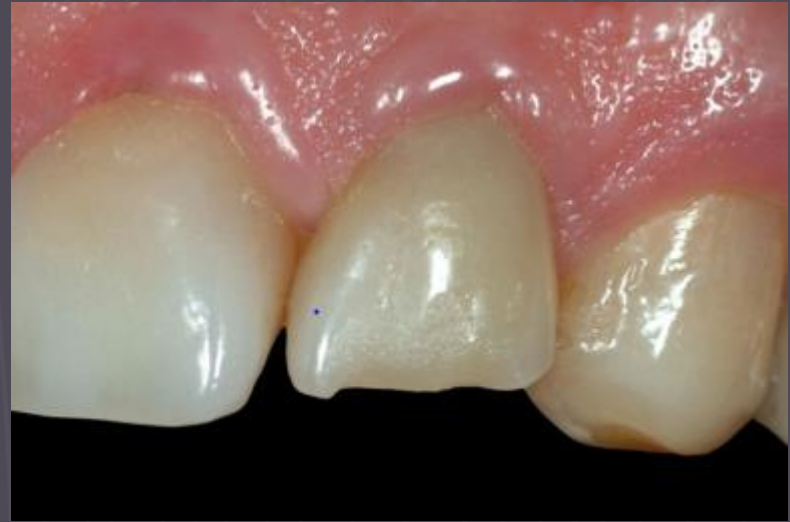↑ Poor stress distribution  
↑ Tooth flexion under occlusal loading  
↓ Surface Area for bonding

- ✓ The most important areas in which to maintain enamel are the incisal and cervical areas

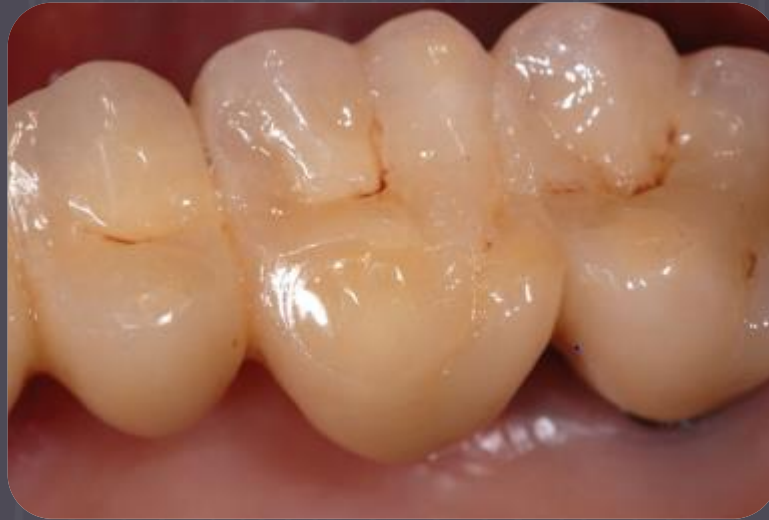Due to the greater stress at the incisal edge of the veneer it is advisable **reducing the incisal edge from 1.5-2.0 mm shorter than the final incisal edge of the PLV**. This will not only enhance the mechanical resistance but the esthetics as well



*Type 2a (Non-Critical chipping of the veneer.  
The site could be easily reshaped and polished*



*Type 2b (Critical chipping of of the veneer  
showing an irremediable loss of morphology  
and esthetics. A new restoration must be  
fabricated*

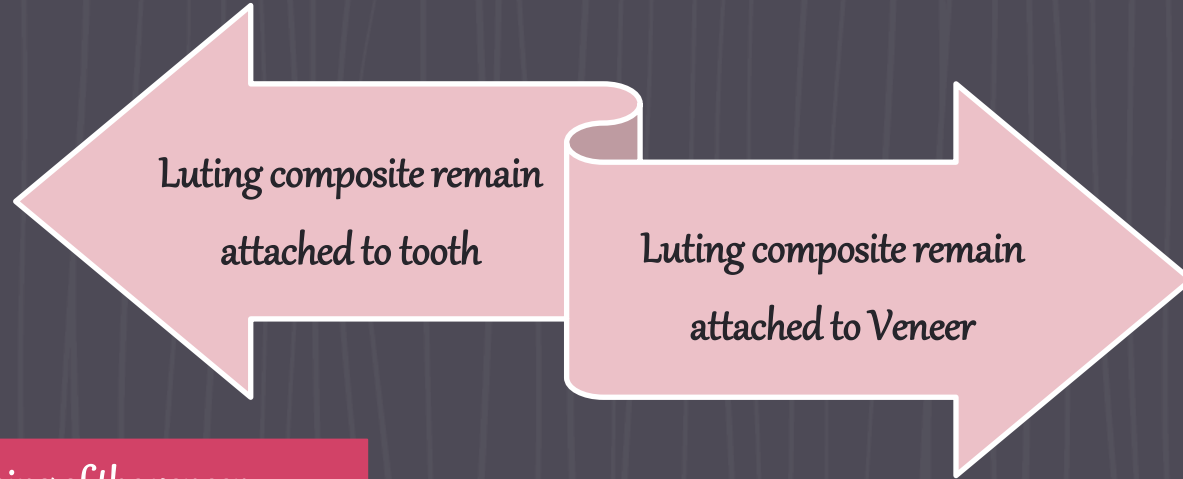


Type 2a (Non-Critical chipping of the veneer showing an delamination of a palatal cusp. The site could be easily reshaped and polished

## *Adhesive Fracture*

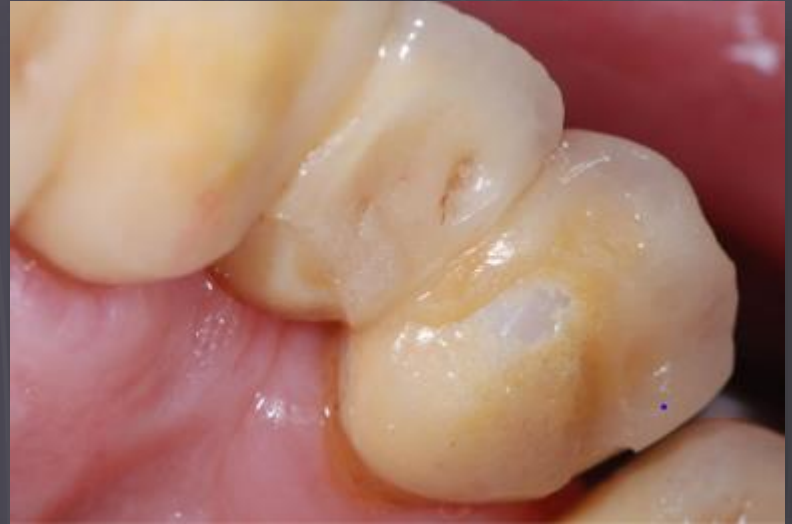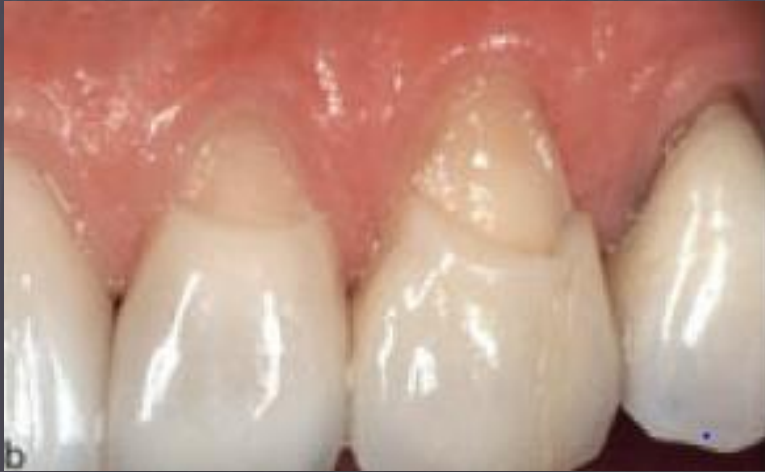An adhesive fracture is due to a failure of the bonding interface between the porcelain/luting composite and the tooth structure

On rare occasions, a porcelain veneer will debond:



- Either inadequate etching of the veneer
- The use of silane past its expiration date

- Problem with either the bonding materials
- The placement technique
- The bonding substrate



It is a result of a weak bond or severe occlusal loading. *Friedman'* reports that 86% of the adhesive fractures occurred at a resin-dentin interface

## RESEARCH AND EDUCATION

# Effect of tooth substrate and porcelain thickness on porcelain veneer failure loads in vitro

Chunling Ge, DDS, PhD,<sup>a</sup> Chad C. Green, BSE, DDS,<sup>b</sup> Dalene A. Sederstrom, CDT,<sup>c</sup> Edward A. McLaren, DDS,<sup>d</sup> James A. Chalfant, PhD,<sup>e</sup> and Shane N. White, BDentSc, PhD<sup>f</sup>

The null hypotheses were rejected: both substrate type and porcelain thickness influenced the loads needed to produce catastrophic failure of model porcelain veneers. Overall, the results of this study suggest that retaining the maximal amount of enamel surface area after tooth preparation is paramount and that thicker veneers will also better resist catastrophic failure.

substrates. Hence, veneers cemented to enamel were several times more damage-tolerant (the difference between the plots lines for initial and catastrophic failure) than those cemented to half-enamel-half-dentin all-dentin substrates.

*Should porcelain thickness be maximized at the cost of tooth structure??*

failure for both half-dentin-half-enamel and all dentin substrates (Fig. 3). Increased porcelain thickness did not compensate for lack of enamel area.

should be maximized. However, 1.4-mm-thick veneers bonded to the half-enamel-half-dentin and all-dentin substrates were weaker than 0.2-mm veneers bonded to an all-enamel substrate (Fig. 3).

Finally, **marginal staining and leakage** are common causes of failure of porcelain veneers. The staining is caused by an influx of oral fluids containing chromogenic bacteria or organic stains

**Post-bonding cracks** mostly due to bad preparation design, insufficient space for the ceramic, and inadequate bonding techniques

The **formation of microcracks** will increase during the firing procedures if there are no smooth, rounded line angles between preparation surfaces produced and, instead, acute line angles between the proximal, occlusal and lingual (palatal) preparation surfaces created

“

▷ *Management of failures*

*In-vivo, minor chipping and cracking may be smoothed or repaired without the need to remove the whole veneer.*

*Dunne and Millar reported that the incidence of such repairable defects (8%) was similar to the number of veneers requiring total replacement (11%)*

***LUMINEERS***  
***The true***  
***laminates!!!***

- Ultrathin porcelain veneers → bonded directly over the tooth structure.
- Approximately, 0.3 mm thick veneers.
- EXAMPLES – Vivaneers
  - Durathin veneers
  - MAC veneers



ADVANTAGES

Fast & painless technique

Conservative

No postoperative sensitivity & pulpal involvement

Long-lasting bonding (bonding to enamel only)

Can be placed over unaesthetic crown

Can be removed.

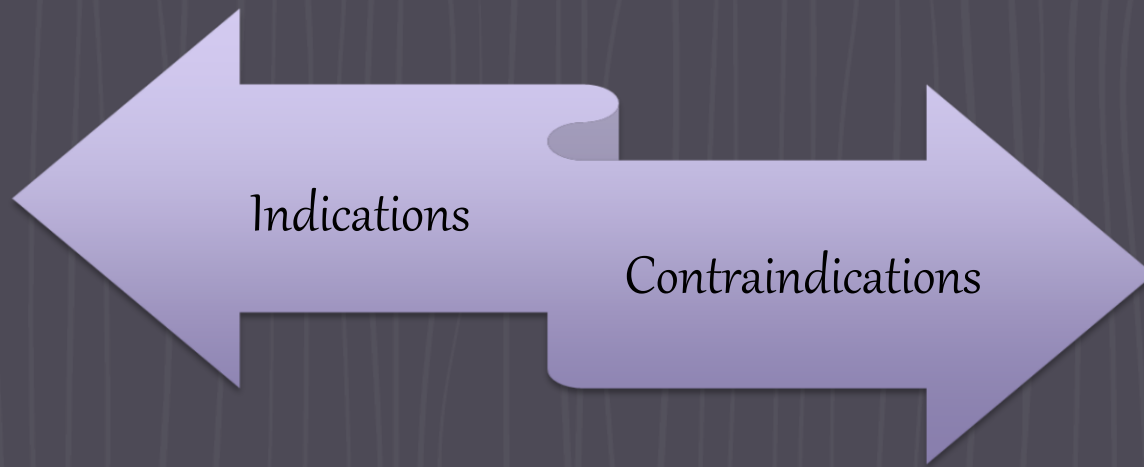
May appear bulky & over-contoured.

Width & length may not be altered significantly.

Color masking - Not proper



DISADVANTAGES



- *Enhancing esthetics appearance.*
- *Masking small discrete wear of color change.*
- *Masking existing restorations*
- *Restoring small chipped teeth*
- *Refreshing existing ceramic restorations*
- *Reshaping small diastemas*

- *Severe/moderate discoloration.*
- *Insufficient enamel substrate.*
- *Large defects, especially at the incisal edges.*
- *Rotated/malposed teeth.*

## *Conclusion*

*The porcelain veneer is very esthetic and conservative treatment option for many indications.*

*The success of porcelain veneer depends very much on the method of fabrication and most importantly case selection.*

THANK YOU